

Croat Med J. 2019;60:458-62
<https://doi.org/10.3325/cmj.2019.60.458>

Autosomal recessive Alport syndrome caused by a novel *COL4A4* splice site mutation: a case report

Alport syndrome (AS) is a genetically heterogenic, structural disorder of the glomerular basement membrane (GBM) due to the mutation of *COL4A3*, *COL4A4*, or *COL4A5* genes, which clinically presents as progressive hematuric nephritis with ultrastructural changes of the GBM, high tone sensorineural hearing loss, and ocular lesions. About 15% of AS cases have autosomal mutations of *COL4A3* and *COL4A4* genes, including homozygous and compound heterozygous mutations. Here, we present a case of a two-year-old boy with autosomal recessive Alport syndrome (ARAS) caused by a novel c.193-2A>C *COL4A4* mutation. The patient had a delayed motor and sensory development coupled with speech and language delay, megalencephaly, hematuria and proteinuria, and normal tonal audiogram and ophthalmology exam. Extensive genetic, metabolic, and neurologic workup performed at the age of 10 months was unremarkable and patient's megalencephaly was described as familial benign megalencephaly. Kidney biopsy analysis showed characteristic signs of AS. Mutations screening with use of Illumina MiSeq platform revealed that the patient was homozygous for a newly discovered splice acceptor pathogenic variant c.193-2A>C found in *COL4A4* at the genomic position chr2:227985866 and both parents were heterozygous carriers. The genetic heterogeneity of AS makes the diagnostic process challenging. Although renal biopsy provides information about the characteristic GBM changes and the degree of renal parenchyma damage (interstitial fibrosis and tubular atrophy ratio), genetic testing is a more sensitive and specific method that also gives insight into potential disease severity and clinical course, and provides the basis for genetic counseling.

Petar Šenjug¹, Tamara Nikuševa Martić², Marija Šenjug Perica³, Maja Oroz⁴, Matija Horaček⁵, Martin Čuk⁶, Slaven Abdović⁶, Danica Galešić Ljubanović^{1,5}

¹Unit of Nephropathology and Electron Microscopy, Department of Pathology and Cytology, Dubrava University Hospital, Zagreb, Croatia

²Department of Biology, University of Zagreb School of Medicine, Zagreb, Croatia

³Children's Hospital Srebrnjak, Zagreb, Croatia

⁴University Hospital for Infectious Diseases "Dr. Fran Mihaljević," University of Zagreb School of Medicine, Zagreb, Croatia

⁵Institute of Pathology, University of Zagreb School of Medicine, Zagreb, Croatia

⁶Department of Pediatrics, Children's Hospital Zagreb, Zagreb, Croatia

Received: August 26, 2019

Accepted: October 30, 2019

Correspondence to:

Tamara Nikuševa Martić
Šalata 3

10000 Zagreb, Croatia

tamara.nikuseva.martic@mef.hr

Alport syndrome (AS) is a genetically heterogenic disorder that clinically presents as a progressive nephropathy characterized by hematuric nephritis with ultrastructural changes of the glomerular basement membrane (GBM), high tone sensorineural hearing loss, and ocular lesions (1). The genetic base for AS is most frequently (85%) the mutation of X-linked gene *COL4A5* (2). Only about 15% of AS cases have autosomal mutations of *COL4A3* and *COL4A4* genes, including homozygous and compound heterozygous mutations (3). X-linked AS more often and more severely affects men than women (4). However, in autosomal recessive AS, the clinical course is influenced by the genotype but is usually severe in both men and women, with early progression to end stage renal disease (ESRD) and frequent extrarenal manifestations (5). Here, we present a case of an early onset ARAS with characteristic GBM changes caused by a novel, c.193-2A>C *COL4A4* mutation.

CASE REPORT

A 10-month-old male infant was referred to the Department of Pediatrics, Children's Hospital Zagreb in 2016 due to a delay in the psycho-motoric development and megalencephaly. After extensive genetic, metabolic, cytogenetic, and neurologic workup, clinical phenotype of the child was described as familial benign megalencephaly. The patient had both motor and sensory developmental delay, coupled with speech and language delay, with stereotypical movements, unresponsiveness to name calling at the age of one, lack of sentence formation with a limited number of used words for age, short attention span, bad tolerance to frustration, and the onset of walking at 22 months. At the age of 1 year and 2 months, macrohematuria and proteinuria were recorded for the first time, with protein/creatinine ratio of 284 mg/mmol. At the age of 2 years he had proteinuria 189 mg/mmol and severe microhematuria. Tonal audiogram was unremarkable and eye exam did not

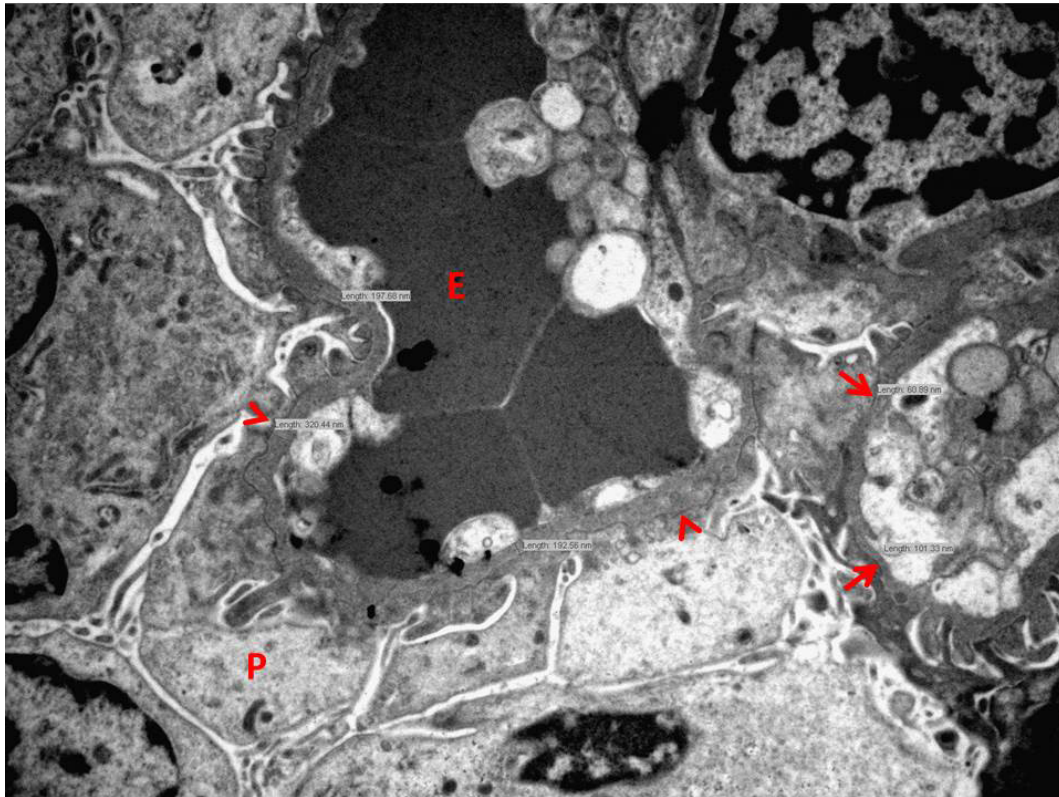


FIGURE 1. Thinning (arrows) and thickening (arrow heads) of glomerular basement membrane with lamellation in the areas of thickening. P – podocyte, E – erythrocyte. Electron microscopy, magnification x8000.

reveal anterior lenticonus. Kidney biopsy was performed. Light microscopy analysis showed one out of 69 globally sclerosed glomeruli and 30% of immature/partly immature glomeruli. There was one small focus of interstitial fibrosis and tubular atrophy (IFTA) that affected 1% of the cortical parenchyma. Routine immunofluorescent analysis was un-

remarkable. Electron microscopy (EM) of the GBM showed areas of thinning and thickening (61 to 390 nm, average 167 nm with a standard deviation of 65 nm, while the reference range of GBM thickness for the age of 2 years is 156-292 nm, Figure 1) (6). The thickened areas of GBM exhibited lamellation and basket-wave appearance. There was focal

TABLE 1. Medical history timeline

| Year/age | Symptoms | Diagnostic workup | Diagnosis | Therapeutic intervention |
|-------------------------|------------------------------------------------------------|---------------------------------------------------------------------------------------------------------------------------------------------------------|-------------------------------------|----------------------------------------------|
| February 2016/0 months | APGAR score 10/10, weight 3090 g, length 48 cm | | | |
| December 2016/10 months | Delay in the psycho-motoric development and megalencephaly | Cariogram 46 XY, tests for fragile X, organic acids in urine, homocysteine B12 and folic acid, acyl – carnitine profile, amino acids in urine and serum | Familial benign megalencephaly | |
| April 2017/14 months | Macrohematuria and proteinuria | Protein/creatinine ratio of 284 mg/mmol | | |
| February 2018/24 months | Proteinuria and severe microhematuria | Protein/creatinine ratio of 189 mg/mmol Kidney biopsy Tonal audiogram Ophthalmology exam | Alport syndrome Normal Normal | Ramipril treatment with proteinuria decrease |
| August 2018/30 months | | Genetic testing | c.193-2A>C COL4A4 mutation | |

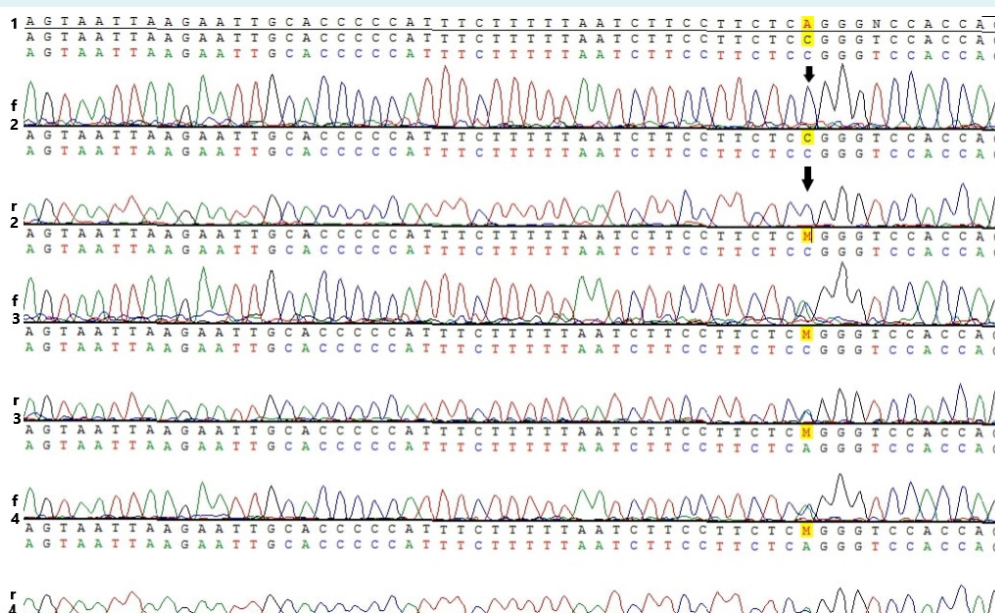


FIGURE 2. Mutation analysis of c.193-2A>C in COL4A4 at the genomic position chr2: 227985866. Electropherogram of a single base-pair A>C substitution at nucleotide 193 (marked with yellow color) in an affected patient [2] and carrier parents [3 and 4]. Patient's and parents' electropherograms are presented as bidirectional sequences (forward [f] and reverse direction [r]). The sequence numbered as [1] stands for reference COL4A4 sequence. M stands for mixed bases (heterozygous genotype) of A and C.

podocyte foot process effacement in the areas above the thickened and lamellated basement membranes. Kidney biopsy report concluded that the findings corresponded to AS and suggested genetic counseling and testing.

Ramipril treatment (6 mg/m²) reduced proteinuria to 73 mg/mmol creatinine, while severe microhematuria persisted.

COL4A3, *COL4A4*, and *COL4A5* genes of both the patient and his parents were screened for mutations with use of Illumina MiSeq platform (Illumina, San Diego, CA, USA). For bioinformatical analysis, Illumina VariantStudio software was used. All variants were assigned a number in available databases, including the NCBI dbSNP138 and ClinVar (7). Newly discovered splice acceptor pathogenic variant c.193-2A>C found in *COL4A4* at the genomic position chr2:227985866 (variant described according to reference genome GRCh37) was confirmed with standard dye-terminator sequencing with use of ABI310 (Applied Biosystems, Foster City, CA, USA) with BigDye v1.1 and Vector NTI Software (Thermo Fisher Scientific, Waltham, MA, USA) for visualization. Both parents were heterozygous for c.193-2A>C variant, while the patient was homozygous (Table 1) (Figure 2).

DISCUSSION

The pathohistological diagnosis of AS in children can be challenging. EM in children with AS often shows only thin glomerular basement membranes (5). In our patient, light microscopy analysis showed 70% of glomeruli with normal appearance, one globally sclerosed glomerulus, and 30% of glomeruli with immature/partly immature appearance. This percentage, although somewhat above the expected for the patient's age, is usual in AS patients (8,9). There was one small focus of IFTA, which affected 1% of the cortical parenchyma. EM revealed classic AS ultrastructural morphology.

Genetic analysis in our patient revealed splice site c.193-2A>C in *COL4A4* at the genomic position chr2:227985866. This mutation has not been previously described in either The Human Gene Mutation Database, Leiden Open (source) Variation Database, or Ensembl genome database. The mutation met the PVS1, PM2, and PP3 criteria for pathogenicity by American College of Medical Genetics and Genomics (10). It was a null variant (within ± 2 of canonical splice site) affecting *COL4A4* gene, which is a widely known disease mechanism (PVS1); the allele was not found in GnomAD despite good coverage (PM2); and

there was computational evidence of pathogenicity (PP3) with DANN score: 0.9909; GERP scores: NR 5.2399 and RS 5.2399; MutationTaster: accuracy 1 and converted rankscore 0.8103; dbSNV: ADA score 0.9999 and RF score 0.916. Variant comparison to the in-house database of 50 healthy individuals also supported this finding.

Very few potential splicing mutations are identified within the first 10 nucleotides of the intron-exon boundaries for the *COL4A3* and *COL4A4* genes (11). In our case, we observed the mutation c.193-2A>C in *COL4A4* at the genomic position chr2:227985866. There are reports of *COL4A4* splice site mutation causing autosomal AS (12). Rosado et al (12) found IVS3+1G>C, replacement of guanine to cytosine in position 1+ of intron 3 in the splicing region, suggesting the presence of autosomal dominant AS. In our case, patient's both parents were heterozygous carriers of c.193-2A>C. The first testing showed that the parents had no hematuria or proteinuria and had normal kidney function, while a repeated urine analysis showed that the father had hematuria. The patient was homozygous for c.193-2A>C, suggesting autosomal recessive inheritance. Parents denied consanguinity, however they were both born in the same village, indicating a theoretical possibility of consanguinity.

It is hard to predict the clinical course for our patient. On the kidney biopsy level, light microscopy showed characteristic EM changes and only incipient chronic changes. Savige et al (11) reported that patients with *COL4A4* mutation develop end-stage renal failure at a mean age of 25.4 ± 10.3 years. Our patient at the age of two had proteinuria and hematuria with normal kidney function.

Considering the genetic heterogeneity of the disease, diagnostic process of AS can be challenging. We presented a case of ARAS caused by a novel c.193-2A>C *COL4A4* splice site mutation. Although renal biopsy provides information about the degree of renal parenchyma damage, genetic testing is a more sensitive and specific method that also gives insight into potential disease severity and clinical course, and provides a basis for genetic counseling.

Funding Croatian Science Foundation, project Genotype-Phenotype Correlation in Alport's Syndrome and Thin Glomerular Basement Membrane Nephropathy (IP-2014-09-2151)

Ethical approval This research is part of the project Genotype-Phenotype Correlation in Alport's Syndrome and Thin Glomerular Basement Membrane Nephropathy (IP-2014-09-2151), which was approved by the Ethics Committee of the University of Zagreb School of Medicine (Number: 380-59-10106-15-168/181, Class: 641-01/15-02/01). Patient's parents gave their written informed consent for the publication of data and images.

Declaration of authorship PŠ, TNM, MŠP, MO, MH, MČ, SA, DGLJ conceived and designed the study; PŠ, TNM, MŠP, MH, MČ acquired the data; PŠ, TNM, MO, MČ, DGLJ analyzed and interpreted the data; PŠ, TNM, MČ drafted the manuscript; MŠP, MO, MH, SA, DGLJ critically revised the manuscript for important intellectual content; PŠ, TNM, MŠP, MO, MH, MČ, SA, DGLJ gave approval of the version to be submitted; PŠ, TNM, MŠP, MO, MH, MČ, SA, DGLJ agree to be accountable for all aspects of the work.

Competing interests All authors have completed the Unified Competing Interest form at www.icmje.org/coi_disclosure.pdf (available on request from the corresponding author) and declare: no support from any organization for the submitted work; no financial relationships with any organizations that might have an interest in the submitted work in the previous 3 years; no other relationships or activities that could appear to have influenced the submitted work.

References

- 1 Kashtan CE, Michael AF. Alport syndrome. *Kidney Int.* 1996;50:1445-63. [Medline:8914010](#) [doi:10.1038/ki.1996.459](#)
- 2 Pirson Y. Making the diagnosis of Alport's syndrome. *Kidney Int.* 1999;56:760-75. [Medline:10432421](#) [doi:10.1046/j.1523-1755.1999.00601.x](#)
- 3 Savige J, Ariani F, Mari F, Bruttini M, Renieri A, Gross O, et al. Expert consensus guidelines for the genetic diagnosis of Alport syndrome. *Pediatr Nephrol.* 2019;34:1175-89. [Medline:29987460](#) [doi:10.1007/s00467-018-3985-4](#)
- 4 Savige J, Gregory M, Gross O, Kashtan C, Ding J, Flinter F. Expert guidelines for the management of Alport syndrome and thin basement membrane nephropathy. *J Am Soc Nephrol.* 2013;24:364-75. [Medline:23349312](#) [doi:10.1681/ASN.2012020148](#)
- 5 Heidet L, Gubler MC. The renal lesions of Alport syndrome. *J Am Soc Nephrol.* 2009;20:1210-5. [Medline:19470679](#) [doi:10.1681/ASN.2008090984](#)
- 6 Haas M. Alport syndrome and thin glomerular basement membrane nephropathy: a practical approach to diagnosis. *Arch Pathol Lab Med.* 2009;133:224-32. [Medline:19195966](#)
- 7 Landrum MJ, Lee JM, Riley GR, Jang W, Rubinstein WS, Church DM, et al. ClinVar: public archive of relationships among sequence variation and human phenotype. *Nucleic Acids Res.* 2014;42:D980-5. [Medline:24234437](#) [doi:10.1093/nar/gkt1113](#)
- 8 Thony HC, Luethy CM, Zimmermann A, Laux-End R, Oetliker OH, Bianchetti MG. Histological features of glomerular immaturity in infants and small children with normal or altered tubular function. *Eur J Pediatr.* 1995;154:S65-8. [Medline:8529714](#) [doi:10.1007/BF02191509](#)
- 9 Rumpelt HJ, Steinke A, Thoenes W. Alport-type glomerulopathy: evidence for diminished capillary loop size. *Clin Nephrol.* 1992;37:57-64. [Medline:1372542](#)
- 10 Richards S, Aziz N, Bale S, Bick D, Das S, Gastier-Foster J, et al. Standards and guidelines for the interpretation of sequence variants: a joint consensus recommendation of the American College of Medical Genetics and Genomics and the Association for Molecular Pathology. *Genet Med.* 2015;17:405-24. [Medline:25741868](#) [doi:10.1038/gim.2015.30](#)
- 11 Savige J, Storey H, Il Cheong H, Gyung Kang H, Park E, Hilbert P, et al. X-Linked and Autosomal Recessive Alport Syndrome: Pathogenic Variant Features and Further Genotype-Phenotype Correlations. *PLoS One.* 2016;11:e0161802. [Medline:27627812](#) [doi:10.1371/journal.pone.0161802](#)
- 12 Rosado C, Bueno E, Felipe C, Gonzalez-Sarmiento R. COL4A4 gene study of a European population: description of new mutations causing autosomal dominant Alport syndrome. *Int J Mol Epidemiol Genet.* 2014;5:177-84. [Medline:25755845](#)