

Croat Med J. 2019;60:545-51

<https://doi.org/10.3325/cmj.2019.60.545>

Kidney transplantation using a colon pouch (Mainz pouch III): a case report

Kidney transplantation is the most efficient method of renal replacement therapy. When this method is performed, native urinary bladder is the preferred urinary reservoir. However, in some patients with an anatomically and functionally abnormal lower urinary tract, the urinary bladder cannot be used for transplantation. In these patients, urinary diversion should be performed before kidney transplantation. We present a case of a 32-year-old male patient with orthotopic kidney transplantation performed using a colon pouch (Mainz-pouch III). He was born with severe anomalies including sacral agenesis, anorectal atresia, and hypospadias, which were corrected during childhood. Neurogenic bladder with severe vesicoureteral reflux led to end-stage renal disease. This dysfunctional bladder was unsuitable for kidney transplantation, and a staged approach for future transplantation was chosen. The first step was the creation of urinary diversion. Due to a short appendix, we created a continent, colon pouch (Mainz pouch III). Two years later, orthotopic kidney transplantation was performed using a right cadaveric kidney. The renal vessels were anastomosed to the aorta and inferior vena cava and the pyelon to the native ureter. Four years after transplantation, the patient has stable renal function without any complications. This is the first documented case of using Mainz-pouch III as a reliable option for kidney transplantation in selected patients.

Dean Markić^{1,2}, Romano Oguić^{1,2}, Kristian Krpina¹, Antun Gršković¹, Ivan Vukelić¹, Sanjin Rački^{2,3}, Aldo Ivančić^{2,4}, Davor Primc⁴, Josip Španjol^{1,2}

¹Department of Urology, University Hospital Rijeka, Rijeka, Croatia

²Faculty of Medicine, University of Rijeka, Rijeka, Croatia

³Department of Nephrology, Dialysis and Transplantation, University Hospital Rijeka, Rijeka, Croatia

⁴Department of Surgery, University Hospital Rijeka, Rijeka, Croatia

Received: January 28, 2019

Accepted: November 16, 2019

Correspondence to:

Dean Markić
Department of Urology
University Hospital Rijeka
Tome Strižića 3
51 000 Rijeka, Croatia
dean.markic@ri.htnet.hr

At the beginning of the era of kidney transplantation (KT), a normal urinary bladder was considered an indispensable condition. Over time, the patients with dysfunctional urinary bladders became candidates for transplantation. The first KT using an ileal conduit in a patient with a severely damaged urinary bladder was done in 1966 (1). Since then, the number of KTs in patients with abnormal lower urinary tracts has gradually increased.

Up to 15% of patients with end-stage renal disease (ESRD) have abnormalities of the lower urinary system, which can lead to kidney deterioration (2). In the pediatric population with ESRD, this rate increases up to 30% (3). In patients with a dysfunctional bladder (small volume, poorly compliant bladder), transplantation must be avoided because the graft will be damaged by the same mechanisms as those that damaged native kidneys. In these patients, it is recommended to perform pretransplant surgical correction of the urinary tract before KT. The urinary bladder can be augmented with a segment of the ileum, colon, or stomach, with the intention to create a bladder with low pressure, enough capacity, and adequate compliance to protect the upper urinary tract and renal allograft. The other possibility is to create a urinary diversion, with or without a cystectomy.

Urinary diversion is defined as the redirection of urine flow from its physiological route as a consequence of a diseased or defective ureter, bladder, or urethra. In most cases, this diversion creates a route that leads to the skin (urostomy), but it could also lead to other systems (rectum, sigmoid colon). Some of them have a continent mechanism (Mainz pouch I), and others do not (ileal conduit). Definitive urinary diversion includes ureterosigmoidostomy (Mainz pouch II), incontinent cutaneous urinary

diversion (ileal conduit), and continent cutaneous urinary diversion (Indiana pouch, Kock pouch, Mainz pouch I, Mainz pouch III).

We present a patient from our transplant center in whom orthotopic kidney transplantation was performed using a colon pouch (Mainz-pouch III). This is the first described case of such transplantation in the literature.

CASE REPORT

The patient was born with significant congenital abnormalities (sacral agenesis, anorectal atresia, and hypospadias) (Table 1). Immediately after birth, a permanent colostomy was performed, with revision when he was 18 months old. His congenital abnormalities resulted in neurological dysfunction of the lower urinary tract with neurogenic bladder, bilateral vesicoureteral reflux, and bilateral megaureters. To prevent the deterioration of kidney function, ureterocutanostomy was performed. The left ureter was terminolaterally anastomosed to the right ureter (transureteroureterostomy), and the right ureter was diverted to the skin (urostomy). At the age of five, nephrotic syndrome was diagnosed, and the kidney biopsy revealed chronic membranous glomerulonephritis. He received corticosteroids, cyclophosphamide, cyclosporine, and azathioprine, but his chronic kidney disease progressed to ESRD. In January 2012, at the age of 30, the patient started hemodialysis. In the same year, he presented to our transplant center, which is a referral center for kidney transplantation in Croatia. The multidisciplinary team decided that he was an appropriate candidate for orthotopic kidney transplantation with urinary diversion and used a staged approach. Since the patient was working and socially active, we planned to construct a continent reservoir.

TABLE 1. Medical history timeline

| Year/age | Diagnosis | Therapeutic intervention |
|----------------|-------------------------------------------------------------------------------------------------|--------------------------------------------------------------------------------------------------------------------------------------------------|
| 1982/0 months | Sacral agenesis, anorectal atresia, hypospadias | Permanent colostomy |
| 1983/18 months | Stenosis of colostomy | Revision of colostomy |
| 1984/24 months | Neurogenic bladder, bilateral vesicoureteral reflux, bilateral megaureters | Ureterocutanostomy |
| 1987/5 years | Chronic kidney disease (biopsy proven chronic membranous glomerulonephritis) | Drug therapy (corticosteroids, cyclophosphamide, cyclosporine, azathioprine) |
| 2012/30 years | End-stage renal disease | Hemodialysis |
| 2012/30 years | Preparation for transplantation including the management of recurrent left sided pyelonephritis | Simultaneous left nephrectomy, creation of urinary diversion: Mainz pouch III, ureterocutanostomy removal, implantation of right ureter in pouch |
| 2014/32 years | End-stage renal disease | Orthotopic right kidney transplantation using Mainz pouch III as urinary diversion |

The first operation was performed in November 2012 using a midline laparotomy approach. Because of recurrent left sided pyelonephritis, we removed the left kidney along with the ureter and removed urostomy. The right kidney and right ureter were preserved. Another part of this operation was the creation of urinary diversion for future transplantation. The small and large bowel were mobilized carefully. Preoperatively, we planned to create an ileocolonic reservoir (Mainz pouch I); however the appendix, which serves as the connection between the skin and the pouch, was too short. Therefore, we decided to perform another type of urinary diversion, Mainz pouch III. Mainz pouch III is a colonic, continent reservoir. We isolated a part of the ascending and transverse colon (approximately 35 cm) for the creation of a reservoir with adequate capacity. The operation was performed as initially described by Leissner et al (4). The right ureter was implanted in the pouch using an antireflux technique. The urinary catheter was inserted into the pouch through the umbilicus because in this type of operation the umbilicus serves as urostomy. Postoperatively, the patient developed paralytic ileus, which resolved with prokinetic drugs. The patient was instructed to irrigate the pouch regularly, twice a week, since only the right kidney produced a scarce amount of urine. This was

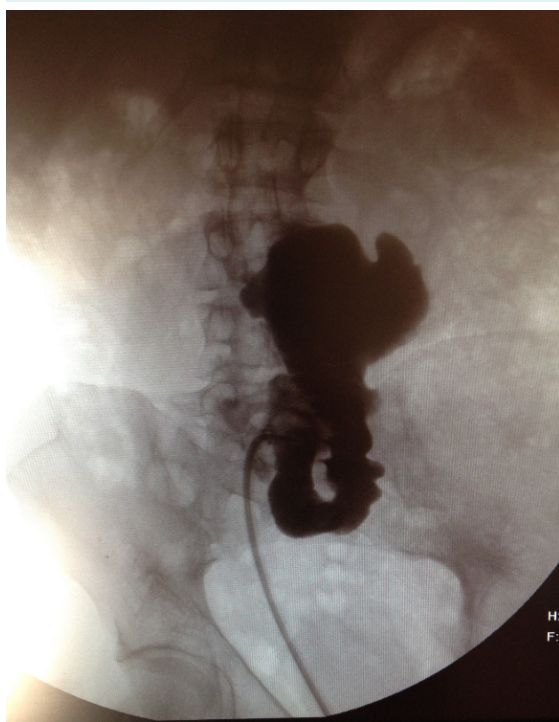


FIGURE 1. Pouchography after the creation of a reservoir.

necessary due to bowel mucous production and to keep the pouch from constricting. The postoperative capacity of the pouch was more than 200 mL (Figure 1). Approximately two months after the operation, the urinary catheter was removed, and the patient continued with self-catheterization. At the end of this first stage, the patient had a continent pouch with a catheterizable stoma prepared for right orthotopic kidney transplantation.

In November 2014, through the Eurotransplant allocation system we received an offer for a left cadaveric kidney. The donor was a 45-year-old male with brain death resulting from a traumatic bilateral subdural hematoma. The HLA matching was as follows: HLA-A (1 match), HLA-B (0), HLA-Cw (1), HLA-DR (1), and HLA-DQ (1). The crossmatch was negative. Since orthotopic kidney transplantation was planned, the surgical approach was a right sided lumbotomy over the 11th rib extending to the lateral edge of the rectus muscle. The complete operation was performed extraperitoneally. Right sided nephrectomy was done. The ureter was ligated at the level of the pyeloureteral junction. Intraoperatively it was observed that the artery and vein of the right kidney were hypotrophic and unsuitable for vascular anastomosis. This is why we prepared the inferior vena cava and aorta for this purpose. On a back-table, the left cadaveric kidney with one renal artery, vein, and ureter was prepared. The cadaveric kidney was placed in the operative field with the renal pelvis as the most superficial part of the hilar structures. First, we anastomosed the renal

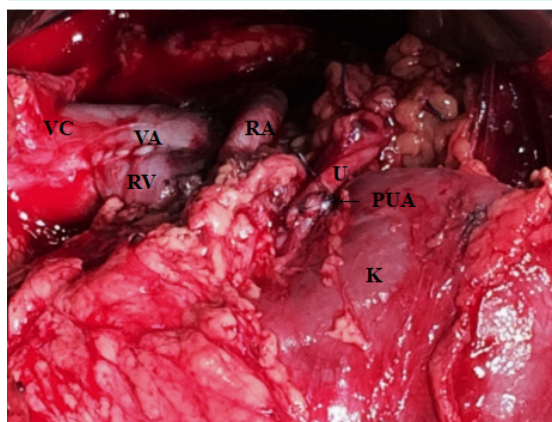


FIGURE 2. Intraoperative view of orthotopic kidney transplantation in the right lumbar region. K – kidney; VC – vena cava; RV – renal vein; RA – renal artery (crossing vena cava anteriorly); U – ureter; VA – venous anastomosis between the vena cava and renal vein; PUA – pyeloureteral anastomosis.

vein with the inferior vena cava and the renal artery with the aorta using running, nonabsorbable, monofilament 5-0 polypropylene sutures. The duration of vascular anastomosis was 40 minutes. After declamping the renal vessels, the graft immediately became well vascularized with normal consistency. Finally, we anastomosed the renal pelvis of the transplanted kidney and the right native ureter (pyeloureteral anastomosis) using monofilament, absorbable, 5-0 polydioxanone sutures (Figure 2). Urinary anastomosis was protected using JJ endoprosthesis (26 cm long, diameter 6 Ch). To prevent the sliding of the transplanted kidney, nephropexy was performed. The overall operation time was 330 minutes, and cold ischemia time was 15 hours. The diuresis level on the first day was 1900 mL. For the first three postoperative days, the patient received heparin intravenously (30.000 IU/24 hours), followed by low molecular weight heparin. The drain was removed on the ninth day. The patient had a positive urine culture: *Escherichia coli* and *Proteus mirabilis*, more than 100 000/mL, both sensitive to ampicillin, piperacillin + tazobactam, cefuroxime, and gentamicin. A combination of piperacillin and tazobactam was administered (2×4.5 g intravenously) for 14 days, followed by cotrimoxazole prophylaxis (450 mg once daily) for six months. From the time of operation to the present, immunosuppressive protocol consisted of corticosteroids, mycophenolate mofetil, and tacrolimus. Twenty days after the operation, the patient was discharged from the hospital with excellent kidney function: serum urea 6.3 mmol/L and serum creatinine 103 μmol/L.

In January 2015 (two months after the operation), the patient was admitted to the hospital for the removal of the JJ endoprosthesis. During general anesthesia, we entered the pouch through the urostomy site in the umbilicus using a semirigid ureteroscope. Some mucus was found in the pouch and was removed. The protected anastomosis between the ureter and the pouch was visualized, and the endoprosthesis was grasped and removed (Figure 3). One week after the stent removal, control ultrasonography revealed a well vascularized graft without hydronephrosis. Since then, the patient has been regularly followed. He empties his pouch with intermittent self-catheterization 4-6 times in a 24-hour period. Currently, four years after transplantation, the patient is without surgical, immunological, or infective complications. The graft function is stable. In 2016, he became the father of fraternal twins with the help of assisted reproductive technology.

DISCUSSION

Currently the most common type of urinary diversion in the kidney transplant population is the ileal conduit (or Bricker operation). The use of a colon conduit was first described by Tunner et al in 1971 (5). Over time, these procedures have increased in number and type, but the overall number of KTs using urinary diversion is low.

The study with the largest number of transplanted patients with urinary diversion included 54 patients with 59 renal

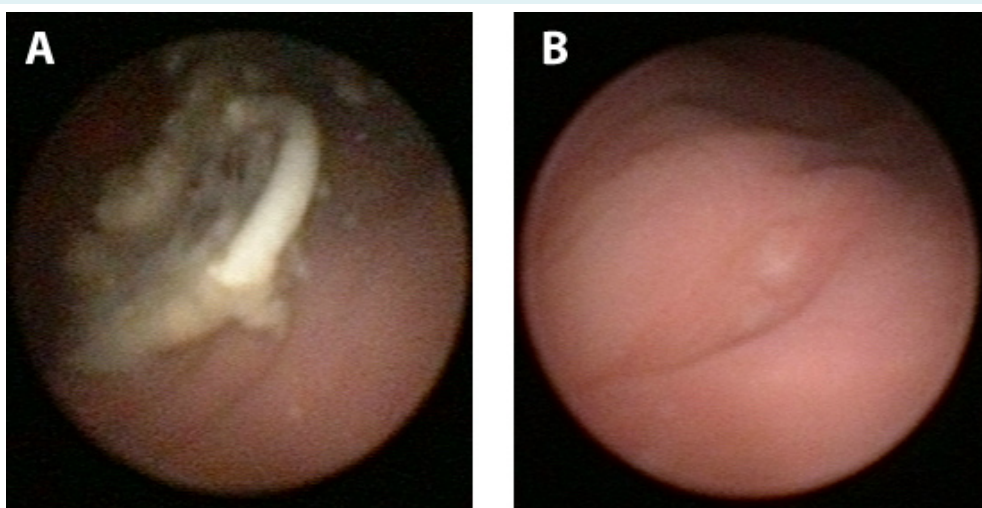


FIGURE 3. Endoscopic view of the colon pouch with ureteral endoprosthesis exiting from the ureteral orifice and partly embedded in mucus (A). Ureteral orifice after removal of the endoprosthesis (B).

transplants (6). All patients had an ileal conduit. The median patient age at the time of transplantation was 29.3 years. Graft survival at 1, 5, 10, and 15 years was 90%, 63%, 52%, and 52%, respectively. Patient survival was 95%, 83%, 69%, and 69%, respectively. Patients had many complications (especially urinary tract infections and complications related to the ileal conduit), but long-term graft and patient survival was comparable to that in the normal transplant population (6).

The experience of using the large bowel for urinary diversion in KT is very limited. In Table 2, we present the literature data about KT using a colon pouch, conduit, or neobladder (5,7-10). Kocot et al (10) presented their long-term results of 18 kidney transplant patients with different types of continent urinary diversion, in 3 of whom the colon was used. KT was performed 4-156 months after the creation of continent urinary diversion. Day and night continence was achieved in all patients with cutaneous urinary diversion and orthotopic substitution. Five patients (27.8%) were diagnosed with acute pyelonephritis rather than having bacterial colonization in all reservoirs. Kocot et al did not observe stenosis of the ureterointestinal anastomosis, although this is found in up to 6.5% of nontransplant patients (11). They found complications of continence mechanisms requiring surgical revision in 18.7% of patients, which is similar to the results of other studies (11). The second transplantation was performed in two patients with thrombosis of the renal vein and chronic graft dysfunction and two more patients resumed hemodialysis. In the remaining patients, with a mean follow-up of 90 months, kidney function was stable (10).

Mainz pouch III as a continent, colonic pouch was first introduced in 2000 (4). An experienced medical team from Mainz used this type of urinary diversion in 44 female patients with gynecological tumors after pelvic irradiation to avoid the use of irradiated bowel segments. There were no early complications, while late complications included incontinence in 2 (4.5%) patients (resolved with the creation of a new efferent segment) and stoma stenosis in 6 (13.6%) (4 treated with endoscopic incision and 2 underwent YV plastic). These satisfactory long-term results promoted this operation as a method of choice in patients with previous pelvic irradiation (4). Another study included 24 patients (6 nonirradiated patients) with Mainz pouch III continent urinary diversion (12). Twenty-two of these patients were treated because of malignancy (gynecological tumors, rhabdomyosarcoma of the prostate, bladder cancer) and 2 because of a benign disease (neurogenic bladder). The follow-up lasted up to 65 months. Twenty patients achieved complete continence (83.3%) and 4 (16.7%) used a protective pad between intermittent self-catheterization. The only pouch-related complication (outlet stenosis) was found in one patient (4.2%) and was surgically corrected.

In our center, we also started to use Mainz pouch III for urinary diversion in patients with gynecological tumors and after pelvic irradiation. This valuable experience allowed us to use this procedure as pretransplant preparation for our kidney transplant recipients. We want to point out that such operations should be performed in centers with adequate experience, especially in cases when, instead of one demanding operation, an intraoperative finding necessitates the use of a different, even more demanding, operation.

TABLE 2. Kidney transplantations using a colon pouch, conduit, or neobladder*

| Author | N | Urinary diversion | Age (years) | Cause of ESRD | Graft survival (months) | Patient survival (months) | Renal function (creatinine in $\mu\text{mol/L}$) | Complications |
|----------------|---|-----------------------------|-------------|-----------------------------------|-------------------------|---------------------------|---------------------------------------------------|---------------|
| Tunner (5) | 1 | sigmoid colon conduit | 11 | posterior urethral valves | unknown | unknown | 123 | unknown |
| Riedmiller (7) | 1 | sigmoid neobladder† | 50 | contracted bladder (tuberculosis) | 52 | 52 | 150 | unknown |
| | 1 | colon pouch† | 30 | myelomeningocele | 32 | 32 | 115 | unknown |
| Rigamonti (8) | 2 | sigmoid colon conduit | 17 | neurogenic bladder | 184 | 184 | 114 | UTIs |
| | | | 20 | neurogenic bladder | 148 | 148 | 142 | no |
| Ishida (9) | 1 | right colon pouch (Indiana) | 32 | neurogenic bladder | 12 | 12 | normal | no |
| Kocot (10) | 1 | sigmoid neobladder† | 50 | contracted bladder (tuberculosis) | 141 | 141 | 141 | unknown |
| | 1 | left colon pouch† | 30 | myelomeningocele | 128 | 128 | 176 | unknown |
| | 1 | sigmoid neobladder | 50 | bladder TCC | 13 | 13 | 106 | unknown |

*ESRD – end-stage renal disease; UTIs – urinary tract infections; TCC – transitional cell carcinoma.

†Same patients in different articles.

The patients who undergo this type of urinary diversion must be informed about the risks of the procedure, including the risks associated with self-catheterization, and should be assessed for compliance. Self-catheterization is mandatory in continent cutaneous diversion, and most authors agree that, although potentially complicated by chronic bacteriuria, it is safe for immunosuppressed transplant patients (10,13). The contraindications for this type of urinary diversion are colon impairment (colorectal cancer, stenosis, diverticular disease, short bowel syndrome) and inadequate compliance (14). The follow-up by urologists includes standard surveillance with determination of acid-base balance and stoma-related problems (incontinence, impaired catheterization) (10). After 3 years of follow-up, it is advisable to perform a yearly pouch endoscopy for malignancy screening (10).

This technique has some advantages compared with ileal or ileocolonic urinary diversion: preservation of the ileocecal valve (without negative influence on stool frequency and enterohepatic circulation), normal intake of vitamin B12, and normal bile acids absorption (12,14). Another advantage of Mainz pouch III is that the efferent limb is created with use of the large bowel instead of the small bowel. The large bowel has a wider lumen than the appendix (frequently used in the other types of pouches), allowing the use of a larger catheter. Additionally, it is easier to flush the reservoir to remove mucus and to perform pouchoscopy of the large bowel, if needed, using both pediatric and adult instruments (12). The main disadvantage is that the operation is relatively complicated compared with the creation of a simple ileal conduit. Additionally, urologists are much more familiar with the use of an ileal segment than the large bowel.

The population of KT patients with urinary diversion is small, and their outcomes are difficult to compare due to different types of operations. The 5-year graft survival is up to 78% and 15-year graft survival is up to 69% (6,8,15-17).

The use of bowel segments in urinary diversion in KT patients is associated with an increased incidence of urinary infections, metabolic changes, and possible tumor development. A few studies reported that chronic bacteriuria or urinary tract infections (UTIs) did not lead to graft loss, but the incidence of UTIs was high (15,17,18). In other studies, severe UTIs were responsible for graft loss in KT patients with urinary diversion (19,20). The most prevalent opinion today is that urinary diversion significantly increases morbidity in KT patients but does not affect graft and patient outcome (21).

Different studies show different prevalence of metabolic changes – from no changes to 85% (8,18,22). The most prevalent type of metabolic imbalance is metabolic acidosis (23-25). Therefore, these patients need to be regularly checked for acid-base balance.

The development of neoplasms, mainly due to chronic immunosuppression, is a well-known possible long-term complication of organ transplantation. Primary neoplasms can be found in urinary diversion in nontransplanted patients (26). There is only one reported case of primary adenocarcinoma of an ileal conduit in a renal transplant patient, which manifested 19 years after KT (27). It has not been elucidated yet which is the proper screening protocol after KT with urinary diversion because of limited data but it could be a combination of urinalysis, urine cytology, imaging techniques, and pouch endoscopy (10,27).

In conclusion, the native bladder is the most efficient reservoir used for KT. Patients with severe anatomical or functional abnormalities of the lower urinary tract require urinary diversion before transplantation. Mainz-pouch III, as a colon continent pouch, can be used as a reliable type of urinary diversion in selected transplant patients.

Acknowledgment We thank Assist Prof. Maksim Valenčić, the former head of the Department of Urology and our teacher, who performed a substantial number of Mainz-pouch III operations and started using different urinary diversions in transplanted patients.

Funding None.

Ethical approval The patient provided informed consent for publication of data and images.

Declaration of authorship DM and SR conceived and designed the study; DM, RO, KK, AI, DP and JŠ acquired the data; DM, AG, IV and AI analyzed and interpreted the data; DM, RO and DP drafted the manuscript; DM, KK, AG, IV, SR, AI and JŠ critically revised the manuscript for important intellectual content; all authors gave approval of the version to be submitted; all authors agree to be accountable for all aspects of the work.

Competing interests All authors have completed the Unified Competing Interest form at www.icmje.org/coi_disclosure.pdf (available on request from the corresponding author) and declare: no support from any organization for the submitted work; no financial relationships with any organizations that might have an interest in the submitted work in the previous 3 years; no other relationships or activities that could appear to have influenced the submitted work.

References

- 1 Kelly W, Merkel F, Markland C. Ileal urinary diversion in conjunction with renal homotransplantation. *Lancet*. 1966;1:222-6.
[Medline:4159068 doi:10.1016/S0140-6736\(66\)90049-3](#)
- 2 Cerilli J, Anderson GW, Evans WE, Smith JP. Transplantation in patients with urinary tract abnormalities. *Surgery*. 1976;79:248-52.
[Medline:769210](#)
- 3 Crowe A, Cairns HS, Wood S, Rudge CJ, Woodhouse CR, Neild GH. Renal transplantation following renal failure due to

- urological disorders. *Nephrol Dial Transplant*. 1998;13:2065-9. [Medline:9719166](#) [doi:10.1093/ndt/13.8.2065](#)
- 4 Leissner J, Black P, Fisch M, Hockel M, Hohenfellner R. Colon pouch (Mainz pouch III) for continent urinary diversion after pelvic irradiation. *Urology*. 2000;56:798-802. [Medline:11068305](#) [doi:10.1016/S0090-4295\(00\)00789-5](#)
 - 5 Tunner WS, Whitsell JC, Rubin AL, Stenzel KH, David DS, Riggio RR, et al. Renal transplantation in children with corrected abnormalities of the lower urinary tract. *J Urol*. 1971;106:133-9. [Medline:4935504](#) [doi:10.1016/S0022-5347\(17\)61241-2](#)
 - 6 Surange RS, Johnson RWG, Tavakoli A, Parrott NR, Riad HN, Campbell BA, et al. Kidney transplantation into an ileal conduit: a single center experience of 59 cases. *J Urol*. 2003;170:1727-30. [Medline:14532763](#) [doi:10.1097/01.ju.0000092023.39043.67](#)
 - 7 Riedmiller H, Gerharz EW, Kohl U, Weingartner K. Continent urinary diversion in preparation for renal transplantation. *Transplantation*. 2000;70:1713-7. [Medline:11152102](#) [doi:10.1097/00007890-200012270-00009](#)
 - 8 Rigamonti W, Capizzi A, Zacchello G, Capizzi V, Zanon GF, Montini G, et al. Kidney transplantation into bladder augmentation or urinary diversion: long-term results. *Transplantation*. 2005;80:1435-40. [Medline:16340788](#) [doi:10.1097/01.tp.0000174342.19265.f4](#)
 - 9 Ishida H, Teranishi J, Hattori Y, Hanai T, Koizumi M, Noguchi K. Kidney transplantation in a patient with an Indiana pouch: a case report. *Nippon Hinyokika Gakkai Zasshi*. 2015;106:45-8. [Medline:26399131](#)
 - 10 Kocot A, Spahn M, Loeser A, Lopau K, Gerharz EW, Riedmiller H. Long-term results of a staged approach: continent urinary diversion in preparation for renal transplantation. *J Urol*. 2010;184:2038-42. [Medline:20850827](#) [doi:10.1016/j.juro.2010.06.111](#)
 - 11 Wiesner C, Bonfig R, Stein R, Gerharz EW, Pahernik S, Riedmiller H, et al. Continent cutaneous urinary diversion: long-term follow-up of more than 800 patients with ileocecal reservoirs. *World J Urol*. 2006;24:315-8. [Medline:16676186](#) [doi:10.1007/s00345-006-0078-y](#)
 - 12 Stolzenburg JU, Schwalenberg T, Liatsikos EN, Sakelaropoulos G, Rodder K, Hohenfellner R, et al. Colon pouch (Mainz III) for continent urinary diversion. *BJU Int*. 2007;99:1473-7. [Medline:17346278](#) [doi:10.1111/j.1464-410X.2007.06767.x](#)
 - 13 Gill IS, Hayes JM, Hodge EE, Novick AC. Clean intermittent catheterization and urinary diversion in the management of renal transplant recipients with lower urinary tract dysfunction. *J Urol*. 1992;148:1397-400. [Medline:1433536](#) [doi:10.1016/S0022-5347\(17\)36920-3](#)
 - 14 Leissner J, Fisch M, Hohenfellner R. Colonic pouch (Mainz-pouch III) for continent urinary diversion. *BJU Int*. 2006;97:417-30. [Medline:16430663](#) [doi:10.1111/j.1464-410X.2006.06052.x](#)
 - 15 Warholm C, Berglund J, Andersson J, Tyden G. Renal transplantation in patients with urinary diversion: a case-control study. *Nephrol Dial Transplant*. 1999;14:2937-40. [Medline:10570101](#) [doi:10.1093/ndt/14.12.2937](#)
 - 16 Srinivasan D, Stoffel JT, Mathur AK, Kapeles S, Bradley K, Sung RS. Long-term outcomes of kidney transplant recipients with bladder dysfunction: a single-center study. *Ann Transplant*. 2016;21:222-34. [Medline:27090659](#) [doi:10.12659/AOT.895975](#)
 - 17 Hatch DA, Koyle MA, Baskin LS, Zaontz MR, Burns MW, Tarry WF, et al. Kidney transplantation in children with urinary diversion or bladder augmentation. *J Urol*. 2001;165:2265-8. [Medline:11371960](#) [doi:10.1016/S0022-5347\(05\)66181-2](#)
 - 18 Djakovic N, Wagener N, Adams J, Gilfrich C, Haferkamp A, Pfitzenmaier J, et al. Intestinal reconstruction of the lower urinary tract as a prerequisite for renal transplantation. *BJU Int*. 2009;103:1555-60. [Medline:19076129](#) [doi:10.1111/j.1464-410X.2008.08264.x](#)
 - 19 Mendizabal S, Estornell F, Zamora I, Sabater A, Ibarra FG, Simon J. Renal transplantation in children with severe bladder dysfunction. *J Urol*. 2005;173:226-9. [Medline:15592081](#) [doi:10.1097/01.ju.0000148369.34519.86](#)
 - 20 Alfrey E, Conley SB, Tanney DC, Mak R, Scandling JD, Dafoe DC, et al. Use of an augmented urinary bladder can be catastrophic in renal transplantation. *Transplant Proc*. 1997;29:154-5. [Medline:9122939](#) [doi:10.1016/S0041-1345\(96\)00045-0](#)
 - 21 Eltemamy M, Crane A, Goldfarb D. Urinary diversion in renal transplantation. *Urol Clin North Am*. 2018;45:113-21. [Medline:29169444](#) [doi:10.1016/j.ucl.2017.09.012](#)
 - 22 Koo HP, Bunchman TE, Flynn JT, Punch JD, Schwartz AC, Bloom DA. Renal transplantation in children with severe lower urinary tract dysfunction. *J Urol*. 1999;161:240-5. [Medline:10037414](#) [doi:10.1016/S0022-5347\(01\)62119-0](#)
 - 23 Yakupoglu HY, Corsenca A, Wahl P, Wuthrich RP, Ambuhl PM. Post-transplant acidosis and associated disorders of mineral metabolism in patients with a renal graft. *Transplantation*. 2007;84:1151-7. [Medline:17998871](#) [doi:10.1097/01.tp.0000287430.19960.0e](#)
 - 24 Miyake H, Hara S, Eto H, Arakawa S, Kamidono S, Hara I. Significance of renal function in changes in acid-base metabolism after orthotopic bladder replacement: colon neobladder compared with ileal neobladder. *Int J Urol*. 2004;11:83-7. [Medline:14706011](#) [doi:10.1111/j.1442-2042.2004.00749.x](#)
 - 25 Airoidi A, Volpe A, Billia M, Marchioro G, Fenoglio R, Lazzarich E, et al. Is renal living-donor transplantation indicated in adult patients with orthotopic ileal neobladder? Lessons learned from a clinical case. *Eur Urol*. 2010;58:788-91. [Medline:19493610](#) [doi:10.1016/j.eururo.2009.05.020](#)
 - 26 Filmer RB, Spencer JR. Malignancies in bladder augmentations and intestinal conduits. *J Urol*. 1990;143:671-8. [Medline:2179579](#) [doi:10.1016/S0022-5347\(17\)40055-3](#)
 - 27 Matulewicz RS, Fryer JP, Yang XJ, Goyal R, Hairston JC. Renal transplantation in the setting of prior urinary diversion: a case of poorly differentiated adenocarcinoma in an ileal conduit. *Urol Case Rep*. 2015;3:53-5. [Medline:26793500](#) [doi:10.1016/j.eucr.2015.01.001](#)