

Carpal Tunnel Release by Limited Palmar Incision vs Traditional Open Technique: Randomized Controlled Trial

Izabela Jugovac, Nijaz Burgić¹, Vladimir Mićović², Lorena Radolović-Prenc³, Miljenko Uravić⁴, Vesna Golubović⁵, Marin F. Stančić

Division of Neurosurgery, Pula General Hospital, Pula; ¹Private Practice, Umag; ²Department of Healthcare and Environmental Medicine, Rijeka University School of Medicine, Rijeka; ³Department of Neurology, Pula General Hospital, Pula; ⁴Departments of Surgery and ⁵Anesthesiology, Rijeka University Hospital Center, Rijeka, Croatia

Aim. To compare a limited palmar incision for carpal tunnel release (CTR) with a traditional open technique, which is still considered the gold standard.

Methods. Seventy-two patients with a carpal tunnel syndrome were individually randomized into the trial (limited incision CTR) (n = 36) and control group (traditional technique CTR) (n = 36). In the trial group, skin incision parallel to the thenar crease was made up to 2.5 cm in length, under an operating microscope and endoscopic transillumination. Skin incision in the control group began at the distal border of the carpal ligament, followed the longitudinal crease of the palm, and crossed the base of the palm in a zigzag fashion. Three months after surgery, the patients were asked about symptomatic relief and intervals between the operation and return to their daily activities and work, and examined for scar tenderness and esthetic outcome. Distal motor latency, conduction velocity, scar length, scar width, and operation time were measured.

Results. There were no differences between the two groups in symptomatic relief and electrophysiological parameters. Intervals between the operation and return to daily activities (median 5 days, range 2-15) were shorter in the trial group than in the control group (median 10 days, range 2-21; p = 0.001), as well as the intervals between the operation and return to work (median 15 days, range 5-45 vs median 30 days, range 10-60; p = 0.001). Scar/pillar tenderness, scar length and width, esthetic outcome, and operation time were significantly better in the trial group.

Conclusion. Limited palmar incision CTR is as effective and safe as traditional CTR technique, but with better postoperative recovery and cosmetic results.

Key words: carpal tunnel syndrome; endoscopy; microsurgery; surgical procedures, minimally invasive

Carpal tunnel syndrome is the most common compressive neuropathy, and the median nerve decompression in the carpal region is the most frequent peripheral nerve surgery (1-3). Major textbooks of operative hand surgery, peripheral nerve surgery, and operative neurosurgical techniques recommend a traditional open-incision technique with longitudinal incision crossing the wrist flexion skin crease as highly effective approach in the treatment of carpal tunnel syndrome, with low percentage of complications (1-3). However, there are two main weaknesses of the traditional open carpal tunnel release. First, the scar is usually hypertrophic and sensitive, and a major source of complications (1,2). Second, the incision of the fascial convergence between the thenar and hypothenar is responsible for slower postoperative recovery (4). The challenge to perform carpal tunnel release without incising the fascial convergence and wrist crease has stimulated the development of several different endoscopic and microsurgical minimally invasive techniques (4-6). Anatomical studies

showed that an endoscopic carpal tunnel release does not allow an adequate exploration of the thenar branch of the median nerve and decompression of its transligamentous variation (7). An endoscopic technique also endangers the ulnar and median nerves, branches of the median nerve, and communication between the two nerves both in the carpal tunnel and in the distal forearm (8-13). Some reports suggest that a minimally invasive open surgery could reduce a tissue trauma with the same effectiveness and safety as the traditional open carpal tunnel release (4-6). We conducted a randomized controlled trial to evaluate the limited palmar incision technique against the traditional approach.

Patients and Methods

Patients

According to the power analysis (14), an appropriate sample size required for each comparison group was 36 subjects. The trial and control groups were assumed to be of equal size. There was a 90% certainty that a clinically important difference

of 0.70 standard deviations would be detected between the groups ($\alpha=0.05$; $\beta=0.90$)

Inclusion criteria were a typical medical history of carpal tunnel syndrome, hypoesthesia of 256 Hz for vibration sense, distal motor latency greater than 5 ms, and/or a sensory nerve conduction velocity less than 30 m/s. The exclusion criterion was trauma-induced carpal tunnel syndrome.

Ethics Committee of the Pula General Hospital approved the clinical trial. Each patient included in the study had been informed before the surgery that he or she would undergo one of the two equally efficient surgical techniques, and be allocated to either the trial or control group.

Surgical Treatment

Patients in the trial group were operated on in regional anesthesia, using an operating microscope. Skin incision parallel to the thenar crease was made in length up to 2.5 cm above the distal part of the transverse carpal ligament (Fig. 1). The ligament was incised and the carpal tunnel decompressed in its distal part. The incision of a proximal ligament part was performed subcutaneously with a flexed wrist. Both the distal part of the forearm and the palm of the hand were transilluminated with a choledochoscope to control the completeness of decompression (5).

The patients from control group were also operated on in regional anesthesia. Operating loupes with x2.5 magnification were used and the carpal tunnel was released by Eversmann technique (Fig. 1). The incision began at the distal border of the transverse carpal ligament, followed the longitudinal crease of the palm in a "zigzag" fashion ulnar to the longitudinal axis of the ring finger, and continued into the forearm. In the proximal por-

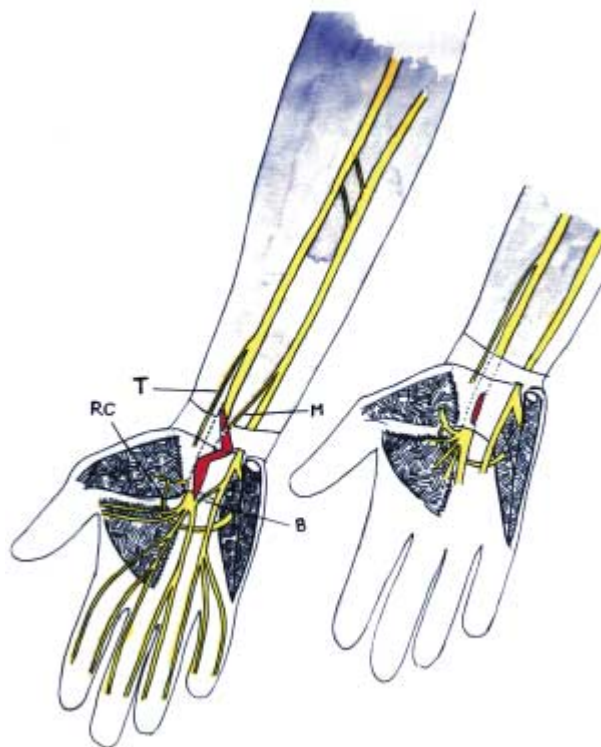


Figure 1. Anatomical relation of the median and the ulnar nerves, the median nerve branches, and its variations are crucial in surgical incisions placement. **Left:** incision in the traditional open carpal tunnel release. **Right:** incision in the limited palmar carpal tunnel release. T – palmar cutaneous branch of the median nerve (Taleisnik branch), M – ulnar-to-median nerve communication in the distal forearm (Marinacci communication), B – superficial palmar communication between the ulnar nerve and the median nerve (Berrettini branch), and RC – a communication between motor branch of the median nerve and the deep branch of the ulnar nerve (Riche-Cannieu anastomosis).

tion of the incision, the forearm fascia was isolated and divided longitudinally. The median nerve was identified and protected. The transverse carpal ligament was divided along the ulnar aspect of the median nerve to protect the median motor branches (1-3). The thenar branch of the median nerve was exposed and, if its course was transligamentous, a further decompression was performed (1-3).

Primary Endpoints

Three months after surgery, patients with covered scar region were sent to the first independent investigator, physiatrist or neurologist (NB or LPR). Data on sensibility, thumb abduction, distal motor latency, conduction velocity, and satisfaction with the operative outcome were labeled with code numbers, and entered into the database by the third independent investigator (VM).

Secondary Endpoints

During the same visit, the second independent investigator, a medical student (IJ), asked the patients about the time elapsed between the surgery and their return to daily activities and work, according to their own appraisal. The student examined the incision region for scar and radial or ulnar pillar tenderness, measured scar length and width, and assessed cosmetic appearance of the scar using grades 1 to 5. The neurosurgeon (MFS) annotated the duration of operations.

Masking and Follow-up

The patients were included into the study by the first independent investigator (NB or LPR), according to the inclusion and exclusion criteria and their own consent. Selected patients were referred to the second independent investigator (IJ), who randomized them into two groups using a 10-number-per-block randomization. The two surgical procedures were concealed in envelopes. The envelopes were consecutively numbered according to the number assigned to each patient included in the study. The type of operation was unknown to a patient and to the surgeon until after the patient had given the written consent. Each patient's medical records were labeled with patient's record number and forwarded to the third independent investigator (VM) for statistical analysis. Three months after surgery, investigators independently checked primary and secondary endpoints.

Statistical Analysis

The following observed parameters were used in the statistical analysis of differences between the groups: electrophysiological findings (distal motor latency and sensory nerve conduction velocity), hand function (return to daily activities and return to work), cosmetic results (scar length, scar width, and esthetic outcome), and operation time. The differences were calculated with the one-way analysis of variance (1W-ANOVA) and, if significant, *post hoc* comparisons using independent sample t-test were performed. Chi-square test was used for comparisons between the two groups in frequency distribution of scar and ulnar or radial pillar tenderness.

Results

Between September 9, 1997 and January 30, 2001, 72 patients entered in the study (Table 1). Eight patients were excluded because their carpal tunnel syndrome was caused by trauma. Patients in the trial group were operated on using the limited incision technique for carpal tunnel release. There were 5 men and 31 women in the trial group (mean age, 54.2 ± 8.9 years). Patients from the control group (mean age 52.5 ± 9.7 years; 13 men and 23 women) were operated on using traditional open technique for carpal tunnel release. Each patient suffered pain and paresthesia in the distribution of the median nerve. The pain was more intensive at night or after specific activities.

Three months after surgery, patients from both groups derived the identical symptomatic relief outcome (Table 2). Furthermore, there were no signs of

Table 1. Characteristics of patients undergoing limited incision carpal tunnel release (n = 36) and those undergoing traditional open carpal tunnel release (n = 36)

Patients (N = 72)	Surgical technique	
	limited incision	traditional
Sex (men/women)	5/31	13/23
Age (mean \pm SD, years)	54.2 \pm 8.9	52.5 \pm 9.7
Side (right/left)	23/13	22/14
Work (manual/agricultural/intellectual)	12/6/18	13/15/8
Diabetes mellitus	4	2
Other endocrinopathies	3	2

Table 2. Symptomatic relief and electrophysiological comparison between the trial and control group as a measure of the efficacy and safety of limited incision carpal tunnel release technique

Primary endpoints	Surgical technique		
	limited incision	p	traditional
Symptomatic relief after the procedure (No. of patients):			
complete	31	1.000	31
near-complete	5	1.000	5
complications	0	1.000	0
Electrophysiological findings (mean \pm SD):			
distal motor latency (ms)	4.12 \pm 0.90	0.425	4.08 \pm 0.80
sensory nerve conduction velocity (m/s)	41.86 \pm 8.50	0.195	43.67 \pm 9.00

Table 3. Secondary endpoints served to measure the invasiveness of surgery

Secondary endpoints	Surgical technique used for carpal tunnel release		
	limited incision	p	traditional
Hand function			
return to daily activities (days) ^a	5 (2-15)	0.001	10 (2-21)
return to work (days) ^a	15 (5-45)	0.001	30 (10-60)
Cosmetic results			
scar length (mm) ^b	2.3 \pm 0.2	0.001	5.0 \pm 1.1
scar width (mm) ^b	1.6 \pm 0.5	0.001	2.2 \pm 0.9
esthetic outcome /1-5 ^{b,c}	5 (3-5)	0.036	4 (2-5)
Tenderness	3/36	0.006	8/36
Operation time (min) ^b	9.5 \pm 1.1	0.001	11.1 \pm 1.2

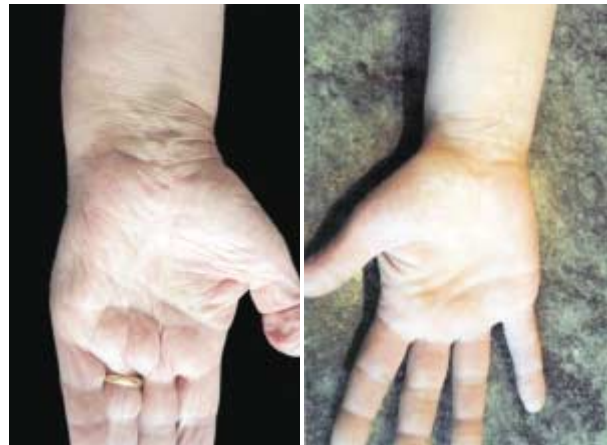^aResults are expressed as median (range).

^bResults are expressed as mean \pm SD.

^cGrades used for assessment: 1 – unsatisfactory, 2 – fair, 3 – good, 4 – very good, and 5 – excellent.

iatrogenic injuries of the palmar cutaneous branch, superficial palmar communication between the median and the ulnar nerve, or motor thenar branch in both groups. There was no significant difference in postoperative electrophysiological findings between the trial and control group (Table 2).

Postoperative scars in the patients operated by traditional open technique for carpal tunnel release were significantly longer than the scars in the patients operated by limited palmar incision technique (Table 3). Thus, esthetic outcomes were better in the group operated by limited palmar incision technique than in traditional technique group (Table 3 and Fig. 2). Three patients in the trial group and 8 patients in the control group complained of scar or pillar tenderness ($p=0.006$). Operation time was on average 1.6 min shorter in the trial group (Table 3).

**Figure 2.** Cosmetic outcome after traditional open technique (left) and limited palmar incision (right) for carpal tunnel release.

Discussion

For almost 50 years, open technique for carpal tunnel release has been a reliable approach for surgeons to relieve symptoms of carpal tunnel syndrome. Recently, some endoscopic and minimally invasive surgical techniques have been developed to decrease the invasiveness of the surgery (4-6). In last few years, there has been intense debate over the "optimal" technique for carpal tunnel release (4,15,16). Lee and Strickland (4) reported very promising results of limited palmar incision technique they used on a series of 525 patients. Shapiro (6) published similarly good results on a series of 482 patients who underwent microsurgical carpal tunnel release. In this trial, we compared the traditional open technique as a gold standard with a microsopic limited incision technique for the first time, and showed that both techniques were equally effective and safe. However, parameters such as intervals between the surgery and return to daily activities and work, scar and pillar tenderness, scar length, scar width, esthetic outcome, and operation time were significantly better in patients who underwent limited palmar incision for carpal tunnel release. Therefore, this approach can be recommended as a less invasive surgical technique.

Our study had at least two weaknesses. First, the group of patients included into trial was small, because the study was conducted in the county hospital where the frequency of surgeries of entrapment neuropathies was relatively low. Power analysis showed that 36 patients per group was the lowest possible number that gives valid results. The second limitation was that, when the trial was planned, we did not predict that worker's compensation would have such a great influence on the interval between the operation and return to work. Patients who had carpal tunnel release done through limited palmar incision and had worker's compensation returned to work significantly later, which caused great overlap between the trial and the control group results and made them less confident (15).

Lee and Strickland (4) introduced a limited palmar incision technique to preserve a fascial convergence between the thenar and the hypothenar and to avoid skin incision crossing wrist crease. These two anatomical structures are the most important for quick postoperative recovery. They used a skin incision up to 1.5 cm in length over the distal part of the carpal ligament. The division of the distal part of the carpal ligament is performed under direct vision, whereas the proximal part of the ligament is blindly divided by a specially designed "carpal tunnel tome". Shapiro (6) described the microsurgical technique with an incision up to 1 cm longer, which allowed the division of the whole ligament under direct vision. The proximal end of the incision is at least 5 mm away from the wrist crease and the convergence between the thenar and the hypothenar is still partially preserved, which are the goals of the minimally invasive technique (15). We preferred incision under direct vision to prevent nerve branch injury, which is the first complication of carpal tunnel release and occurs due to numerous anatomical variations (7,12,13). Furthermore, the thenar branch can be explored and further decompressed, only under direct vision (1,2).

An incomplete section of the ligament is the second commonest complication and may occur when the operative field is not widely opened (4,5,11,15,18). Franzini et al (5) described the use of transillumination in a minimally invasive carpal tunnel release using a modified Paine retinaculotome to secure a completeness of ligament transaction. For transillumination we used a choledochoscope available in our operating theater because the price of a single-use retinaculotome with light is around US\$100, whereas the surgery itself costs US\$10.

Our next step will be the comparison between limited incision and an endoscopic technique for carpal tunnel release. Endoscopy is a rapidly developing technique, but today still connected with serious complications. We hope that in time the endoscopy will carry less risk of complications, which will allow us to do further research for the benefit of our patients.

Acknowledgement

This study was supported by Croatian Ministry of Science and Technology grant No. 0062076 to Dr Marin F. Stančić.

References

- 1 Eversmann WW. Entrapment and compression neuropathies. In: Green DP, editor. Operative hand surgery. New York (NY): Churchill Livingstone; 1988. p. 1423-78.
- 2 Gelberman HR. Carpal tunnel release. In: Gelberman RH, North ER, editors. Operative nerve repair and reconstruction. 2 vol. Philadelphia (PA): JB Lippincott; 1991. p. 900-11.
- 3 Young HA. Surgical management of peripheral entrapment neuropathy. In: Schmidek HH, Sweet WH, editors. Operative neurosurgical techniques. Indications, methods, and results. Philadelphia (PA): WB Saunders; 1988. p. 1583-98.
- 4 Lee WP, Strickland JW. Safe carpal tunnel release via a limited palmar incision. *Plast Reconstr Surg* 1998;101: 418-24.
- 5 Franzini A, Broggi G, Servello D, Dones I, Pluchino MG. Transillumination in minimally invasive surgery for carpal tunnel release. Technical note. *J Neurosurg* 1996;85:1184-6.
- 6 Shapiro S. Microsurgical carpal tunnel release. *Neurosurg Focus* [electronic resource] 1997;3:Article No. 3. Available at: <http://www.neurosurgery.org/focus/july97/3-1-3.html>. Accessed: July 23, 2001.
- 7 Stančić MF, Eškinja N, Stošić A. Anatomical variations of the median nerve in the carpal tunnel. *Int Orthop* 1995;19:30-4.
- 8 Nath RK, Mackinnon SE, Weeks PM. Ulnar nerve transection as a complication of two-portal endoscopic carpal tunnel release: a case report. *J Hand Surg (Am)* 1993;18:896-8.
- 9 del Pinal F, Cruz-Camara A, Jado E. Total ulnar nerve transection during endoscopic carpal tunnel release. *Arthroscopy* 1997;13:235-7.
- 10 Shinya K, Lanzetta M, Conolly WB. Risk and complications in endoscopic carpal tunnel release. *J Hand Surg (Br)* 1995;20:222-7.
- 11 Palmer AK, Toivonen DA. Complications of endoscopic and open carpal tunnel release. *J Hand Surg (Am)* 1999;24:561-5.
- 12 Stančić MF, Mićović V, Potočnjak M. The anatomy of the Berrettini branch: implications for carpal tunnel release. *J Neurosurg* 1999;91:1027-30.
- 13 Stančić MF, Burgić N, Mićović V. Marinacci communication. Case report. *J Neurosurg* 2000;92:860-2.
- 14 Weast RC. CRC Handbook of tables for probability and statistics. 2nd ed. Boca Raton (FL): CRC Press; 1968. p. 260.
- 15 Olney JR, Quenzer DE, Makowsky M. Contested claims in carpal tunnel surgery: outcome study of worker's compensation factors. *Iowa Orthop J* 1999;19:111-21.
- 16 Wheatley MJ, Hall JW, Pratt D, Faringer PD. Is training in endoscopic carpal tunnel release appropriate for residents? *Ann Plast Surg* 1996;37:254-7.
- 17 Forman DL, Watson HK, Caulfield KA, Shenko J, Caputo AE, Ashmead D. Persistent or recurrent carpal tunnel syndrome following prior endoscopic carpal tunnel release. *J Hand Surg (Am)* 1998;23:1010-4.
- 18 Hirooka T, Hashizume H, Senda M, Nagoshi M, Inoue H, Nagashima H. Adequacy and long term prognosis of endoscopic carpal tunnel release. *Acta Med Okayama* 1999;53:39-44.

Received: September 28, 2001

Accepted: January 15, 2002

Correspondence to:

Marin F. Stančić
Division of Neurosurgery
Pula General Hospital- Marinespital MDCCCLXI
Negrijeva 6
52100 Pula, Croatia
marin.stancic@pu.tel.hr