

## Continuous Systemic Perfusion via Collaterals at Moderate Hypothermia in Aortic Arch Repairs in Neonates

László Király, Zsolt Prodán

*Department of Cardiac Surgery, Pediatric Cardiac Centre, Gottsegen Hungarian Institute of Cardiology, Budapest, Hungary*

**Aim.** To present our experience with modified cannulation with continuous, moderately hypothermic systemic perfusion in extensive aortic arch repair. The technique has fewer complications and preserves cerebral blood flow autoregulation.

**Method.** Nine neonates, 6 with the hypoplastic left heart syndrome and 3 with the interrupted aortic arch with ventricular septal defect, were surgically treated with this technique between June and December 2001. Before extracorporeal circulation, 3.5-mm polytetrafluoroethylene tube was sutured onto the innominate artery and the arterial perfusion cannula inserted into the tube. Aortic arch repair was then performed with extracorporeal circulation. Right radial artery and femoral artery pressures were continuously monitored. Perfusion flows were built up gradually, with strict attention to the upper body (right radial artery) pressures not to exceed normal values. Procedures were carried out at moderate hypothermia ( $> 28^{\circ}\text{C}$ ), preferably with the beating heart.

**Results.** No morbidity or mortality attributable to continuous perfusion occurred. Mean $\pm$ SD extracorporeal circulation duration was  $114\pm 26$  min. Maximum perfusion rate (actual/required flow for body surface area) was 1.65 at normal perfusion pressures. Right radial artery pressure at full flow ( $\geq 2.2$  L/m<sup>2</sup>/min) was  $56.1\pm 6.7$  mm Hg, whereas femoral artery pressure was  $34.2\pm 8.2$  mm Hg. Decrease in right radial-to-femoral artery pressure was  $21.9\pm 5.6$  mm Hg. The lowest nasopharyngeal temperature was  $28.5^{\circ}\text{C}$ . There were no neurologic complications.

**Conclusion.** Continuous, moderately hypothermic systemic perfusion via collaterals seems to be a method of choice in aortic arch repair in neonates. As there is no need for deep hypothermic total circulatory arrest, its numerous sequelae, such as increased postoperative bleeding and permanent neurologic deficit, can be avoided.

**Key words:** cardiac surgical procedures; cardiopulmonary bypass; heart defects, congenital; hypoplastic left heart syndrome; infant, newborn; intraoperative period; perfusion; surgical procedures, operative; treatment outcome

Glauser et al (1) reported that in complex palliative procedures, such as first-stage palliation of hypoplastic left heart syndrome, neurologic injury occurred in as many as 45% of the neonates. Permanent neurologic deficit, choreoathetosis, increased postoperative bleeding, and other sequelae have been attributed to deep hypothermic total circulatory arrest. Deep hypothermic total circulatory arrest, however, offers bloodless operating field and thus makes complex aortic arch repairs easier to perform. Various methods have been suggested to eliminate the need for the systemic perfusion during arch repairs (2-8). Asou et al (2) introduced selective cerebral perfusion via polytetraethylene tube sutured to the innominate artery. Pigula et al (4) demonstrated that reduced flow rates at selective perfusion maintained adequate lower body perfusion via collaterals. All alternative perfusion techniques use deep hypothermia and low flow rates. We present our preliminary experience in

modified cannulation, with the possible benefits of moderately hypothermic continuous systemic perfusion, which eliminates the risk of neurologic injury associated with total circulatory arrest during extensive arch repairs.

### Patients and Methods

Between June and December 2001, we surgically treated 9 neonates (5 boys and 4 girls), using modified cannulation with continuous, moderately hypothermic systemic perfusion. The median age of neonates was 4 days (range, 2-21 days), and their median weight was 2.9 kg (range, 2.5-3.6 kg) (Table 1). Six neonates had hypoplastic left heart syndrome, and 3 had interrupted aortic arch and ventricular septal defect. Aortic atresia associated with an ascending aorta of 2 mm in diameter was found in all 6 patients. Patient No. 6 had biventricular morphology and large ventricular septal defect, with aortic atresia and diminutive ascending aorta, hypoplastic transverse aortic arch, and coarctation. The morphology seemed encouraging for a future reestablishment of biventricular circulation.

**Table 1.** Demographic data, diagnosis, and surgical data of 9 neonates with hypoplastic left heart syndrome or interrupted aortic arch with ventricular septal defect operated at Gottsegen Hungarian Institute of Cardiology between June and December 2001<sup>a</sup>

Patient	Age (days)	Weight (kg)	Sex	Diagnosis	Operation	ECC (min)	AoCC (min)	Arch (min)	Outcome
1	2	2.9	M	HLHS, AA, MS	mod Norwood I	93	–	44	alive
2	3	2.8	M	HLHS, AA, MS	mod Norwood I	108	–	41	alive
3	3	2.8	M	HLHS, AA, MS	mod Norwood I	114	–	37	alive
4	4	3.1	M	HLHS, AA, MS	mod Norwood I	89	–	39	died
5	4	3	F	HLHS, AA, MS	mod Norwood I	110	–	51	died
6	10	2.5	F	HLHS equivalent AA, huge VSD	mod Norwood I	85	–	19	alive
7	21	2.9	F	Type B IAA, VSD, SAS, ARSCA	complete repair	118	63	38	alive
8	4	3.6	M	Type B IAA, VSD, SAS	complete repair	140	74	56	alive
9	5	2.7	F	Type A IAA, VSD	complete repair	85	35	20	alive

<sup>a</sup>Abbreviations: AA – aortic atresia, AoCC – aortic crossclamp time; Arch – arch repair duration; ARSCA – anomalous right subclavian artery; ECC – extracorporeal circulation duration; F – female; HLHS – hypoplastic left heart syndrome; IAA – interrupted aortic arch; M – male; MA – mitral atresia; mod Norwood I – modified Norwood Stage I operation; SAS – subaortic stenosis; VSD – ventricular septal defect.

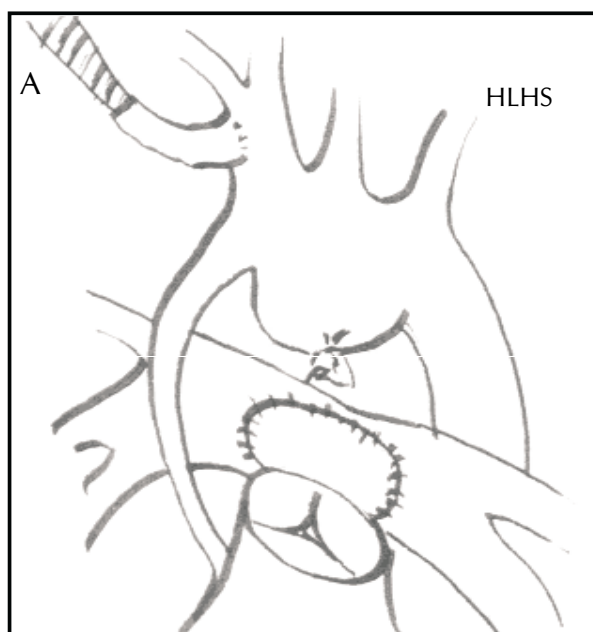
In two patients, type-B interrupted aortic arch (an interruption between the innominate artery and the left carotid artery) and ventricular septal defect were associated with DiGeorge syndrome. Small ascending aorta (<5 mm in diameter) was found in two neonates with interrupted aortic arch, coupled with subaortic stenosis.

All neonates received prostaglandin E<sub>1</sub> infusion preoperatively. The first 3 neonates were operated on an emergency basis, whereas others underwent 3 days of stabilization before the repair. In neonates with hypoplastic left heart syndrome, the surgical aim was to create a nonobstructive systemic outlet and pulmonary (venous) inlet to the main (right) ventricle with well-balanced systemic-to-pulmonary flow ratio. For interrupted aortic arch combined with ventricular septal defect we always tried to achieve biventricular circulation to accomplish arch repair and close ventricular septal defect. All operations were performed via midline sternotomy.

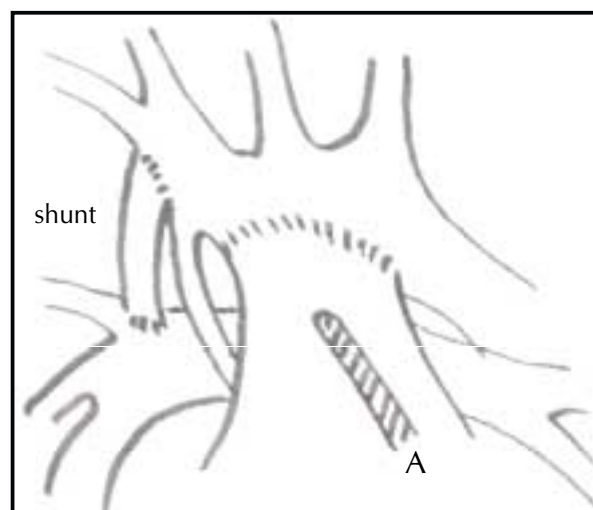
In the first-stage operation for hypoplastic left heart syndrome, a 3.5 mm polytetrafluoroethylene tube was sutured onto the innominate artery before the extracorporeal circulation began. The arterial perfusion cannula of 2.5-mm was then inserted into the tube. Extracorporeal circulation was started with a perfusate of a hematocrit of 0.25 ± 0.44 (mean ± SD). After the arterial duct was divided, the pulmonary bifurcation was detached from the pulmonary trunk and patched with autologous pericardium (Fig. 1), accomplishing the atrial septectomy. Pulmonary-trunk-to-aortic-arch anastomosis was performed with clamps to proximal arch and descending aorta and tourniquets to the arch vessels. Throughout the course of the operation, great care was taken to avoid obstruction or kinking of the small ascending aorta to preserve coronary perfusion and keep the heart beating. As a final step of the operation, the distal end of the systemopulmonary shunt was sutured onto the right pulmonary artery while the patient was perfused via the pulmonary trunk (neo-aorta) (Fig. 2).

In patients with interrupted aortic arch, the arterial cannula was advanced into the innominate artery. Extracorporeal circulation commenced after the arterial duct had been ligated and divided. Arch repair was carried out with clamps applied to descending aorta and tourniquets to arch vessels. To facilitate surgical exposure, the heart was stopped with cold crystalloid cardioplegia in 6 patients. Subaortic stenosis was approached transtricuspidally and through the right ventricle. Ventricular septal defects in all patients were closed with polytetrafluoroethylene patch and running polypropylene suture through the tricuspid valve.

Both right radial and femoral artery pressures were continuously monitored intraoperatively by intra-arterial cannulae of the same gauge, inserted percutaneously. Perfusion flows were built up over a period of 5-10 min to the full flow of 2.2 L/m<sup>2</sup>/min (range: 354-480 mL/min according to the range of body surface area of 0.16-0.22 m<sup>2</sup>), with strict attention to the upper body (right radial artery) pressures not to exceed normal values. No vasodilator medication was used during this phase of the operation. All procedures were carried out at moderate hypothermia (>28°C), preferably with the heart beating (in patients with hypoplastic left heart syndrome). Usual methods of intraoperative monitoring, such as arterial and central venous pressure lines, urinary catheter, and temperature probes, were applied. Superior and inferior caval serum lactate measurements taken prebypass,



**Figure 1.** In hypoplastic left heart syndrome (HLHS), the arch repair is carried out with clamps and tourniquets, whereas systemic perfusion (A) is maintained through the innominate artery.



**Figure 2.** Completed arch repair. Distal end of the systemopulmonary shunt was sutured onto the right pulmonary artery, whereas systemic perfusion (A) was maintained through the pulmonary trunk (neo-aorta).

on modified perfusion, postbypass and postoperatively were available for two patients. All patients received methylprednisolone (10 mg/kg IV) intraoperatively and mannitol (0.25 g/kg IV every 6 h) on the day of operation and first postoperative day, to avoid cerebral edema. Serial head ultrasounds were performed to assess cerebral edema preoperatively, on arrival to postoperative intensive care unit, and 24 h after operation.

## Results

There was no intraoperative mortality. Two neonates with the hypoplastic left heart syndrome were lost due to hypoxia, intractable metabolic acidosis, and low cardiac output on the third and seventh postoperative days, respectively. All patients with interrupted aortic arch repair survived. No morbidity or mortality attributable to continuous perfusion occurred.

The mean duration ( $\pm$ SD) of extracorporeal circulation was  $114\pm 26$  min (Table 1). Two patients required additional periods of 25 min of reperfusion to achieve hemodynamic stability. There was no cross-clamping of the ascending aorta in any of the patients undergoing first-stage palliation of hypoplastic left heart syndrome. The mean duration of arch repair was  $38\pm 18.5$  min. Maximum perfusion rate (actual/required flow for body surface area) that could be delivered within normal perfusion pressures was 1.65. This equaled a flow of  $3.52$  L/m<sup>2</sup>/min, or 225 mL/kg/min. In patient No. 7 with type-B interrupted aortic arch, ventricular septal defect, and anomalous origin of the right subclavian artery from the descending aorta, the perfusion started with the right subclavian artery left patent. However, during arch repair it became necessary to use the right subclavian artery as a posterior wall of a composite conduit to bridge the gap between the ascending and descending aorta. The anomalous right subclavian artery was therefore divided without significant change in the lower body perfusion pressures.

The right radial to femoral artery pressure gradient became more pronounced towards higher perfusion flows (Table 2). The lowest nasopharyngeal/rectal temperature was 28.5°C. There was no difference between nasopharyngeal and rectal temperatures. Urine output (mean $\pm$ SD) dropped from  $1.8\pm 0.7$  mL/kg/h prebypass to  $1.1\pm 0.3$  mL/kg/h during modified perfusion to  $2.7\pm 1.3$  mL/kg/h after the repair phase of the operation. We did not observe any intraoperative adverse effects, such as metabolic acidosis, drop in venous saturation of the inferior vena cava return, hypoglycemia or hyperglycemia. Serial serum lactate levels were only available for the last two patients in the series. A gradual increase in serum lactate was observed during arch repair, with a peak on the release

of the cross-clamps on the descending aorta. There was no postoperative bleeding in any of the patients. Urine output remained adequate in the postoperative period in all but 2 patients with low cardiac output.

Serial cranial ultrasonography did not reveal any significant change in early postoperative period and first day after operation as compared to the preoperative findings. No neurological complications were encountered.

The follow-up of the survivors ranged from 10 to 17 months. They exhibited normal psychosomatic development as assessed by their pediatrician. Two neonates with DiGeorge syndrome were below the normal percentiles for their age. There was no fatal outcome or need for reintervention in patients with interrupted aortic arch repair. Four neonates who survived the first-stage palliation of hypoplastic left heart syndrome have been scheduled for the second stage (cavopulmonary anastomosis).

## Discussion

Alarming high incidence of serious neurologic complications occurring after deep hypothermic total circulatory arrest have daunted its clinical use and forced surgeons to find alternatives of continuous perfusion during aortic arch repairs (1,9). Several methods have been introduced to avoid deep hypothermic total circulatory arrest and all its sequelae (2-8). In the technique we adopted from the original description by Asou et al (2), the arterial cannula is well away from the operating field, thus not interfering with surgical manipulation. The introduction of continuous perfusion during arch repair has changed the shape of a once "clamp-and-run" operation to one where de- liberation and meticulous tayloring may be afforded. For a team who masters a new type of operation, such as first-stage palliation of hypoplastic left heart syndrome, the benefits of avoiding complications from time constraints are of paramount importance. With careful application of aortic clamps, the first stage palliation of hypoplastic left heart syndrome is performed with the heart beating. Therefore, the surgeon may be at all times well aware that the diminutive ascending aorta is in no danger of kinking or obstruction. All this should pay off in better hemodynamics, less bleeding, and smoother postoperative course.

Adequate lower body perfusion is achieved via collaterals (5). Our experience confirms the observations by others that it is necessary to place a clamp on the descending aorta to avoid flooding the operative field from backflow (7). Gray's Anatomy enlists 12 alternative pathways of upper-to-lower body collaterals at the neck, shoulder, and arm region (10). These pathways are suspected to be very variable both anatomically and in respect to their capacity (4). One of our patients (No. 7) with an interrupted aortic arch and anomalous right subclavian artery from the descending aorta offers a good example for the pliability of the collateral system. No difference between right radial and femoral artery pressure gradients was observed regardless of the anomalous artery itself being patent or clamped. This may also highlight the importance of allowing time for the collaterals to adapt to

**Table 2.** Right radial and femoral artery pressures and perfusion flow in 9 neonates with hypoplastic left heart syndrome and interrupted aortic arch during aortic arch repair and continuous perfusion via collaterals

Site	Mean $\pm$ SD perfusion flows (L/m <sup>2</sup> /min) at mm Hg of pressure		
	0.55	1.1	2.2
Right radial artery	16.7 $\pm$ 4.8	33.0 $\pm$ 7.1	56.1 $\pm$ 6.7
Femoral artery	6.4 $\pm$ 2.8	21.1 $\pm$ 3.4	34.2 $\pm$ 8.2
$\Delta$ radial-to-femoral pressure	10.3 $\pm$ 3.9	11.9 $\pm$ 4.4	21.9 $\pm$ 5.6

the actual flow pattern. Perfusion flows should be built up very gently and gradually, ie, over a period of 5-10 min.

A major difference between our and other continuous perfusion techniques is that we maintained nasopharyngeal temperatures above 28°C. As the heart remains beating during arch repair, we believe that myocardial performance may be better preserved at that temperature than at deep hypothermia. At temperatures below 28°C, cerebral autoregulation is lost and cerebral blood flow becomes dependent on the mean arterial pressure. Thus, the brain is at risk of extra perfusion (11). At moderate hypothermia, cerebral autoregulation is preserved (12) and cerebral blood flow remains independent from mean arterial pressure (13,14). Our experience shows that, by keeping the temperature above 28°C, a more harmonious flow distribution may be achieved and thus the brain may be protected from extra perfusion. Based upon the evidence of serial cranial ultrasonography performed in our patients, we saw that cerebral edema could be avoided. Although urine output decreased during arch repair, renal function remained intact, suggesting adequate lower body perfusion. Authors advocating continuous perfusion during arch repair reported that their patients had been cooled down to 18°C, which provided reduced flow at 0.5-1.0 L/m<sup>2</sup>/min (4,7). At higher temperatures (>28°C), higher perfusion rates are needed. However, the upper-to-lower body pressure gradient becomes pronounced only at more than normal perfusion rates (≥2.2 L/m<sup>2</sup>/min). Although demand-supply is lower at low temperatures, their coupling may be better at higher temperatures when autoregulation of the microcirculation as well as that of the collateral pathways is better preserved (15). We propose a slow and gradual build-up in perfusion rates and applying clamps to allow possible alternative pathways to maintain preferential flow. These time-related changes in flow pattern need to be further studied and may be compared with the changes in extensive coarctation repair, when abdominal organ perfusion becomes limited quite abruptly by placing clamps on the arch and its vessels at relatively high temperature. We present our first experience with this technique with the obvious limitations of the study because of a small number of patients, limited number of parameters investigated, and short follow-up.

In conclusion, the technique of continuous systemic perfusion via collaterals during extensive aortic arch repairs is still in evolution with regard to the temperature, maximal flow, safe period of perfusion, hematocrit, and other factors. Further research is needed to ascertain the relative merits of preservation of cerebral autoregulation versus hypothermia for cerebral protection. Early results are good but longer follow-up is needed.

## References

- 1 Glauser TA, Rorke LB, Weinberg PM. Acquired neuropathologic lesions associated with the hypoplastic left heart syndrome. *Pediatrics* 1990;85:991-1000.
- 2 Asou T, Kado H, Imoto Y, Shiokawa Y, Tominaga R, Kawachi Y, et al. Selective cerebral perfusion technique during aortic arch repair in neonates. *Ann Thorac Surg* 1996;61:1546-8.
- 3 Ishino K, Kawada M, Irie H, Kino K, Sano S. Single stage repair of aortic coarctation with ventricular septal defect using isolated cerebral and myocardial perfusion. *Eur J Cardiothorac Surg* 2000;17:538-42.
- 4 Pigula FA, Nemoto EM, Griffith BP, Siewers RD. Regional low-flow perfusion provides cerebral circulatory support during neonatal aortic arch reconstruction. *J Thorac Cardiovasc Surg* 2000;119:331-9.
- 5 Pigula FA, Gandhi SK, Siewers RD, Davis PJ, Webber SA, Nemoto EM. Regional low-flow perfusion provides somatic circulatory support during neonatal aortic arch surgery. *Ann Thorac Surg* 2001;72:401-7.
- 6 Imoto Y, Kado H, Shiokawa Y, Minami K, Yasui H. Experience with the Norwood procedure without circulatory arrest. *J Thorac Cardiovasc Surg* 2001;122:879-82.
- 7 Tchervenkov CI, Korkola SJ, Shum-Tim D. Surgical technique to avoid circulatory arrest and direct arch vessel cannulation during neonatal aortic arch reconstruction. *Eur J Cardiothorac Surg* 2001;19:708-10.
- 8 Tchervenkov CI, Korkola SJ, Shum-Tim D, Calaritis C, Laliberte E, Reyes TU, et al. Neonatal aortic arch reconstruction avoiding circulatory arrest and direct arch vessel cannulation. *Ann Thorac Surg* 2001;72:1615-20.
- 9 van der Linden J, Astudillo R, Ekroth R, Scallan M, Lincoln C. Cerebral lactate release after circulatory arrest but not after low flow in pediatric heart operations. *Ann Thorac Surg* 1993;56:1485-9.
- 10 Gray H. *Gray's anatomy descriptive and surgical*. London: Parragon; 1993.
- 11 Kern FH, Hickey PR. The effects of cardiopulmonary bypass on the brain. In: Jonas RA, Elliott MJ, editors. *Cardiopulmonary bypass in neonates, infants and young children*. Oxford: Butterworth Heinemann; 1994. p. 263-85.
- 12 Greeley WJ, Kern FH, Meliones JN, Ungerleider RM. Effect of deep hypothermia and circulatory arrest on cerebral blood flow and metabolism. *Ann Thorac Surg* 1993;56:1464-6.
- 13 Sakurada T, Kazui T, Tanaka H, Komatsu S. Comparative experimental study of cerebral protection during aortic arch reconstruction. *Ann Thorac Surg* 1996;61:1348-54.
- 14 Higami T, Kozawa S, Asada T, Obo H, Gan K, Iwashita K, et al. Retrograde cerebral perfusion versus selective cerebral perfusion as evaluated by cerebral oxygen saturation during aortic arch reconstruction. *Ann Thorac Surg* 1999;67:1091-6.
- 15 Svensson LG. Brain protection. *J Card Surg* 1997;12(2 Suppl):326-30.

Received: May 16, 2002

Accepted: August 26, 2002

## Correspondence to:

Laszlo Kiraly

Hungarian Institute of Cardiology

Pediatric Cardiac Centre

Szent Laszlo Ter 22

1102 Budapest, Hungary

[kiraly@kardio.hu](mailto:kiraly@kardio.hu)