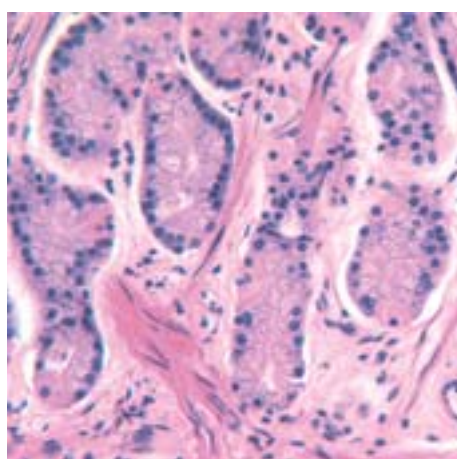
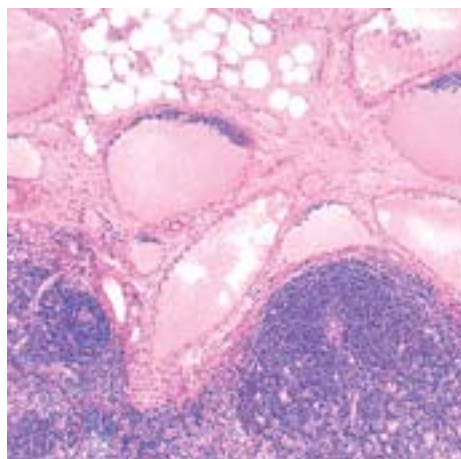
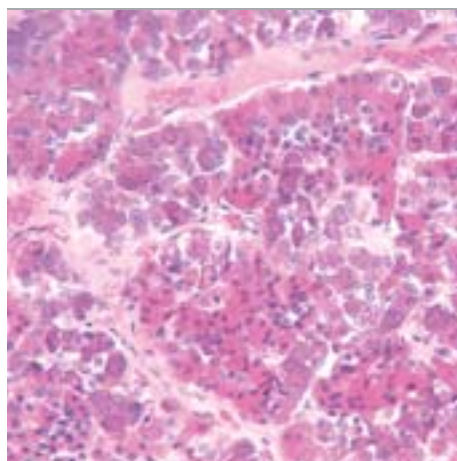
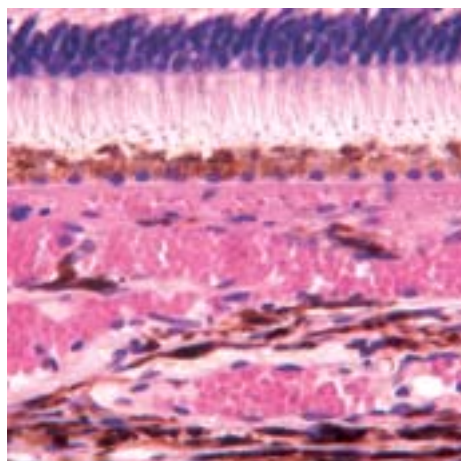


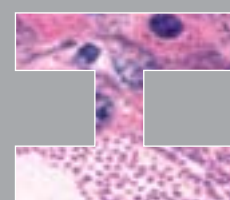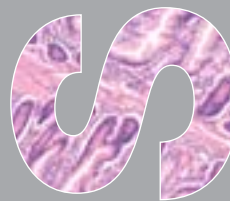
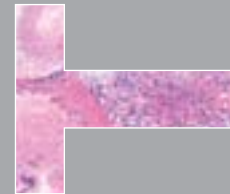
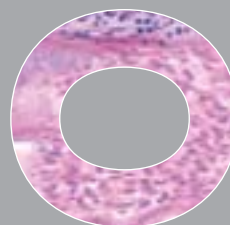
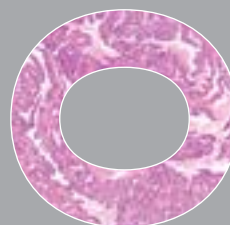
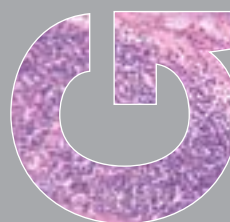
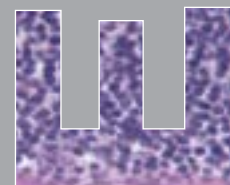
Želimir Bradamante
Anton Švajger



**Slike
histoloških
preparata**

II dio

Vježbe iz



Prof. dr. sc. Želimir Bradamante
Prof. dr. sc. Anton Švajger

Zavod za histologiju i embriologiju
Medicinski fakultet Sveučilišta u Zagrebu

Vježbe iz histologije

Slike histoloških preparata

II. dio

Zagreb, 2002.



PREDGOVOR

Pred vama je i drugi dio zbirke slika histoloških preparata koje naši studenti mikroskopiraju na vježbama iz predmeta Histologija i embriologija. Tako je slikovnim prikazom zaokruženo cijelo gradivo praktičnog dijela nastave ovoga predmeta, koje je ujedno i ispitno gradivo.

Da bi ovaj drugi dio atlasa mogao doći u ruke studenata već na početku ljetnoga semestra akademske godine 2001./2002. bio je potreban užurban, katkada i iscrpljujući rad. Nije bilo vremena za minuciozno dotjerivanje svih detalja. Zato se nisu mogle izbjeći poneke neujednačenosti u veličini slika pa i u kakvoći predložaka (preparata). Bio je to svjesni rizik i žrtva nastojanju da se postigne važnija svrha - da studenti dobiju atlas u pravo vrijeme, kao pomoć u savladavanju gradiva i pripremanju ispita. Kada se postigne ta prva svrha, bit će dovoljno vremena za reviziju obih dijelova atlasa, izmjene, dopune i poboljšanja te pripreme za izdavanje cijeloga sadržaja u jednom svesku. Takav raspored rada bila nam je i prvotna nakana.

Pri uporabi ove zbirke mikrofotografija valja imati na umu da su one snimljene na reprezentativnim uzorcima, tj. na preparatima na kojima se pojedini detalji najbolje vide. To znači da se svaki od njih možda neće naći na svim preparatima (tj. na svim tankim presjecima kroz tkivo!), ili se na svim preparatima neće jednako dobro vidjeti. Međutim, nastojali smo uvrstiti sve bitne pojedinosti koje se na preparatima mogu vidjeti. Pa kad ih nađete - znat ćete o čemu se radi. Treba misliti i na to da se preparati jednoga te istog organa međusobno razlikuju i po serijama, tj. po uzorcima uzetim od različitih pokojnika te histološkom tehnikom obrađenih u širokom vremenskom rasponu. Zato se ne može očekivati da budu jednaki niti po makroskopskom izgledu niti po svim pojedinostima mikroskopske slike. Česta studentska pogreška u prepoznavanju preparata (i razočaranje na ispitu!) temelji se na primjeni krivih kriterija ovakvoga tipa: "Na vježbama je sluznica jednaka bila ravna, a sada (na ispitu) je nabrana". Prepoznavanje preparata mora se uvijek temeljiti na zbroju kriterija bitnih za pojedino tkivo ili organ, uzimajući pri tome u obzir i razlike koje mogu nastati tijekom priređivanja preparata. To je tehnika mišljenja, zapažanja i prosudbe koja će vam dobro doći i u medicinskoj dijagnostici.

Želimo da vam oba dijela atlasa budu dobrodošla pomoć u savladavanju ispitnoga gradiva.

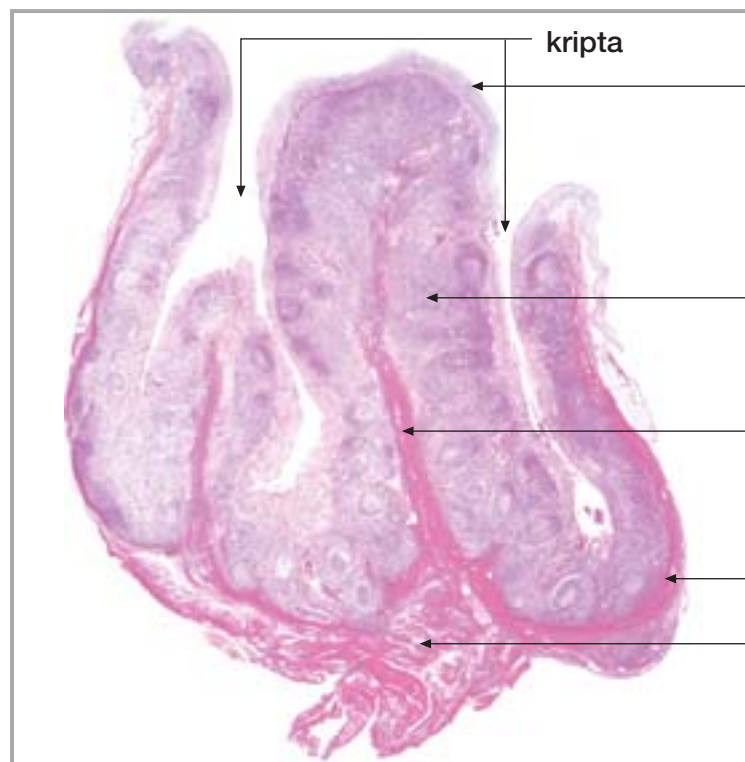
U Zagrebu, ožujka 2002.

Autori

S A D R Ž A J

- 17. NEPČANA TONZILA I ŽDRIJELO**
- 18. JEDNJAK**
- 19. ŽELUDAC**
- 20. TANKO CRIJEVO**
- 21. DEBELO CRIJEVO**
- 22. GUŠTERAČA S DVANAESNIKOM**
- 23. JETRA I ŽUČNI MJEHUR**
- 24. DUŠNIK I PLUĆA**
- 25. BUBREG, MOKRAĆOVOD I MOKRAĆNI MJEHUR**
- 26. TESTIS I EPIDIDYMIS**
- 27. SJEMENOVOD, SJEMENSKI MJEHURIĆI I PROSTATA**
- 28. PENIS**
- 29. JAJNIK I JAJOVOD**
- 30. MATERNICA I RODNICA**
- 31. ENDOKRINE ŽLIJEZDE**
- 32. LIMFNI ČVOR, SLEZENA I TIMUS**
- 33. OKO**
- 34. UHO**
- 35. VELIKI I MALI MOZAK, KRALJEŽNIČNA MOŽDINA**

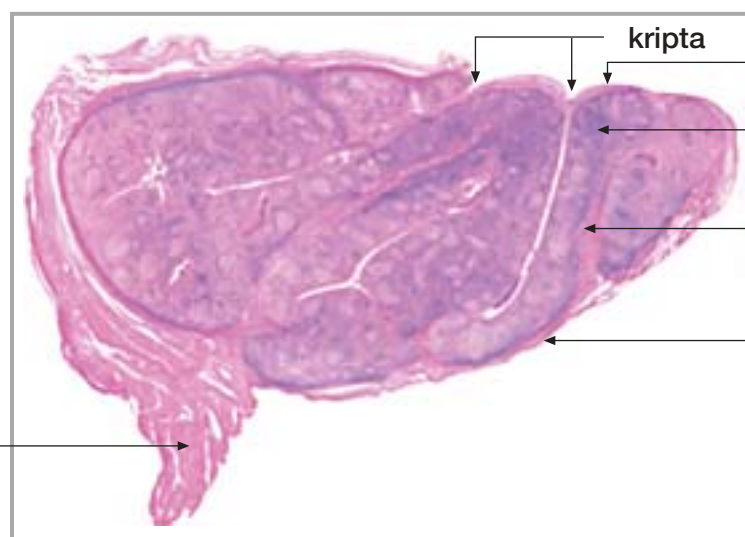
17. NEPČANA TONZILA I ŽDRIJELO



Sl. 142.

Tonsilla palatina

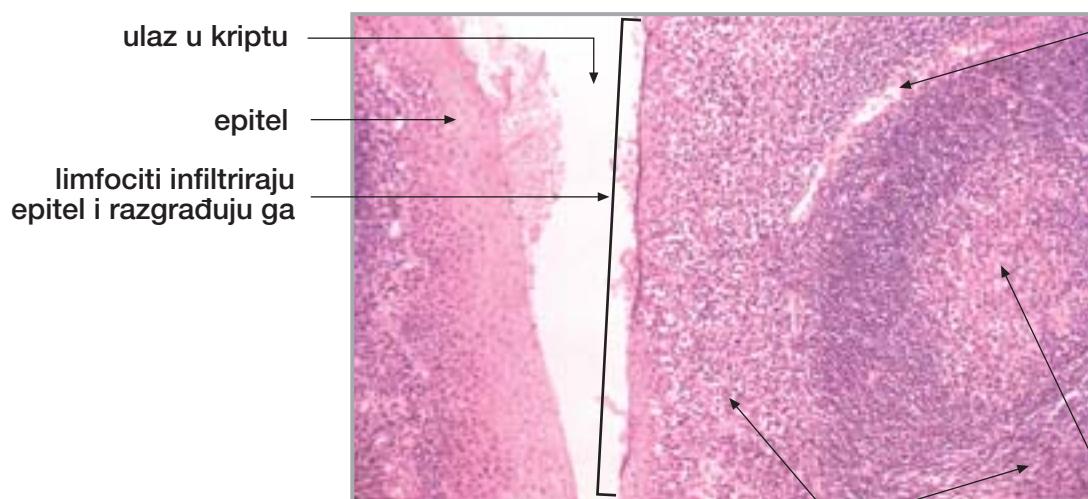
epitel
limfno tkivo
vezivna pregrada
vezivna čahura
mišićje ždrijela



Sl. 143.

Tonsilla palatina

kripta
epitel
limfno tkivo
vezivna pregrada
vezivna čahura
mišićje ždrijela



Sl. 144.

Tonsilla palatina

ulaz u kriptu
epitel
limfociti infiltriraju epitel i razgrađuju ga
krvna žila
limfni čvorić
zametno središte
difuzno limfno tkivo u lamini propriji

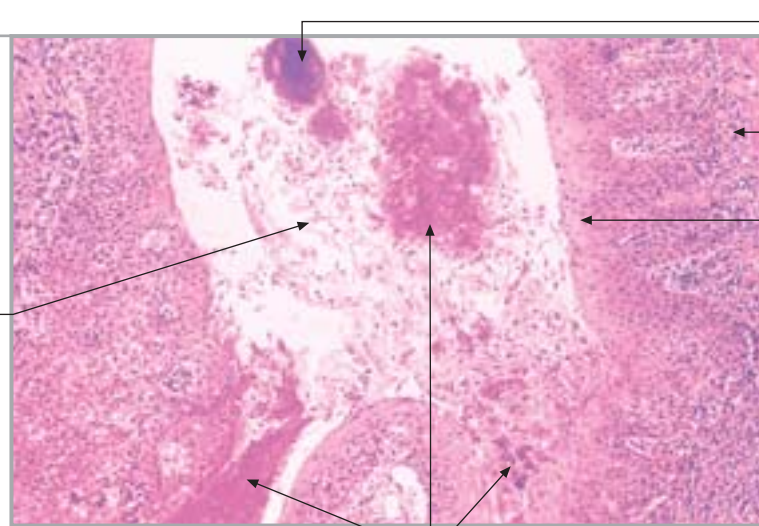
17. NEPČANA TONZILA I ŽDRIJELO

nastavak

Sl. 145.

Tonsilla palatina
(dno kripe)

odljuštene
(deskvamirane) stanice



ovapnjenje
zgnusnutog sadržaja

lamina proprija

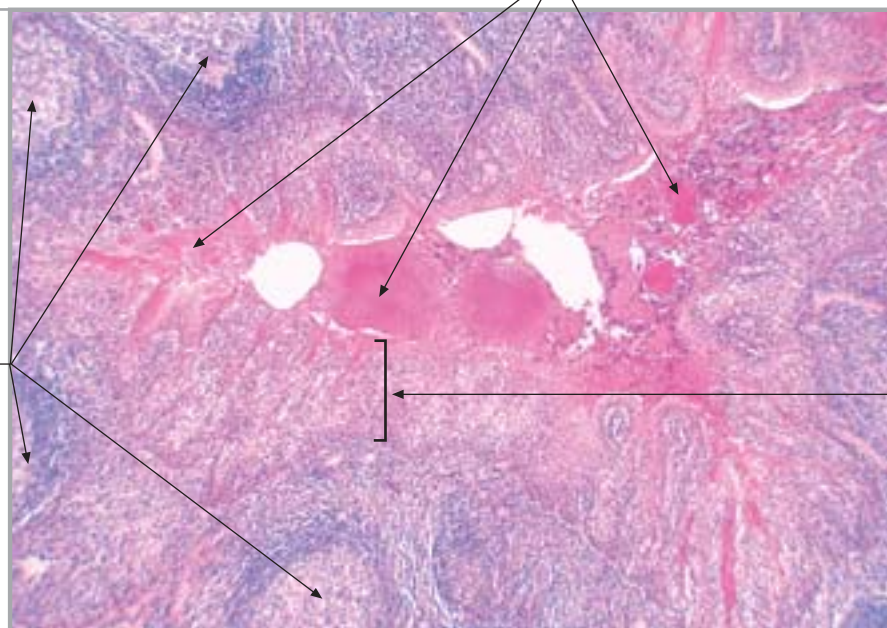
epitel

homogenizacija sadržaja

Sl. 146.

Tonsilla palatina
(dno kripe)

limfni čvorići



zgnusnuti sadržaj

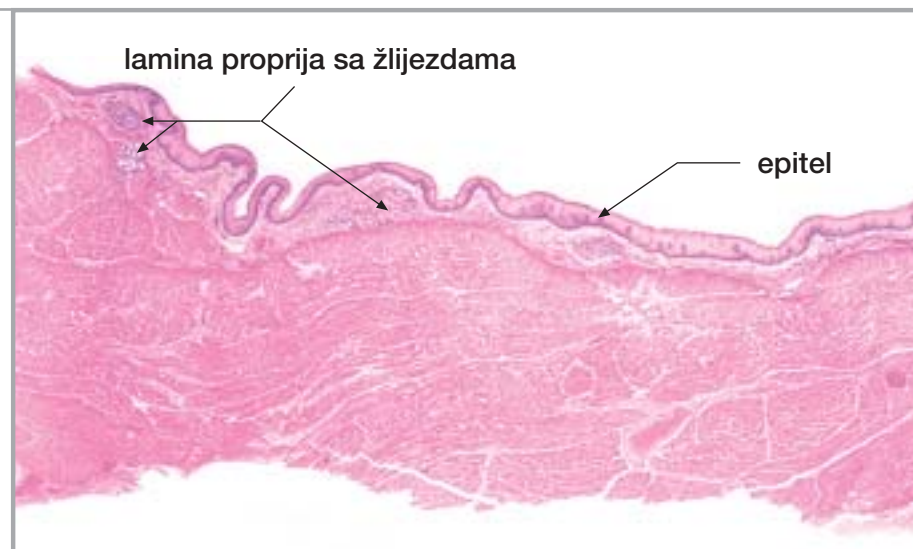
epitel infiltriran
limfocitima

Sl. 147.

Ždrijelo

lamina proprija sa žlijezdama

epitel



ždrijelno mišićje

17. NEPČANA TONZILA I ŽDRIJELO

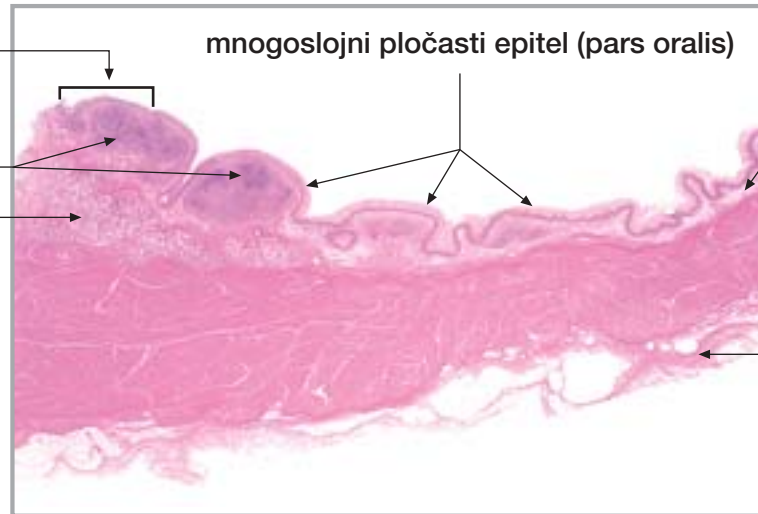
nastavak

višeredni cilindrični epitel s trepetljikama (pars nasalis)

limfno tkivo

žlijezde

mnogoslojni pločasti epitel (pars oralis)



lamina proprija

ždrijelno mišićje

adventicija

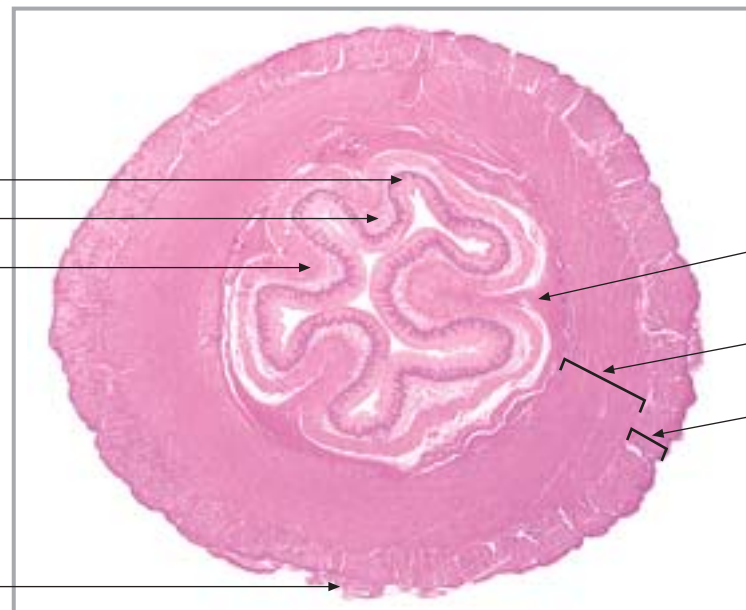
Sl. 148.

Ždrijelna tonzila

18. JEDNJAK

sluznica

epitel
lamina proprija
muskularis mukoze



adventicija

podsluznica

unutrašnji (kružni) mišićni sloj

vanjski (uzdužni) mišićni sloj

Sl. 149.

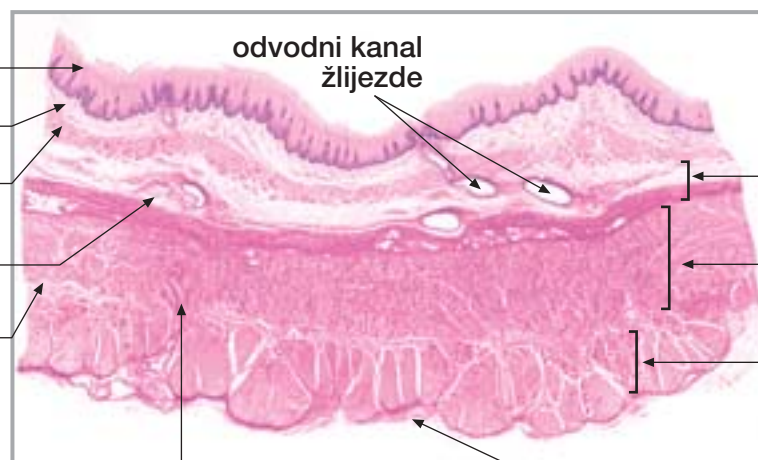
Jednjak (poprečni presjek)

sluznica

epitel
lamina proprija
muskularis mukoze

gl. esophagea

Auerbachov mienterički živčani splet



arterija prodire iz adventicije kroz mišićne slojeve prema podsluznici

adventicija

podsluznica

unutrašnji (kružni) mišićni sloj

vanjski (uzdužni) mišićni sloj

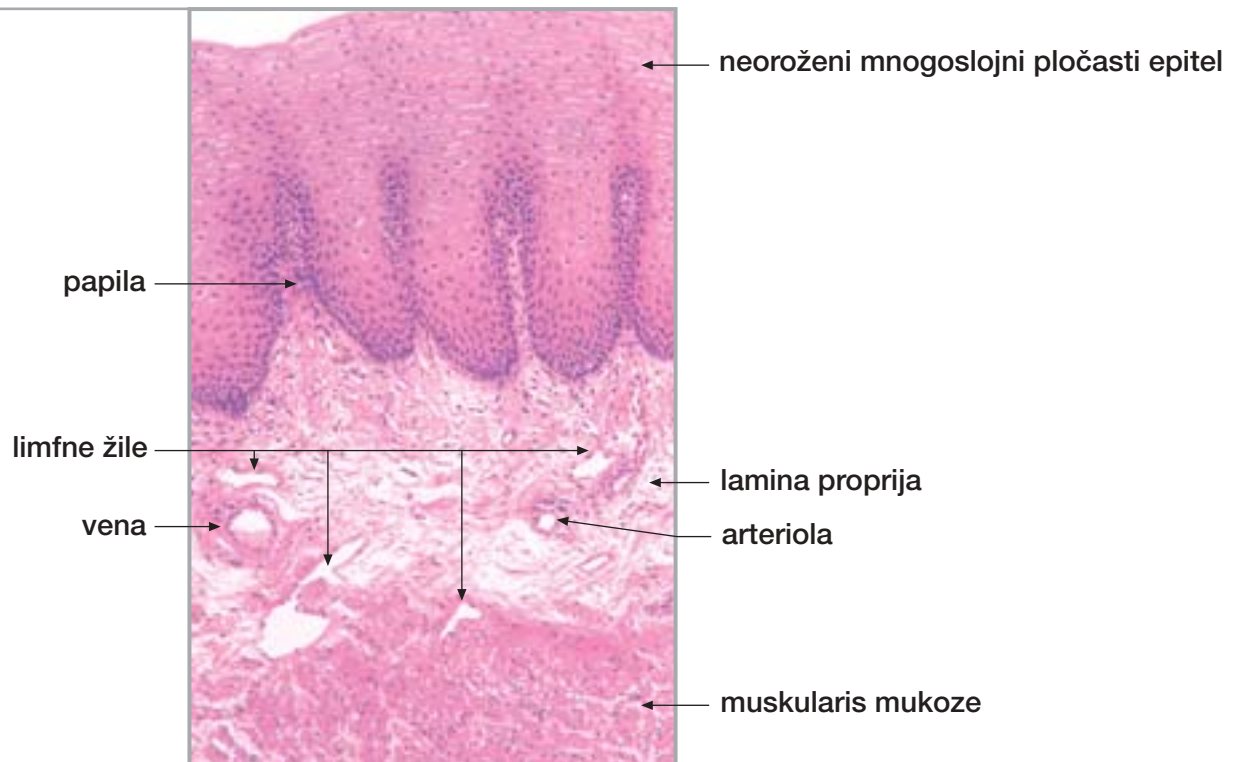
Sl. 150.

Jednjak (poprečni presjek)

tunica muscularis

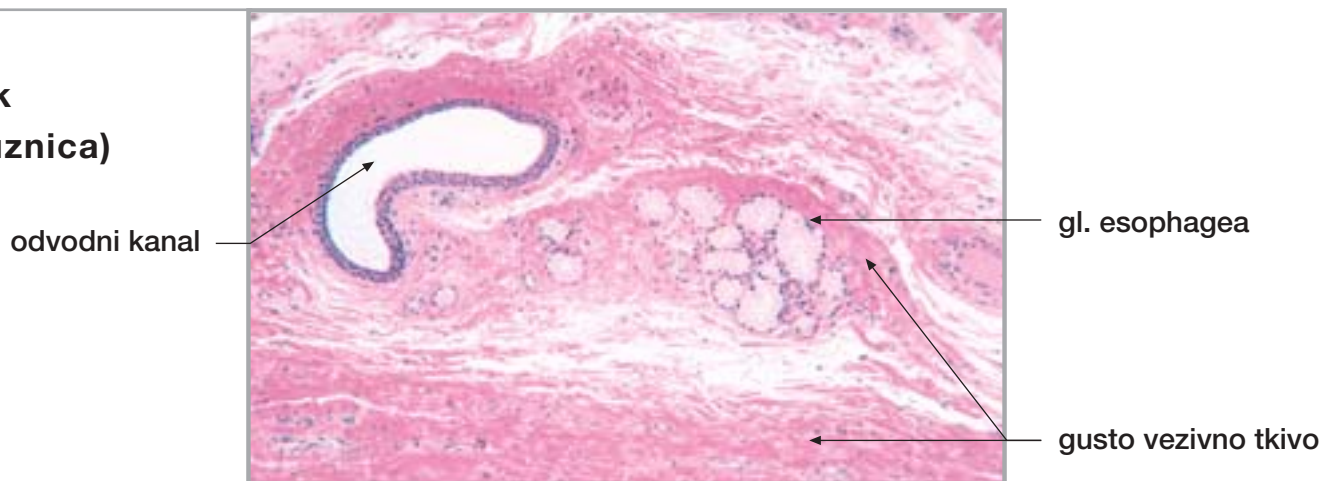
Sl. 151.

Jednjak (sluznica)



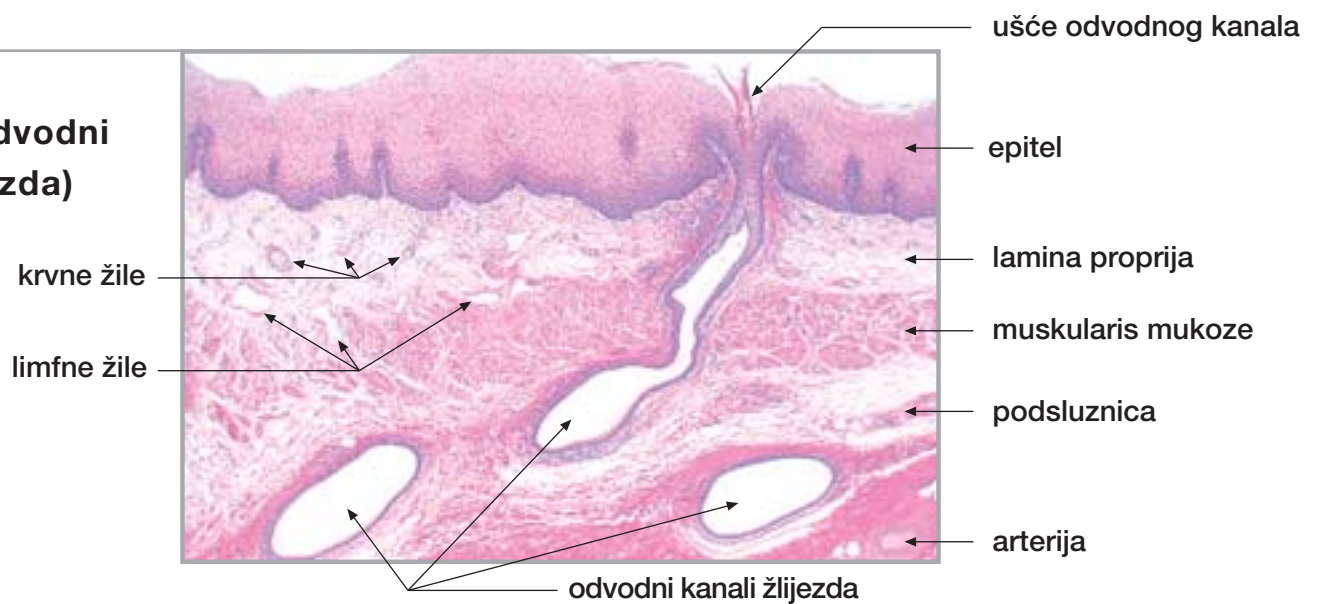
Sl. 152.

Jednjak (podsluznica)



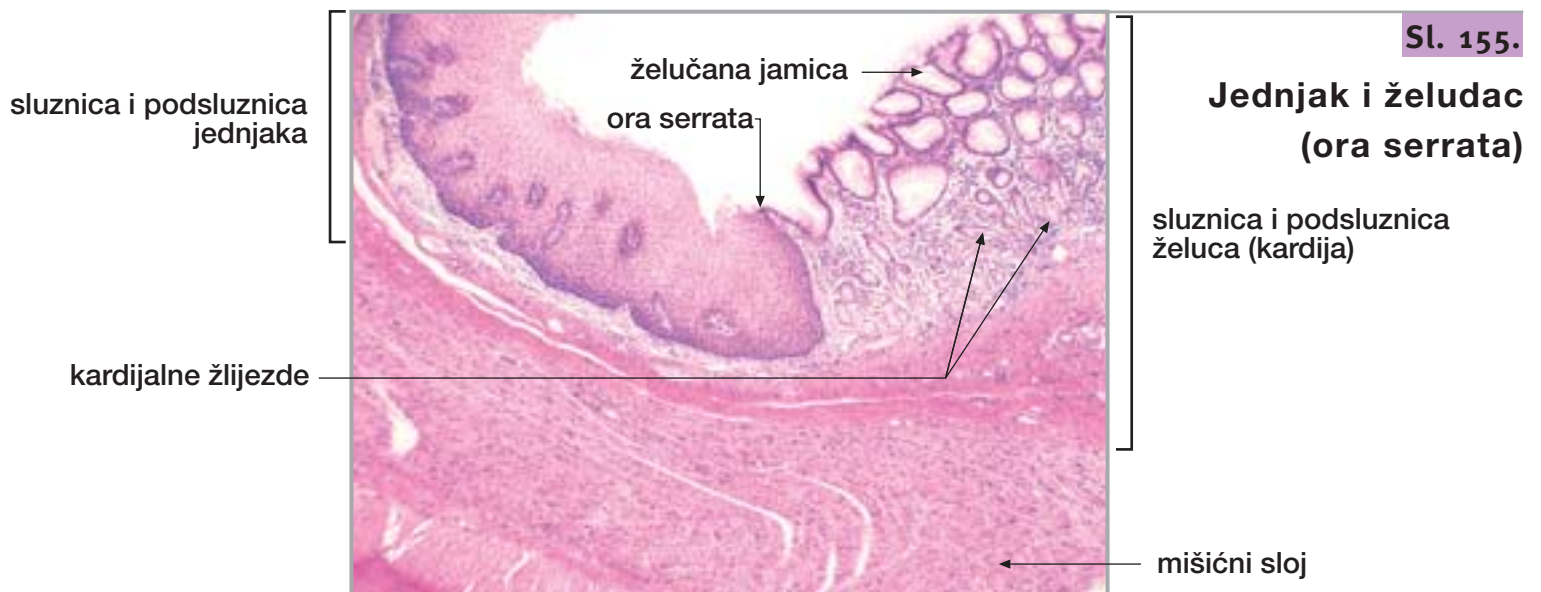
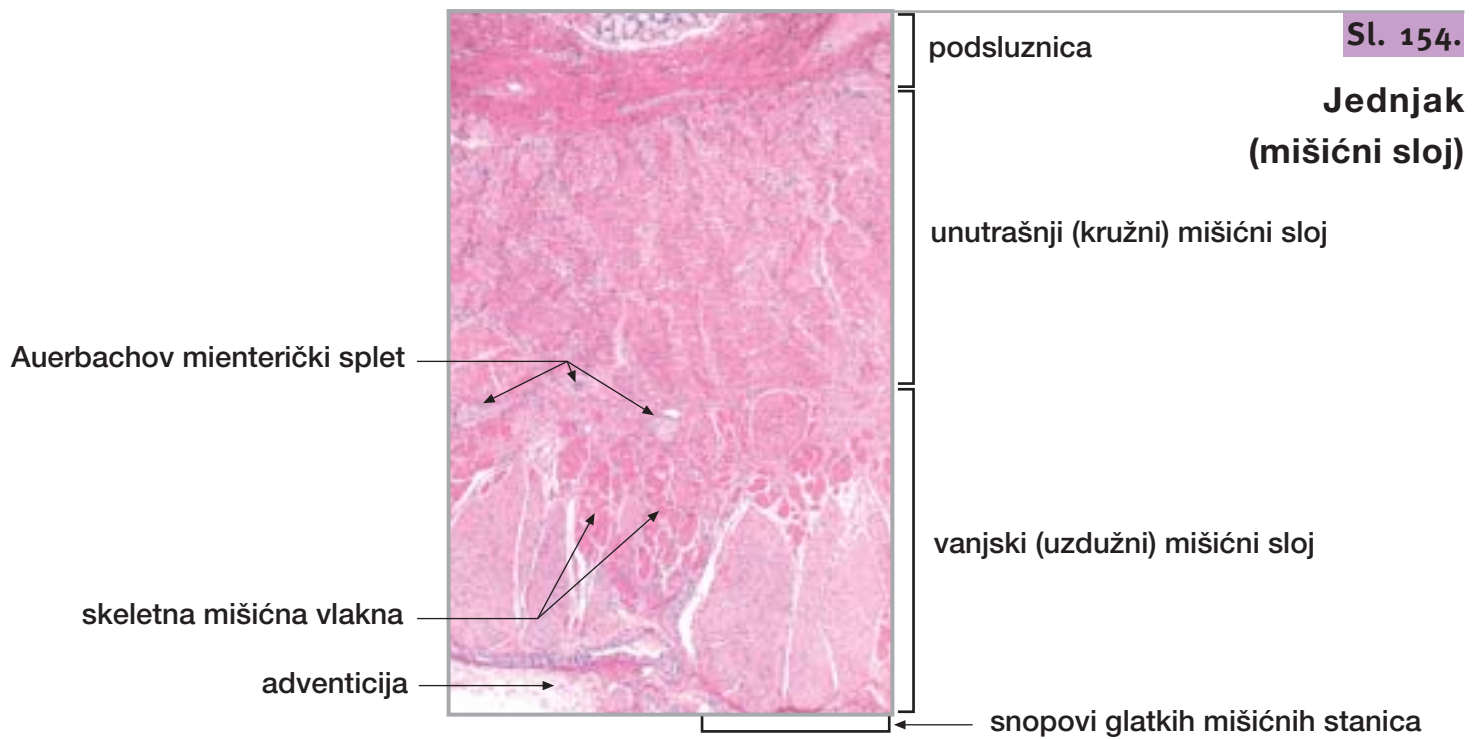
Sl. 153.

Jednjak (odvodni kanali žlijezda)

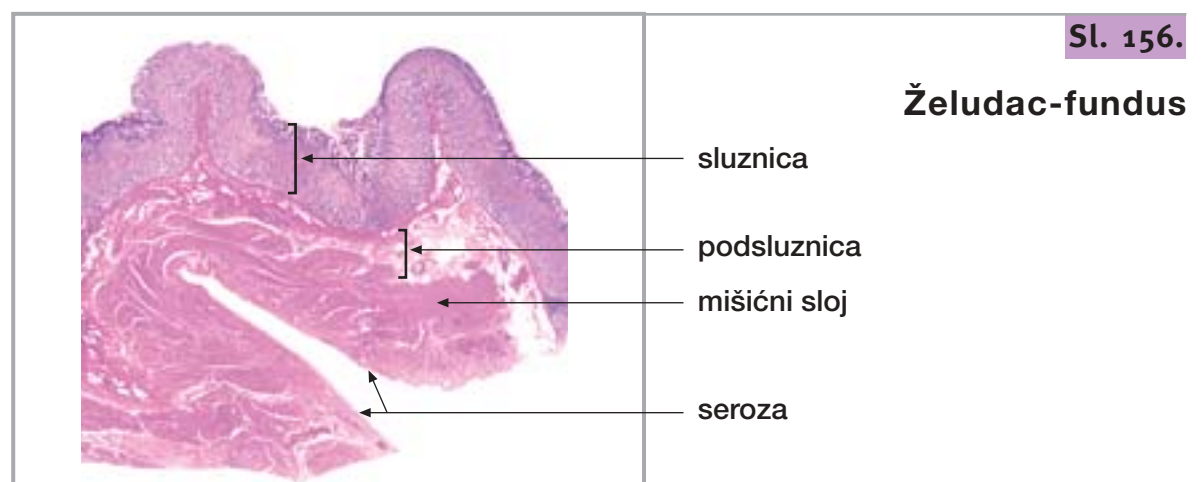


18. JEDNJAK

nastavak

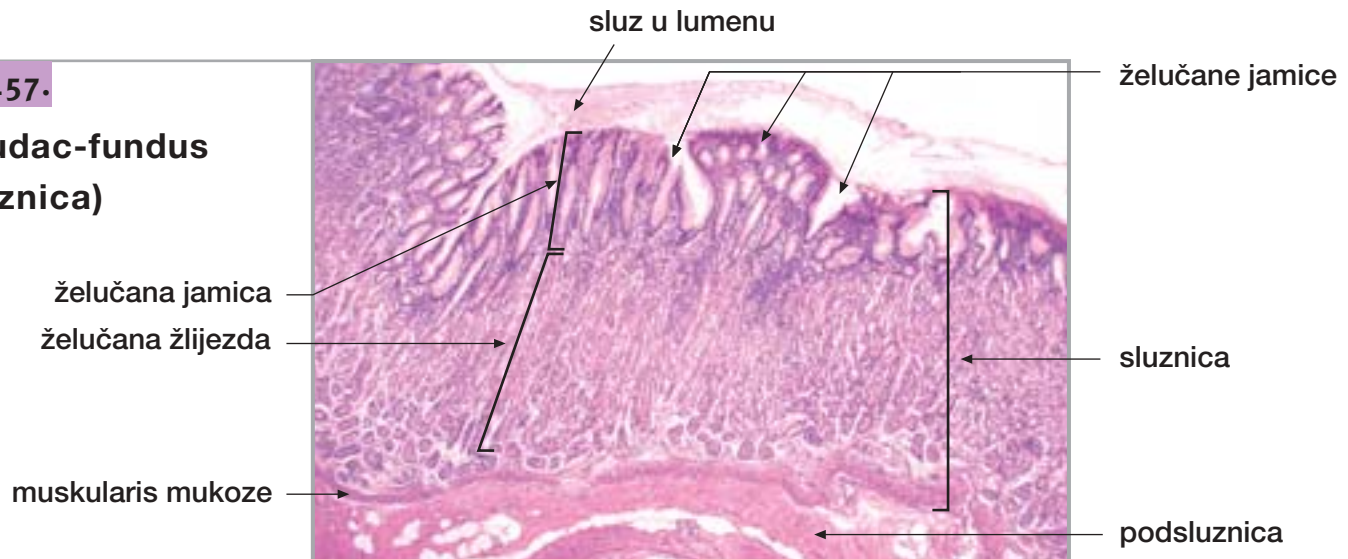

19. ŽELUDAC



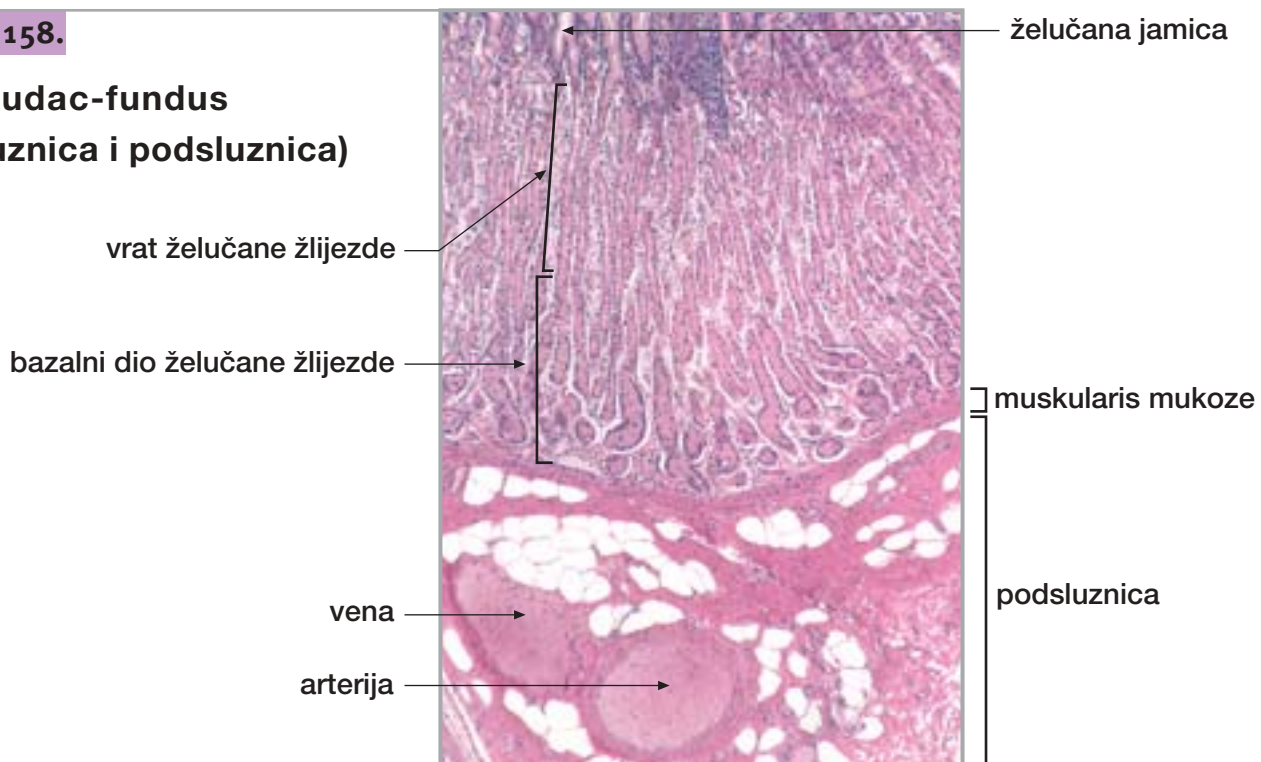Sl. 157.

Želudac-fundus (sluznica)



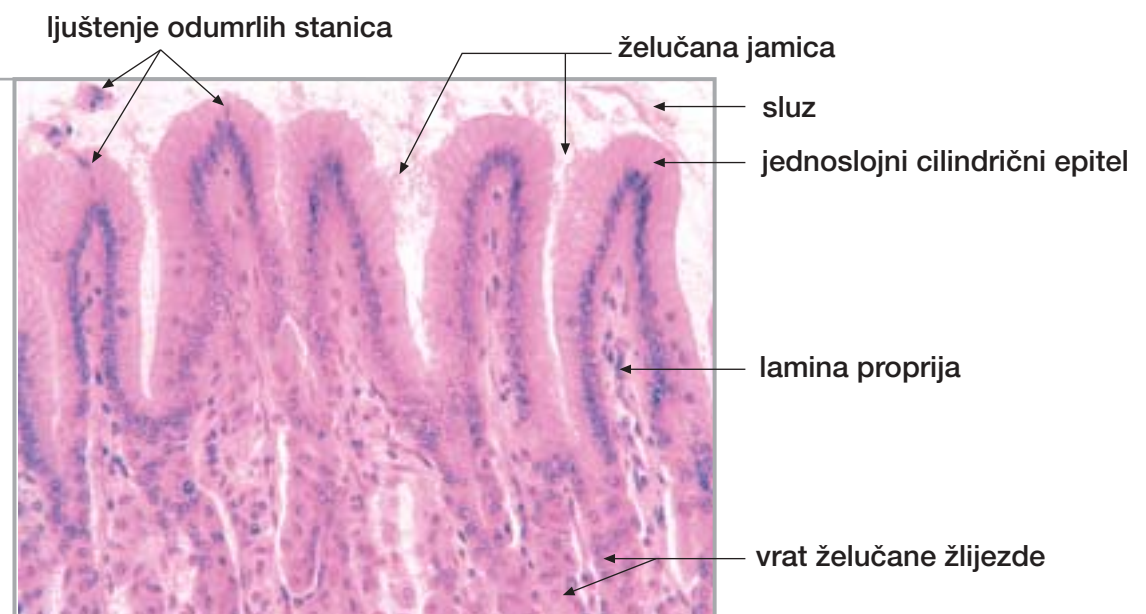
Sl. 158.

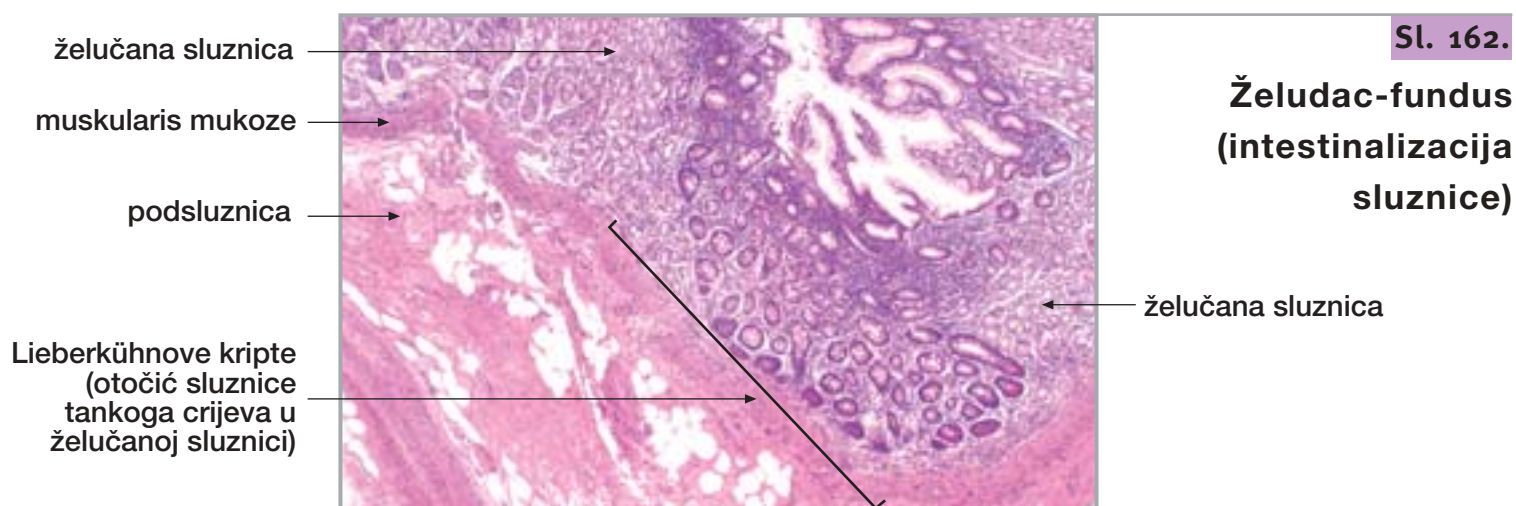
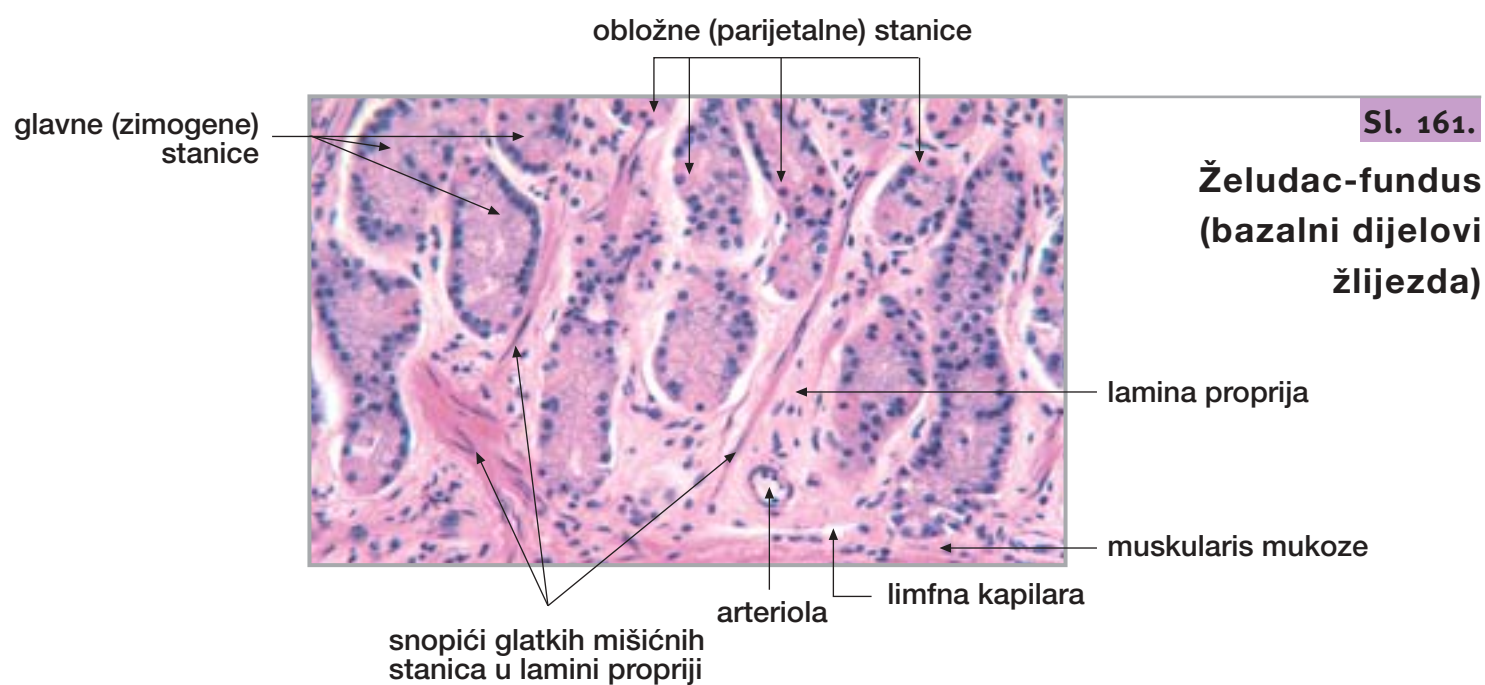
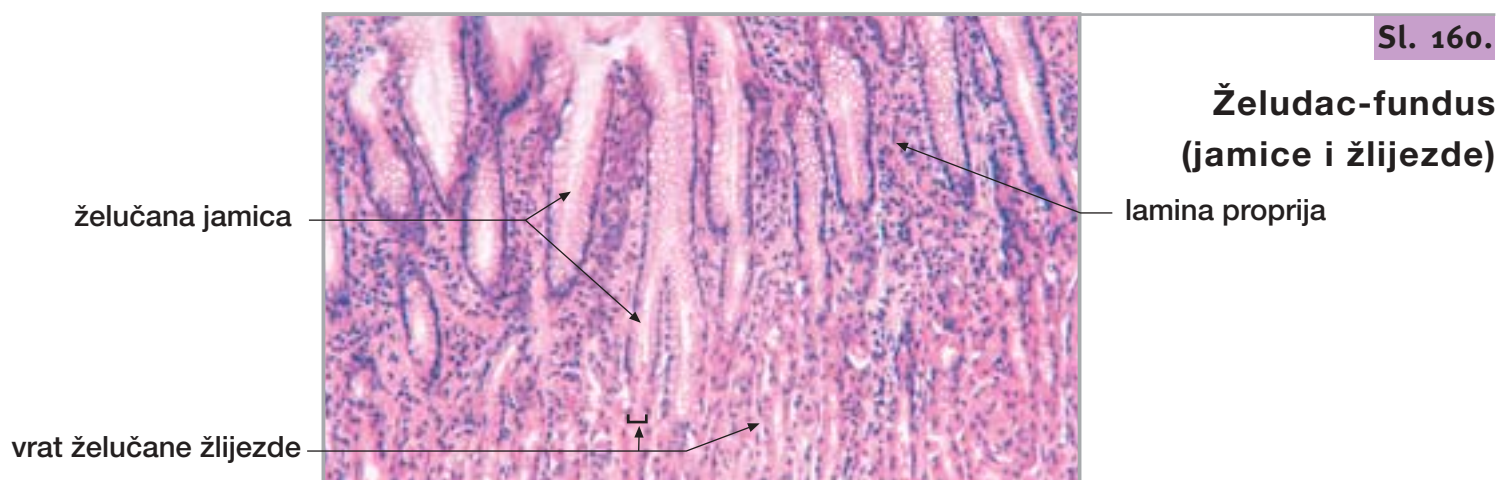
Želudac-fundus (sluznica i podsluznica)



Sl. 159.

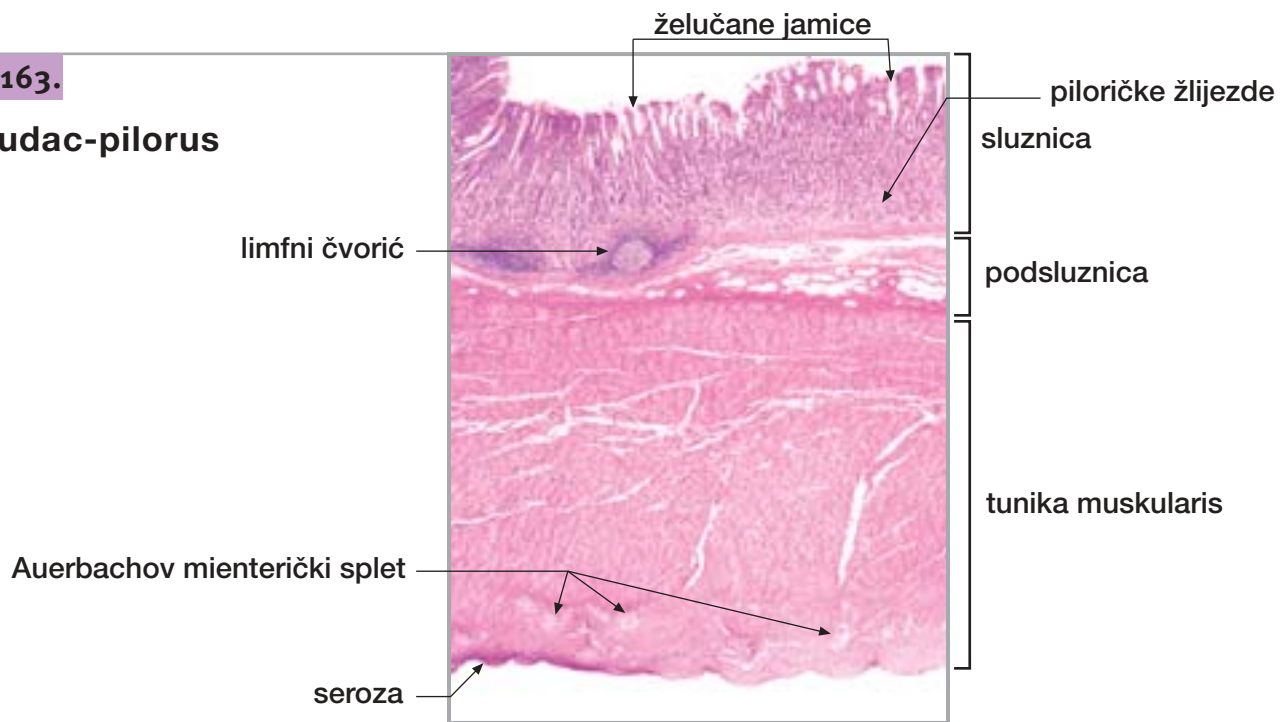
Želudac-fundus (želučane jamice)





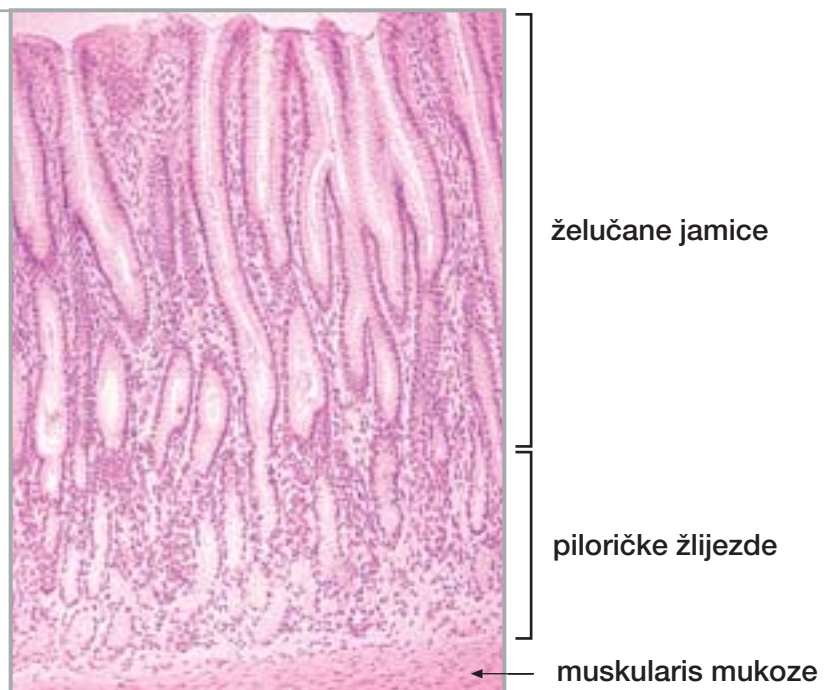Sl. 163.

Želudac-pilorus



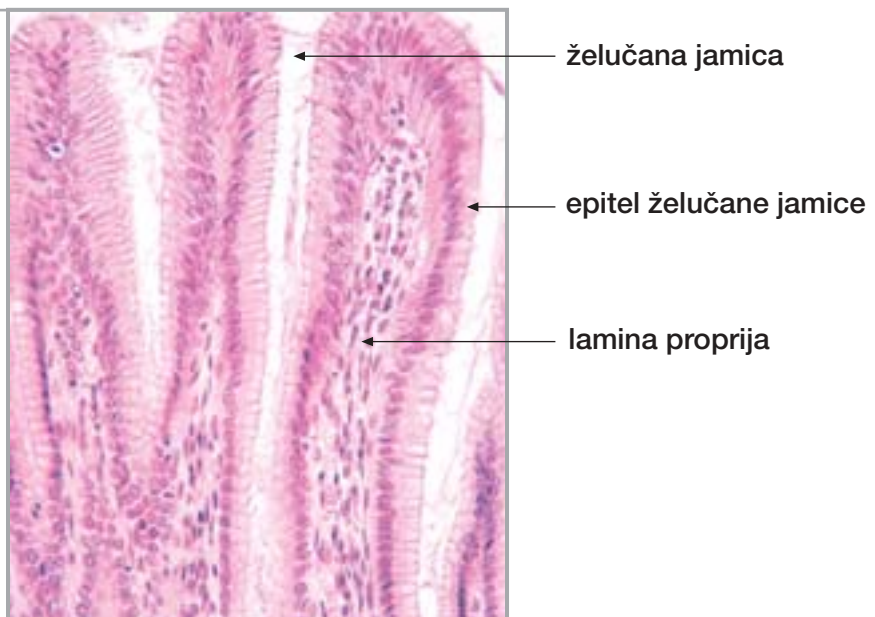
Sl. 164.

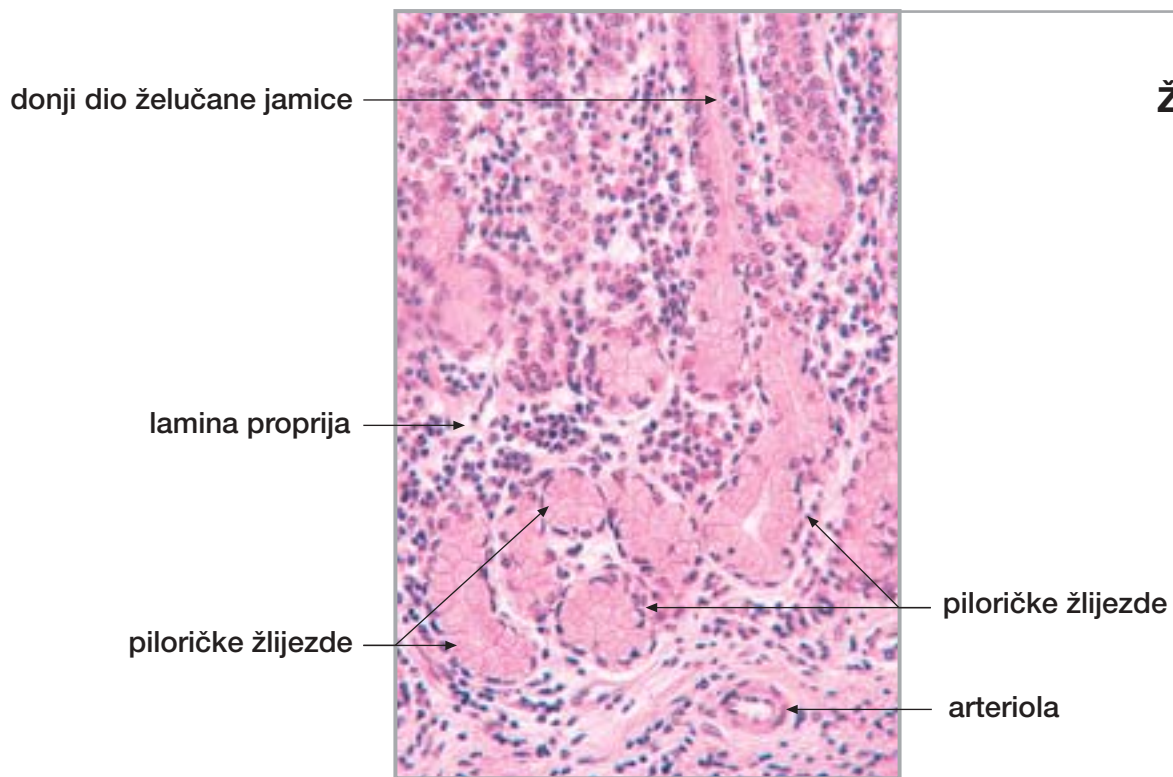
Želudac-pilorus (sluznica)



Sl. 165.

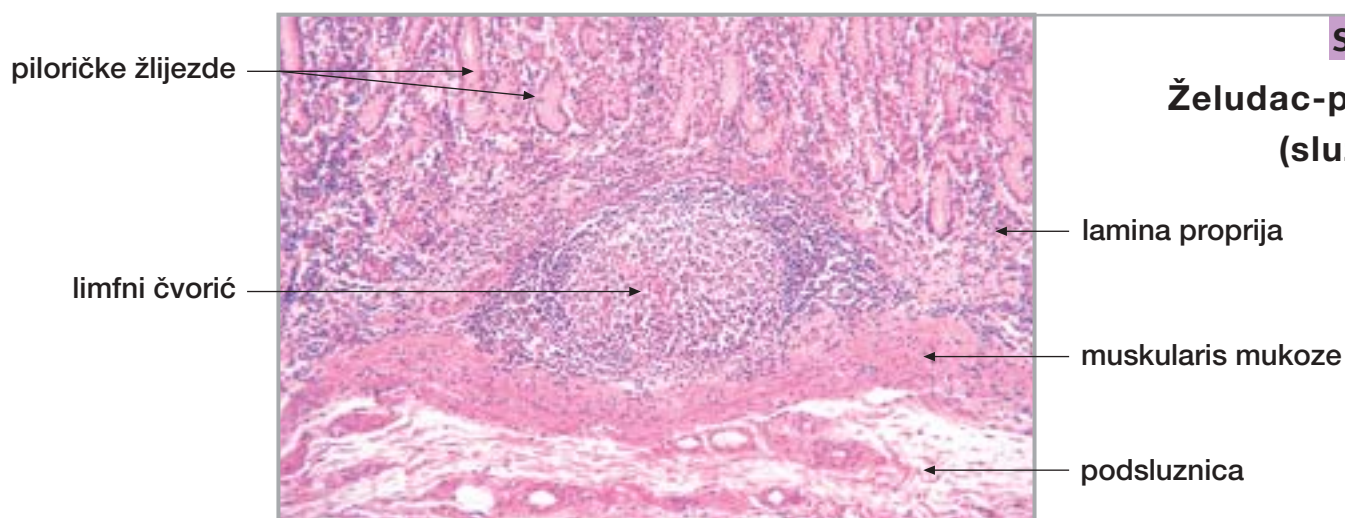
Želudac-pilorus (jamice)





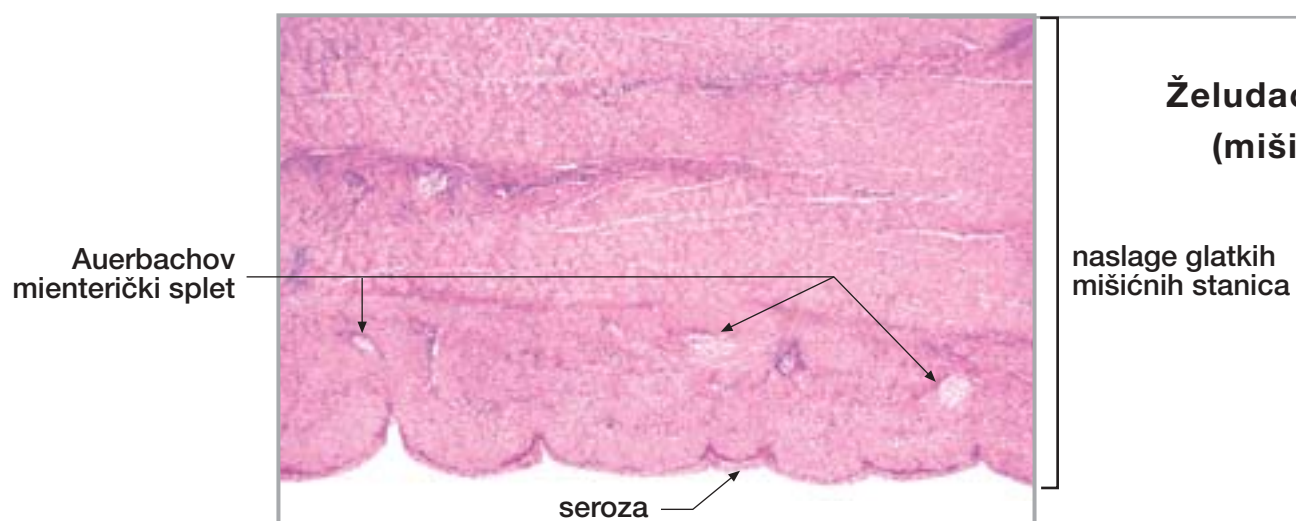
Sl. 166.

Želudac-pilorus
(žlijezde)



Sl. 167.

Želudac-pilorus
(sluznica)



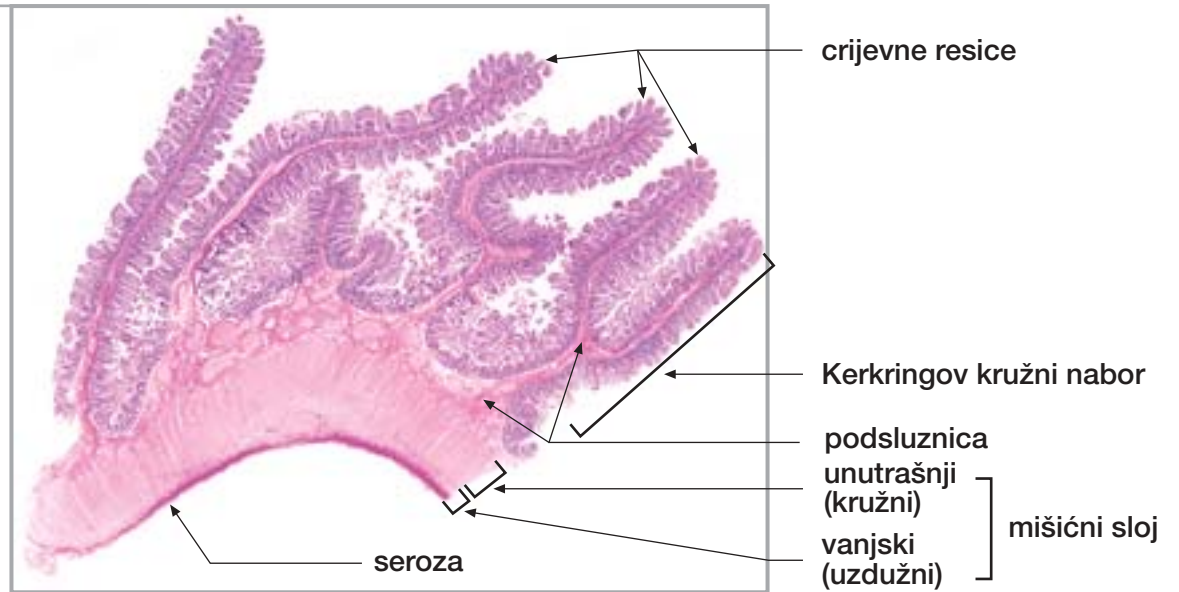
Sl. 168.

Želudac-pilorus
(mišićni sloj i seroza)

20. TANKO CRIJEVO

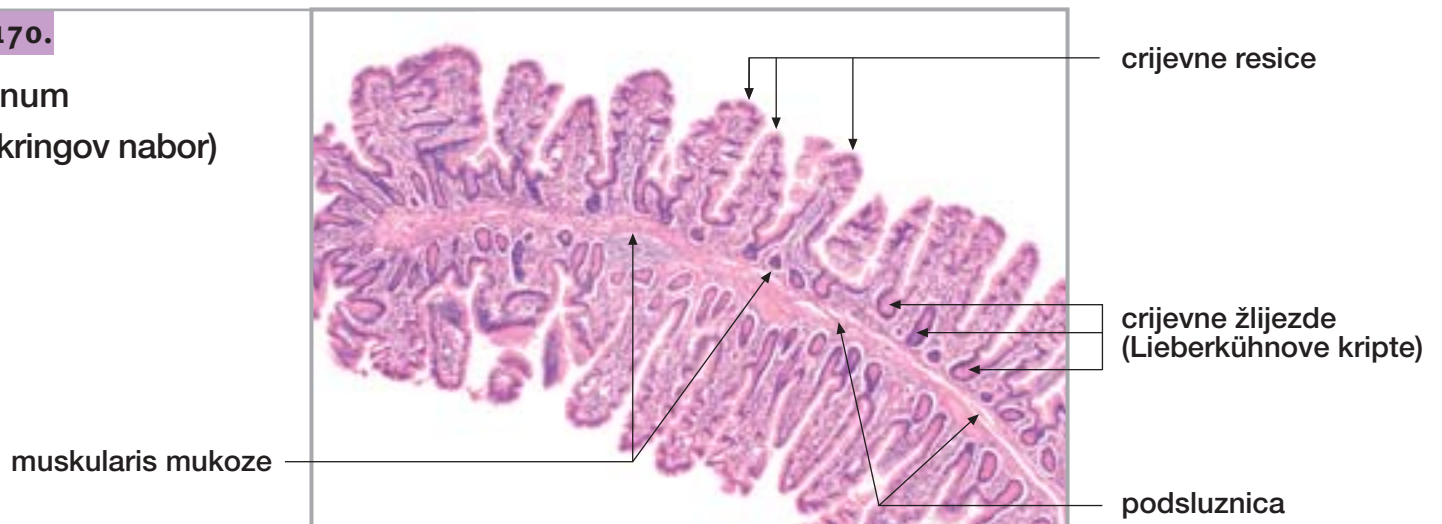
Sl. 169.

Jejunum
(uzdužni presjek)



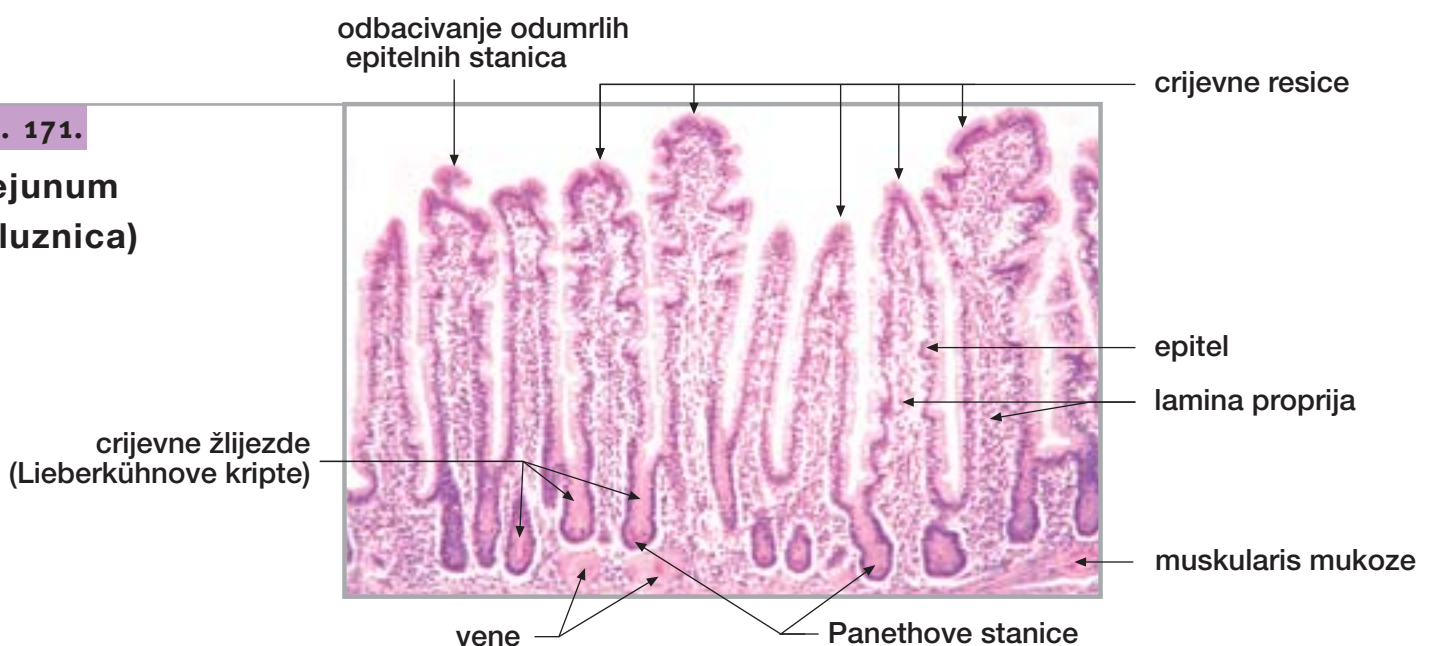
Sl. 170.

Jejunum
(Kerkringov nabor)



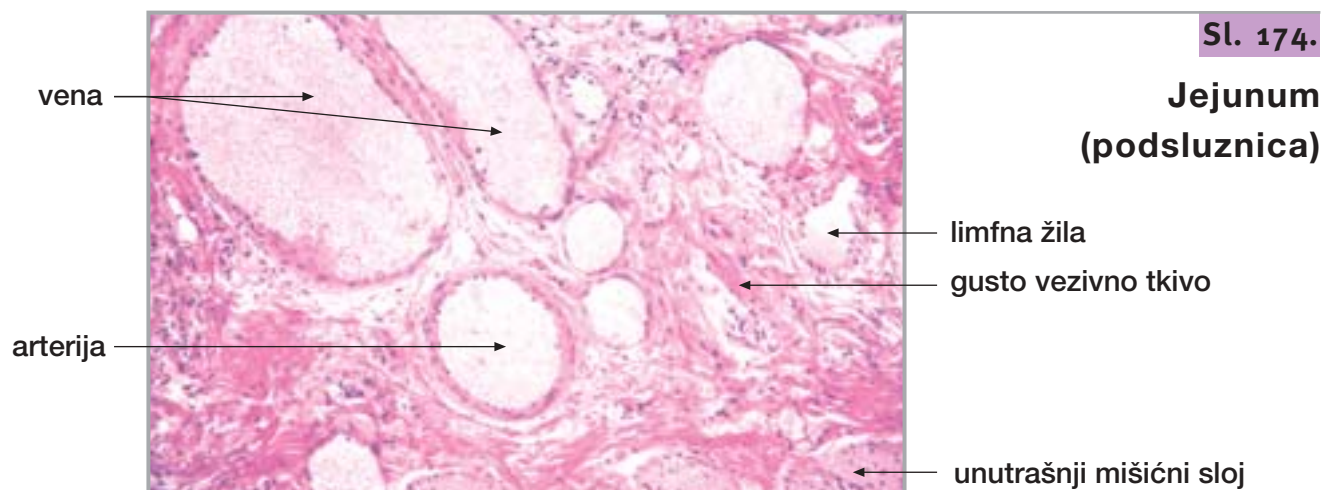
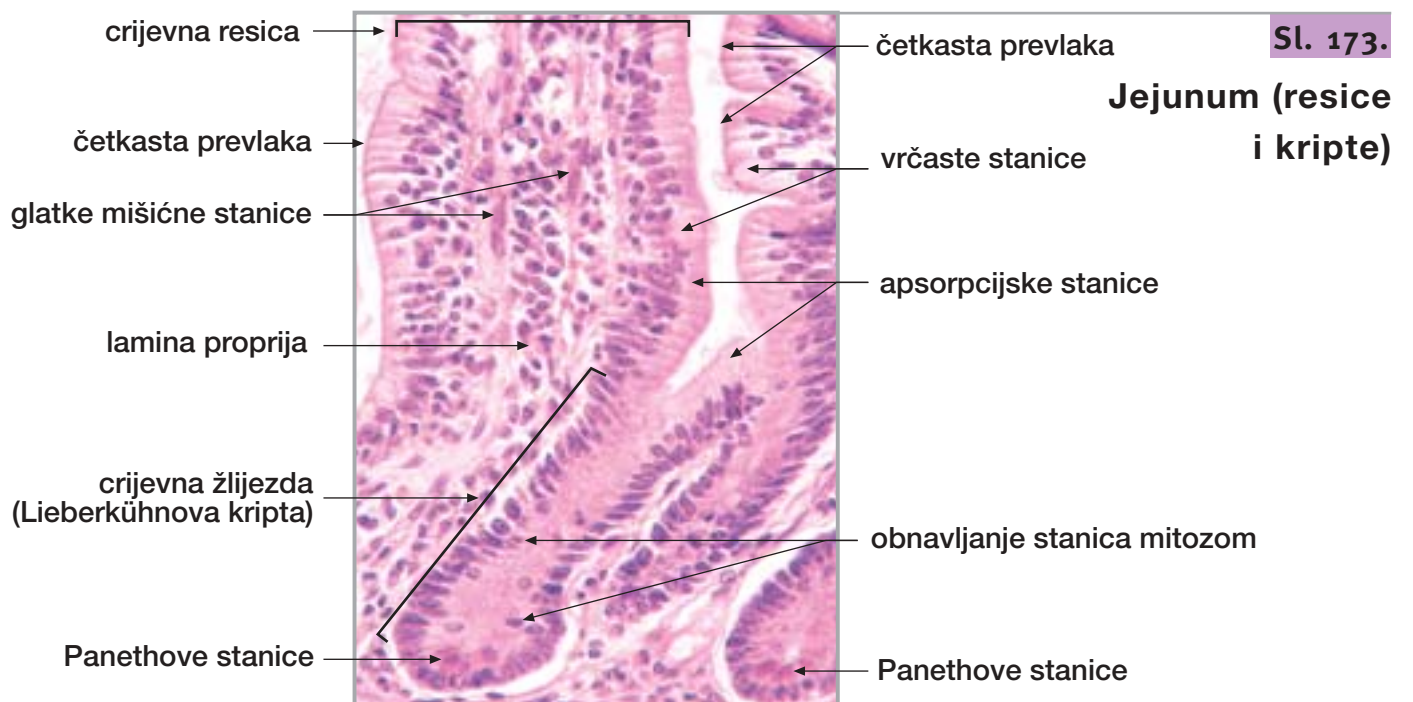
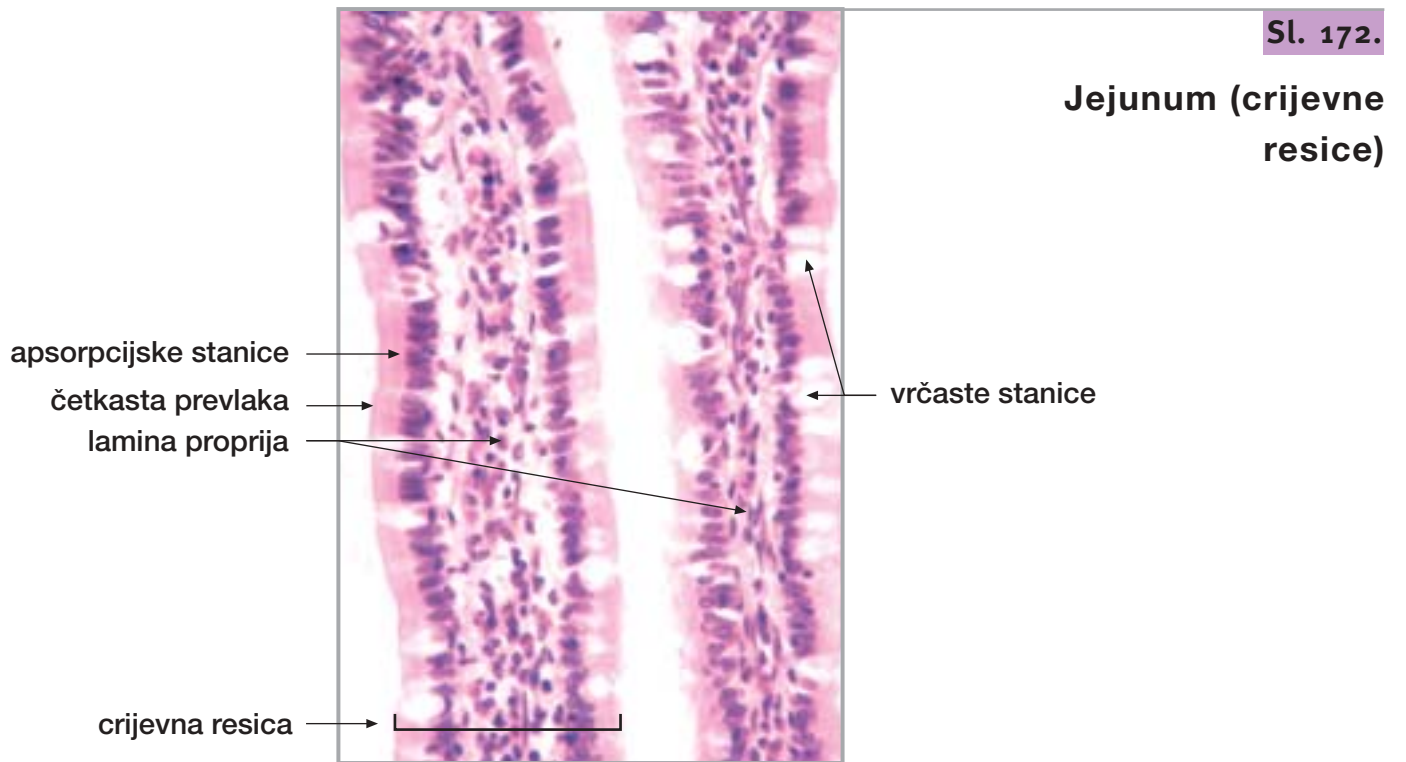
Sl. 171.

Jejunum
(sluznica)



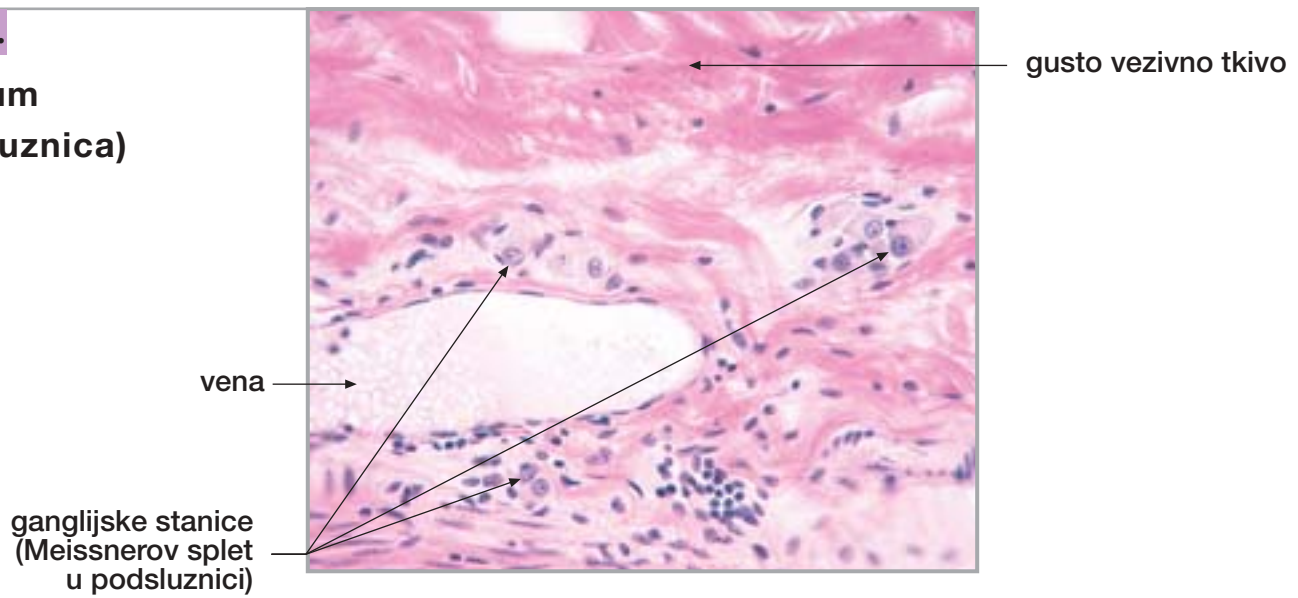
20. TANKO CRIJEVO

nastavak



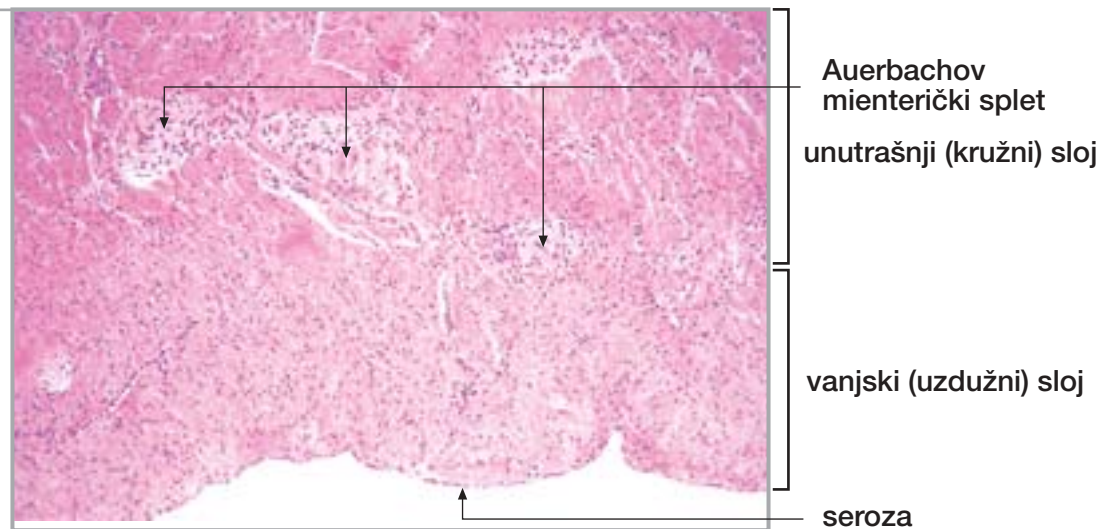
Sl. 175.

Jejunum
(podsluznica)



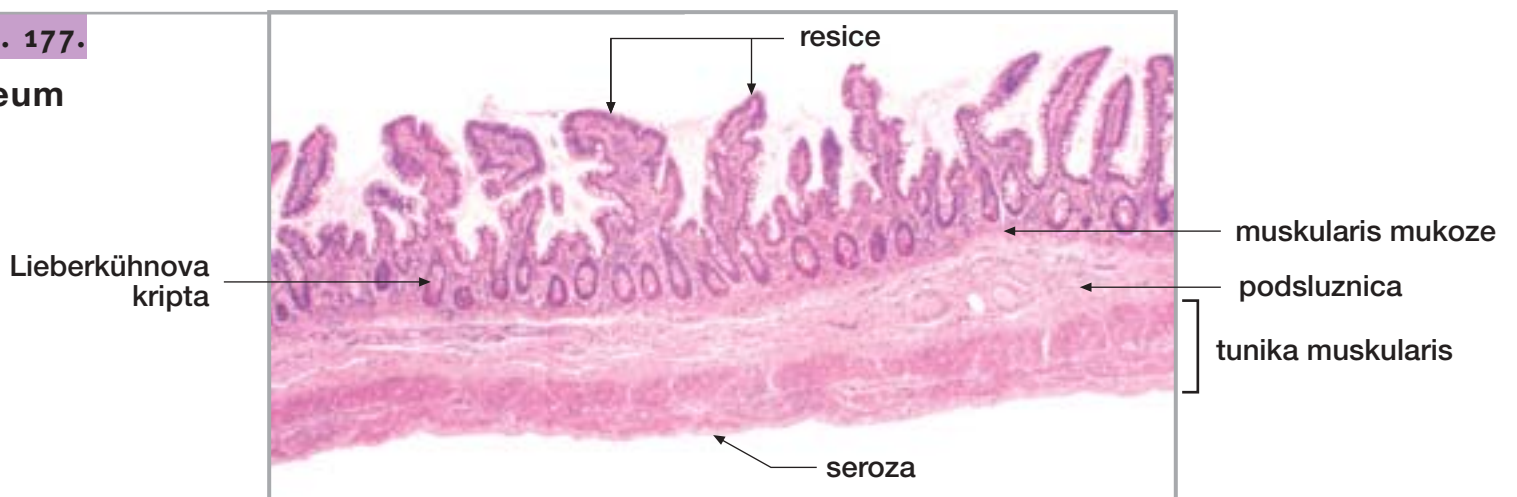Sl. 176.

Jejunum
(mišićni sloj)

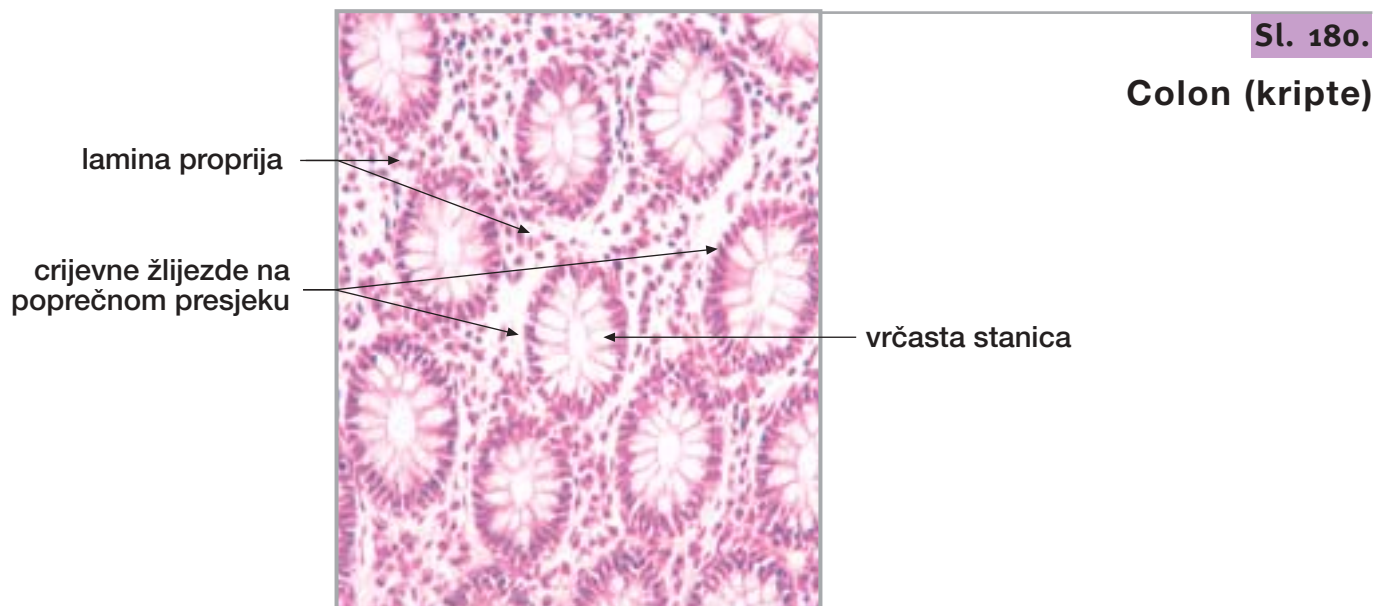
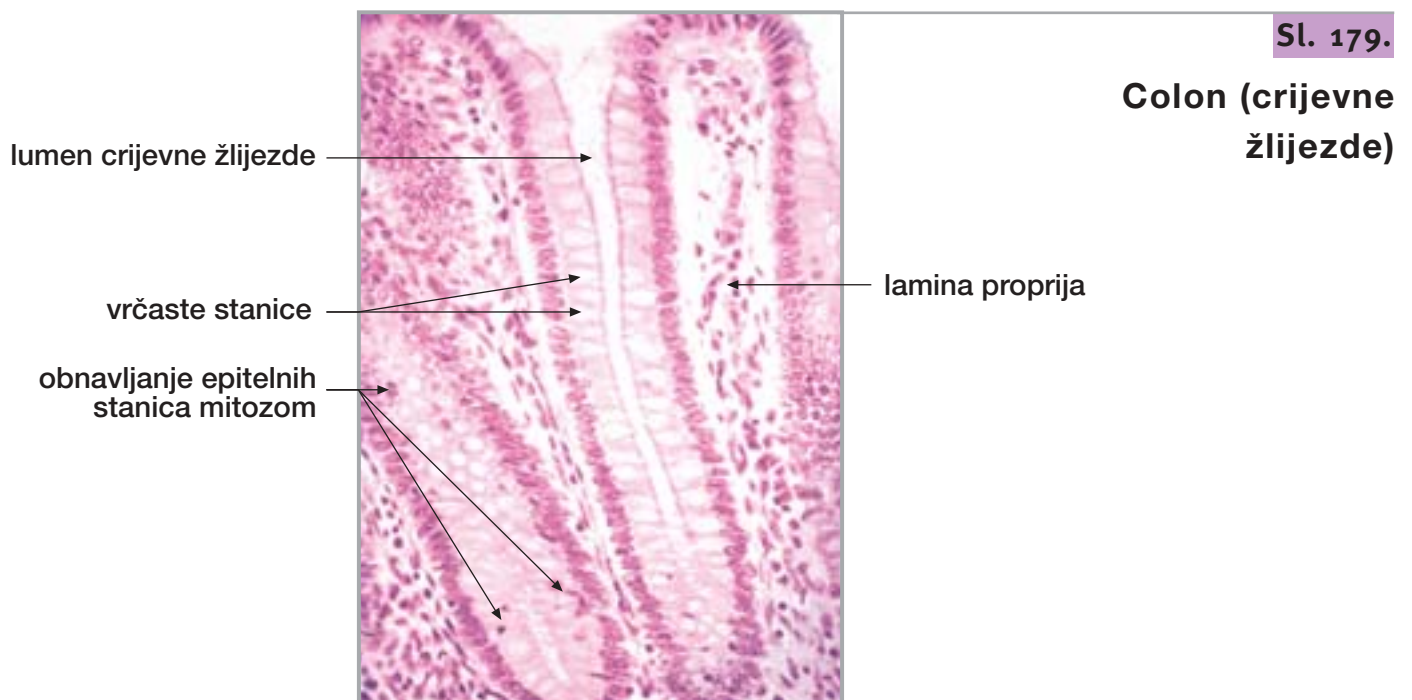
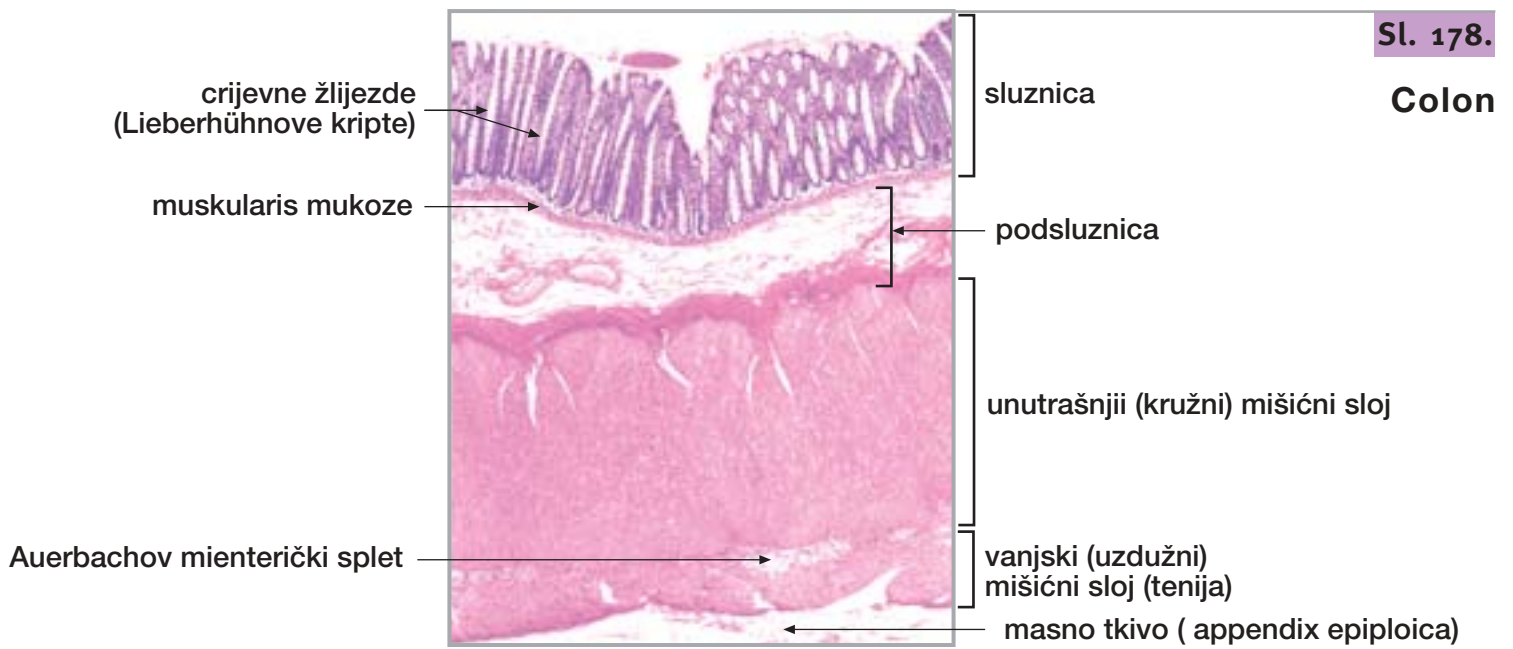


Sl. 177.

Ileum



21. DEBELO CRIJEVO



Sl. 181.

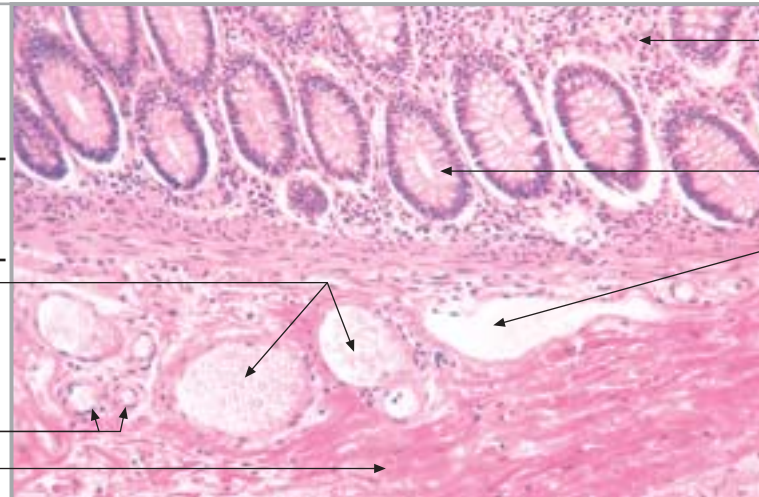
**Colon
(podsluznica)**

muskularis mukoze

vene

arterije

gusto vezivno tkivo



lamina propria

dno crijevne žlijezde

limfna žila

podsluznica

Sl. 182.

Colon (mišićni sloj)

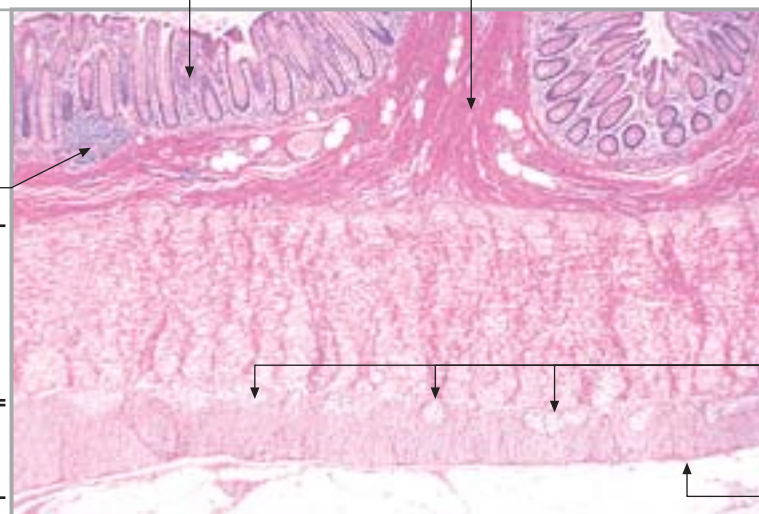
limfni čvorić

kružni mišićni sloj

uzdužni mišićni sloj (tenija)

sluznica

podsluznica



Auerbachov
mienterički splet

seroza

Sl. 183.

Crvuljak

sluznica

podsluznica

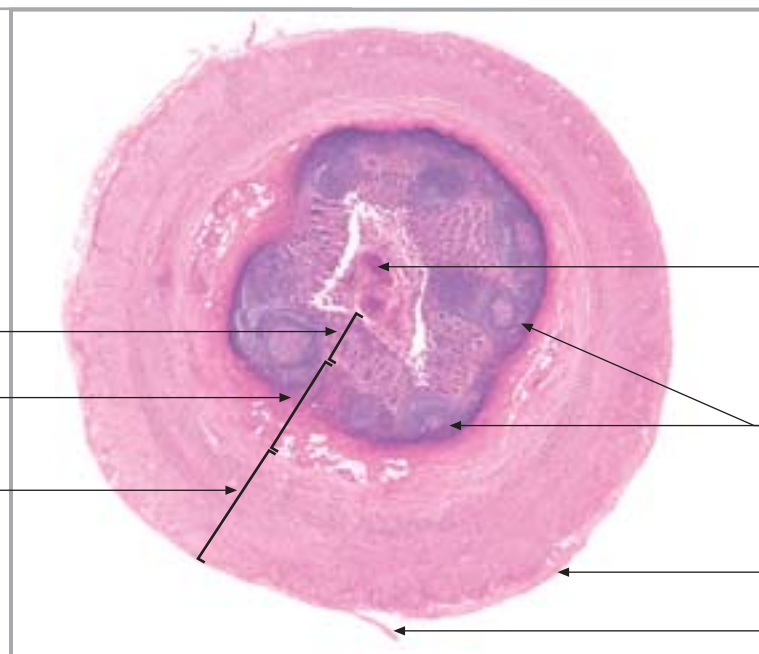
mišićni sloj

sadržaj (homogenizacija)

limfno tkivo

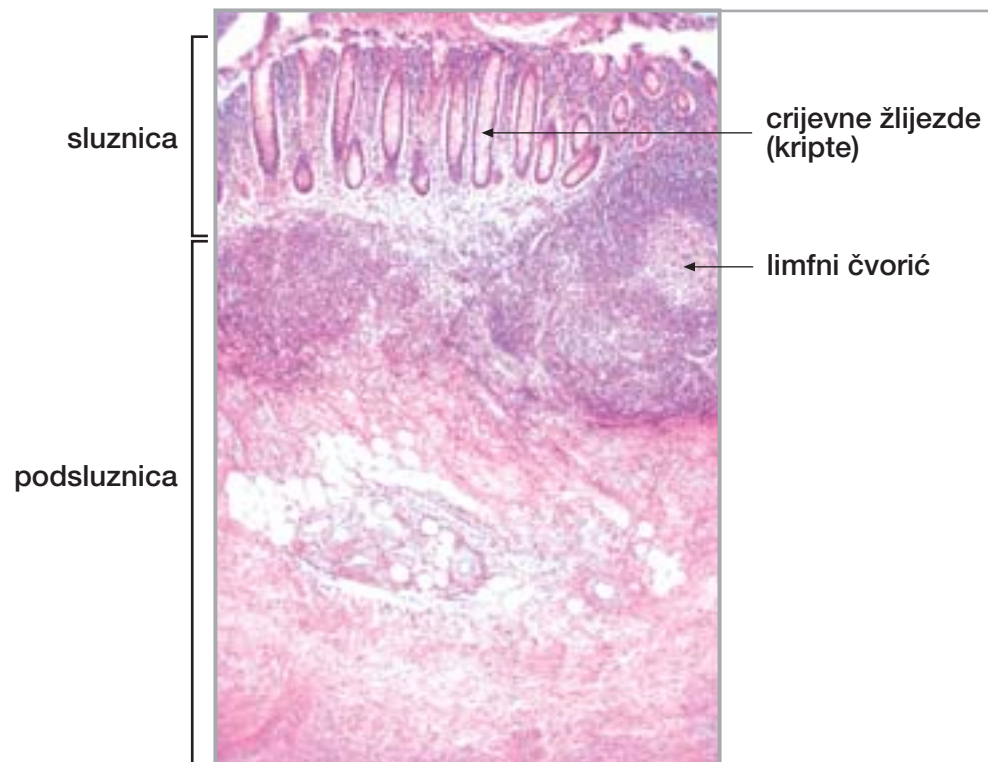
seroza

mesoappendix



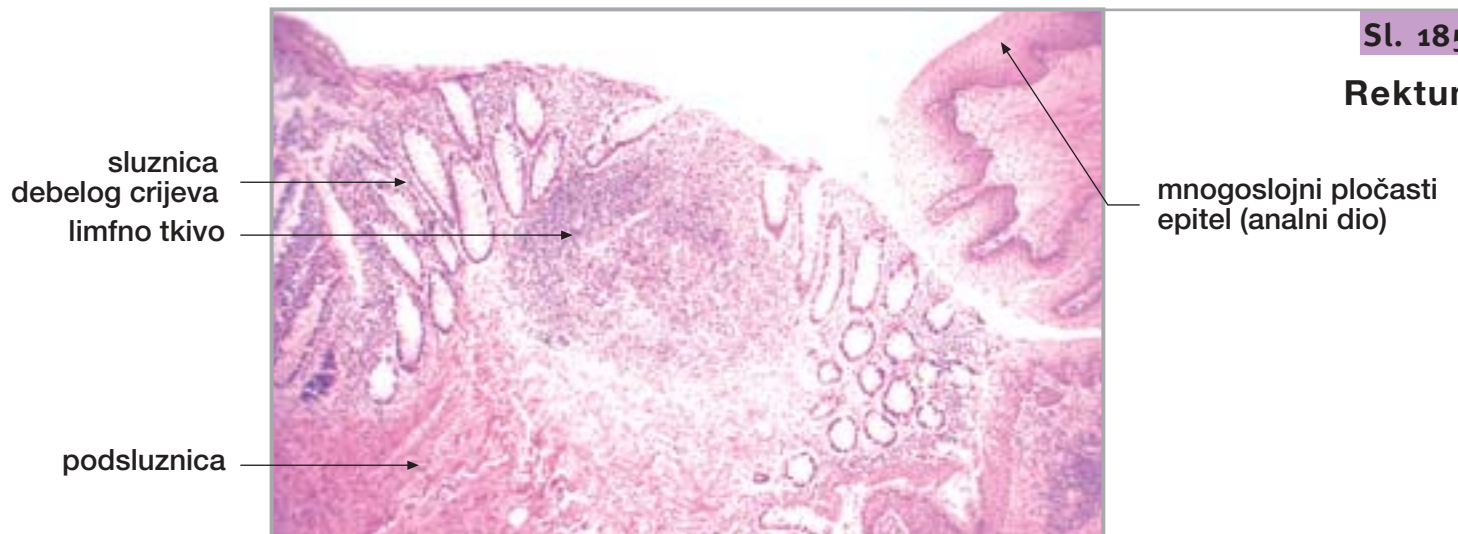
21. DEBELO CRIJEVO

nastavak



Sl. 184.

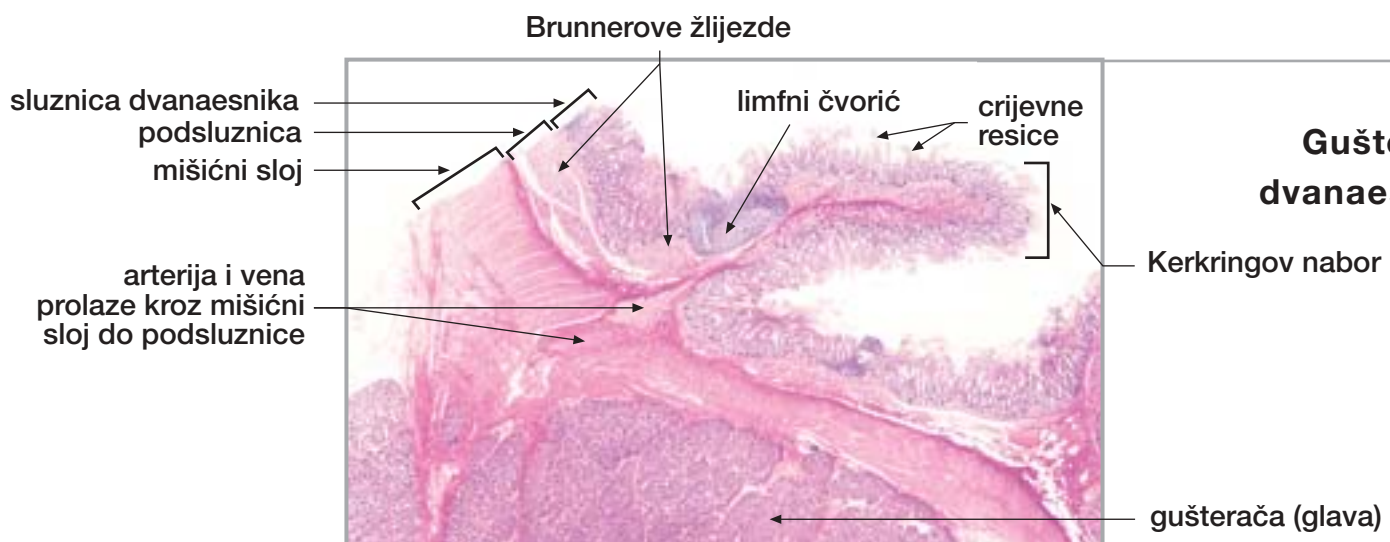
Crvuljak



Sl. 185.

Rektum

22. GUŠTERAČA S DVANAESNIKOM



Sl. 186.

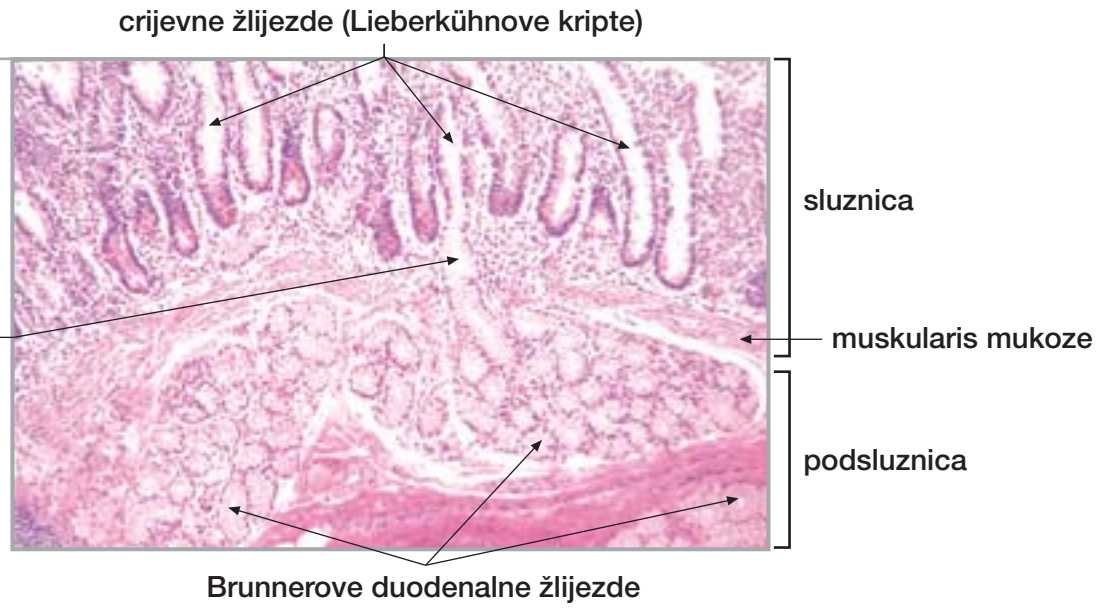
Gušterača s dvanaesnikom

22. GUŠTERAČA S DVANAESNIKOM nastavak

Sl. 187.

Dvanaesnik
(Brunnerove
žlijezde)

Brunnerova žlijezda
se ulijeva u dno kripe



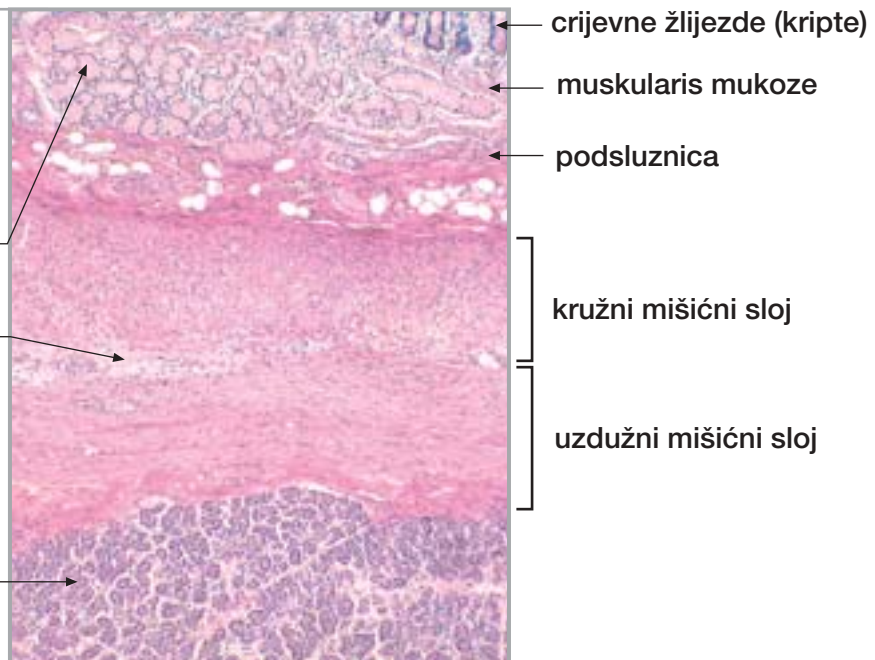Sl. 188.

Dvanaesnik
(mišićni sloj)

Brunnerove
duodenalne žlijezde

Auerbachov
mienterički splet

gušterača

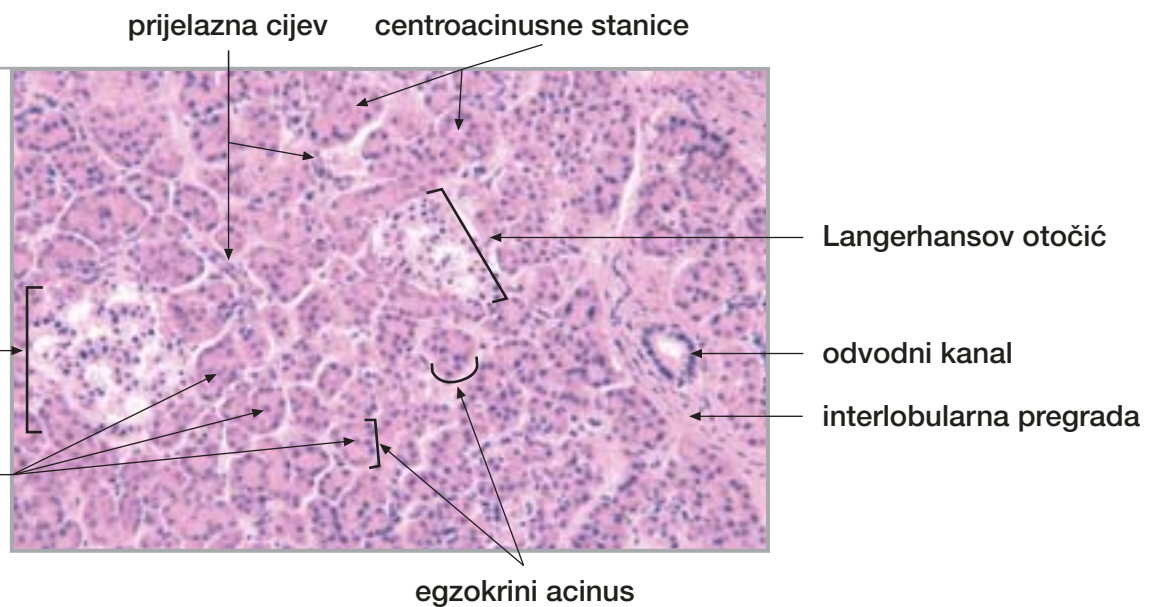


Sl. 189.

Gušterača

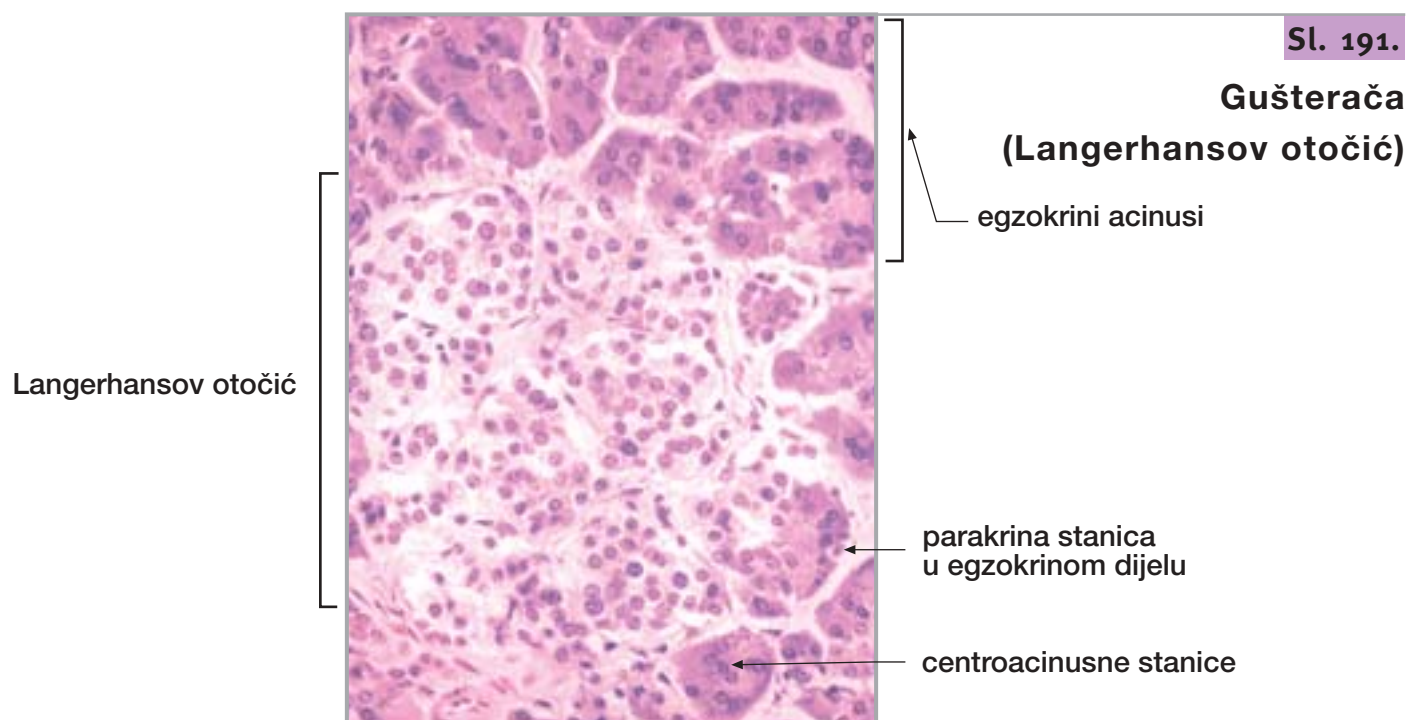
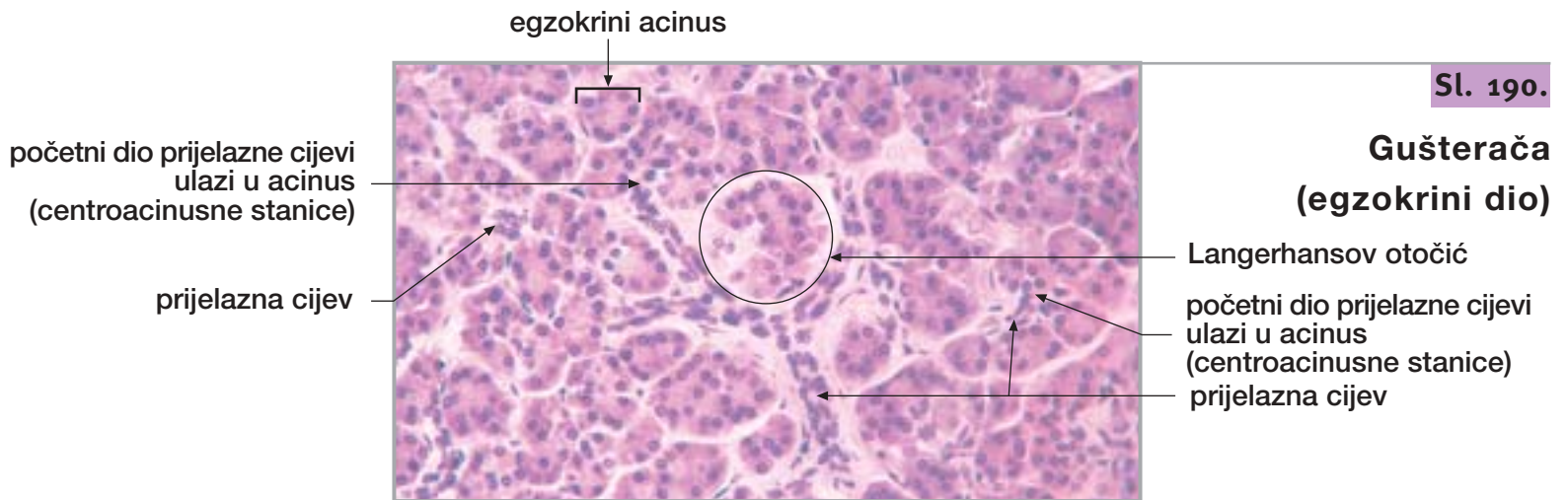
Langerhansov otočić

centroacinusne stanice

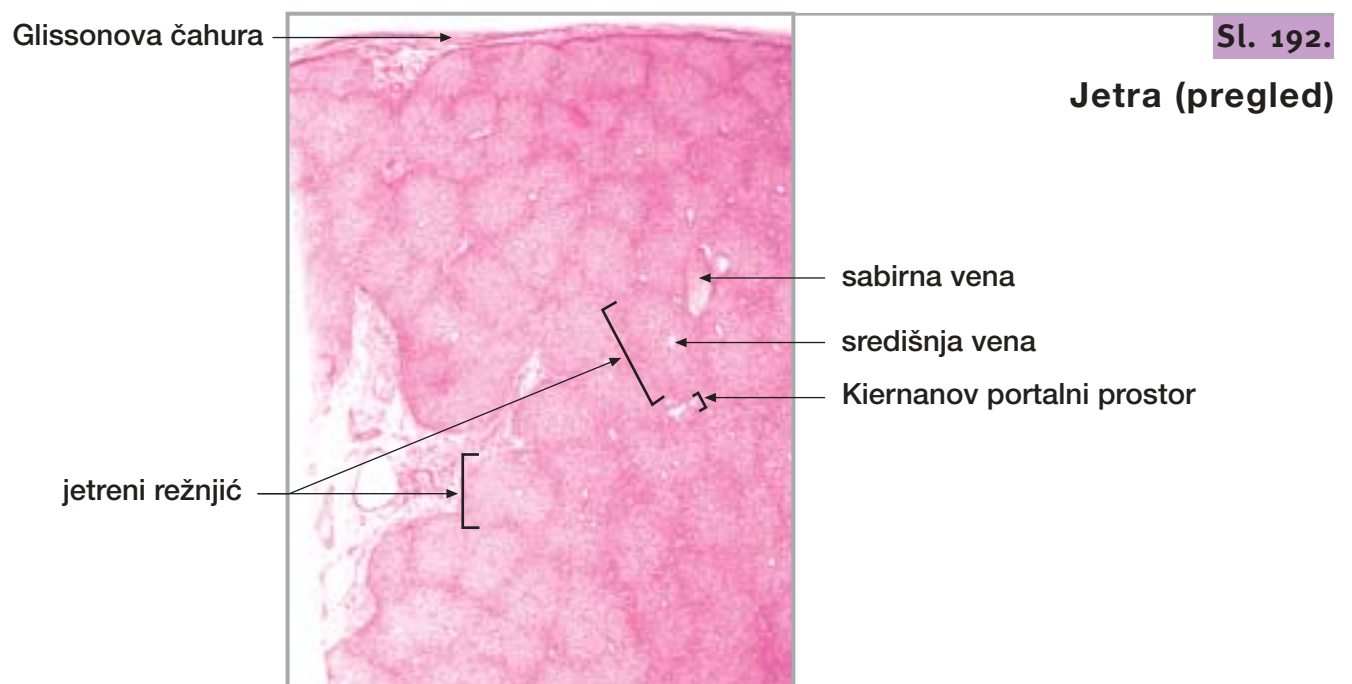


22. GUŠTERAČA S DVANAESNIKOM

nastavak



23. JETRA I ŽUČNI MJEHUR

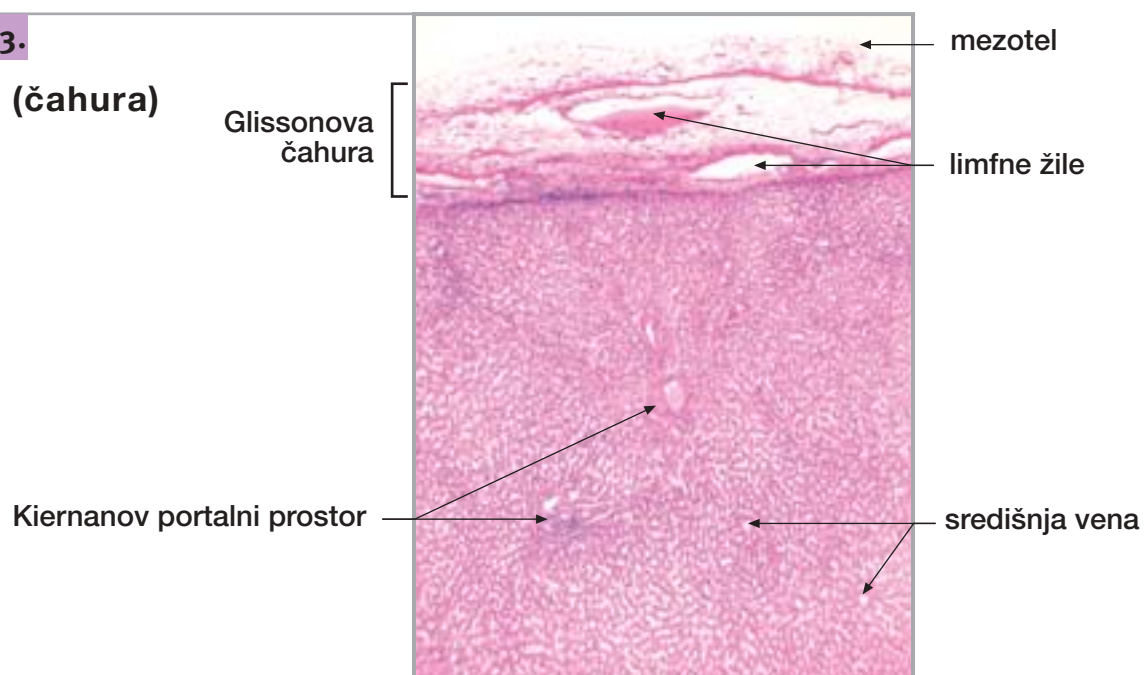


23. JETRA I ŽUČNI MJEHUR

nastavak

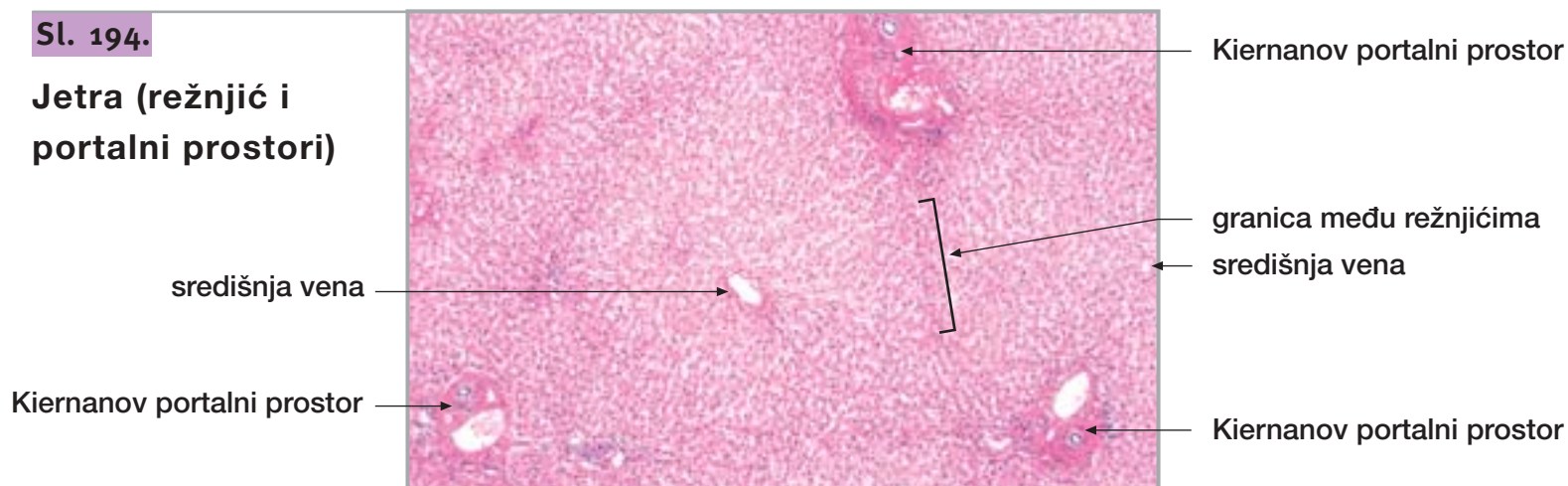
Sl. 193.

Jetra (čahura)



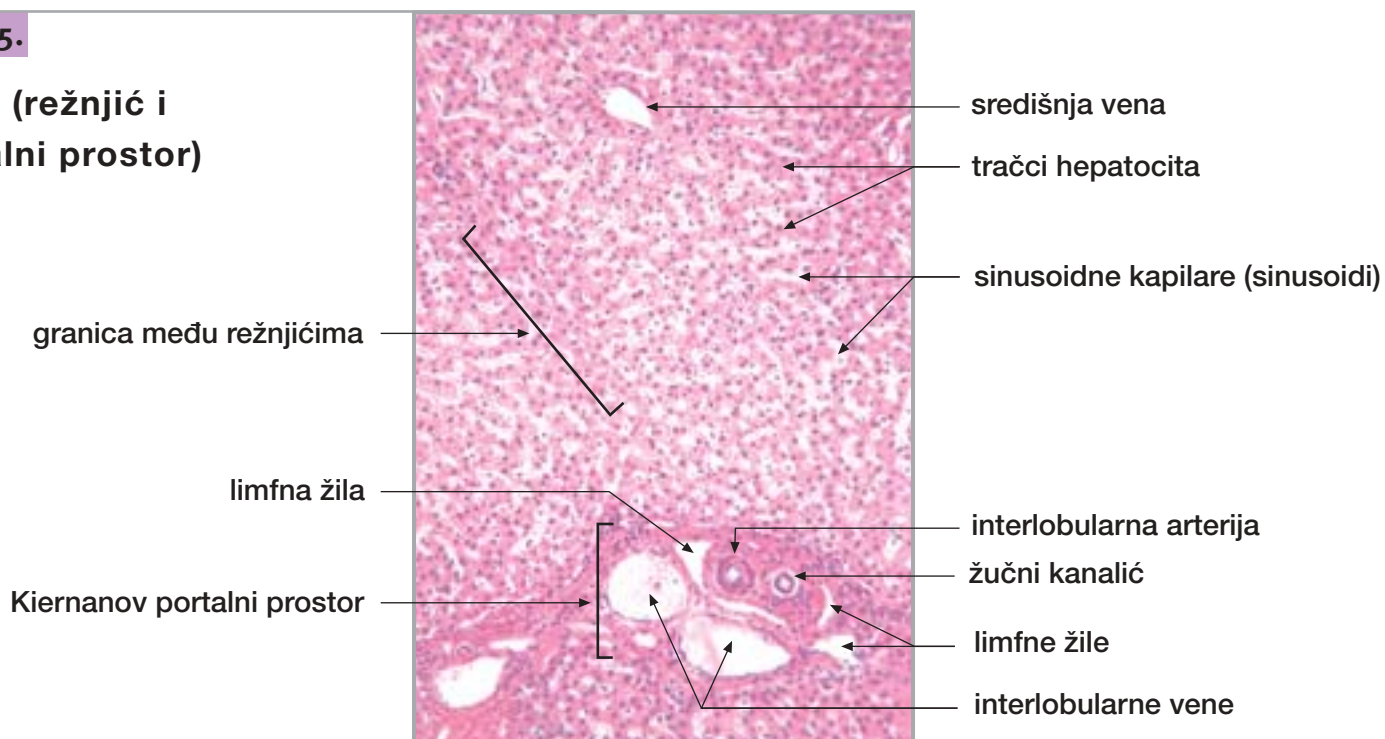
Sl. 194.

Jetra (režnjić i portalni prostori)



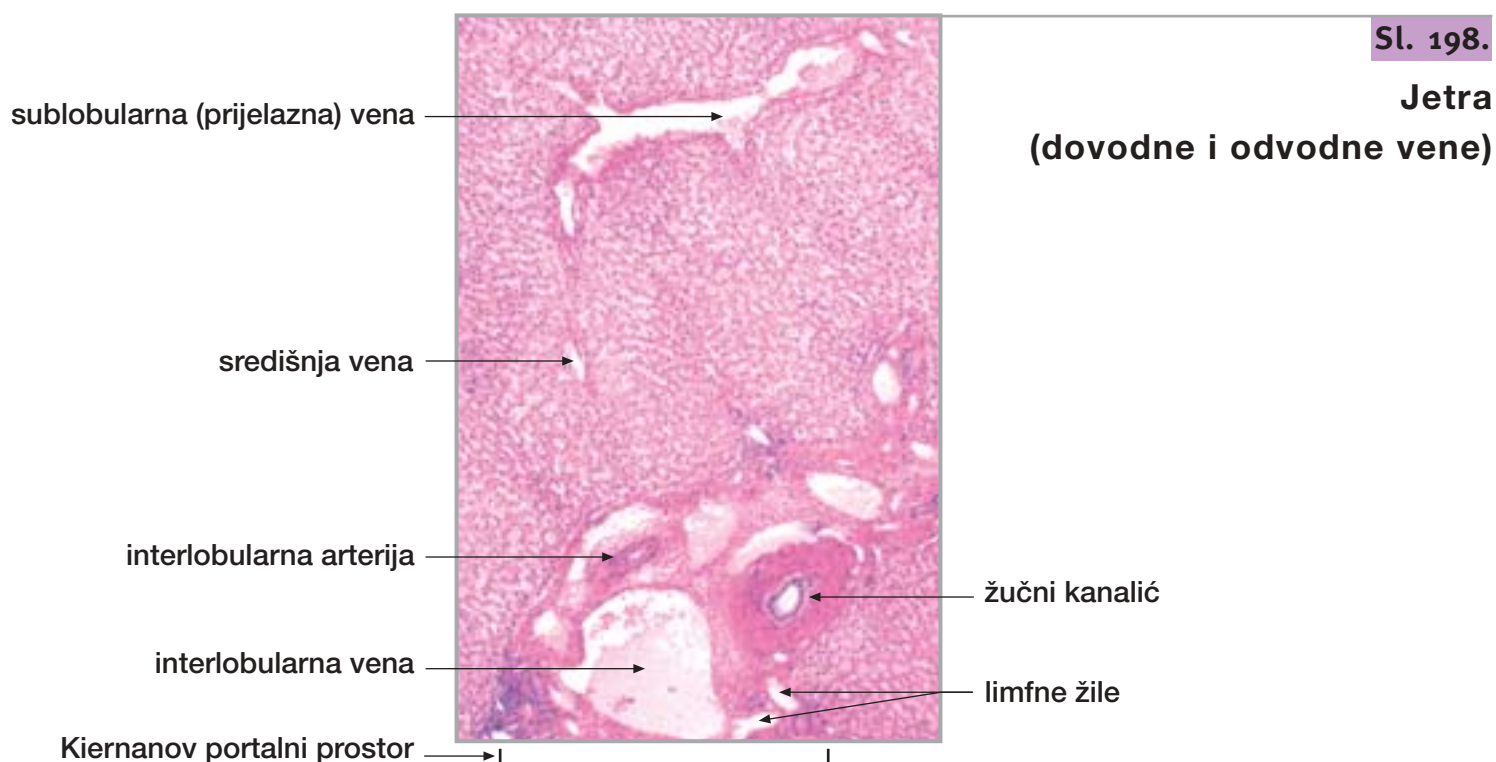
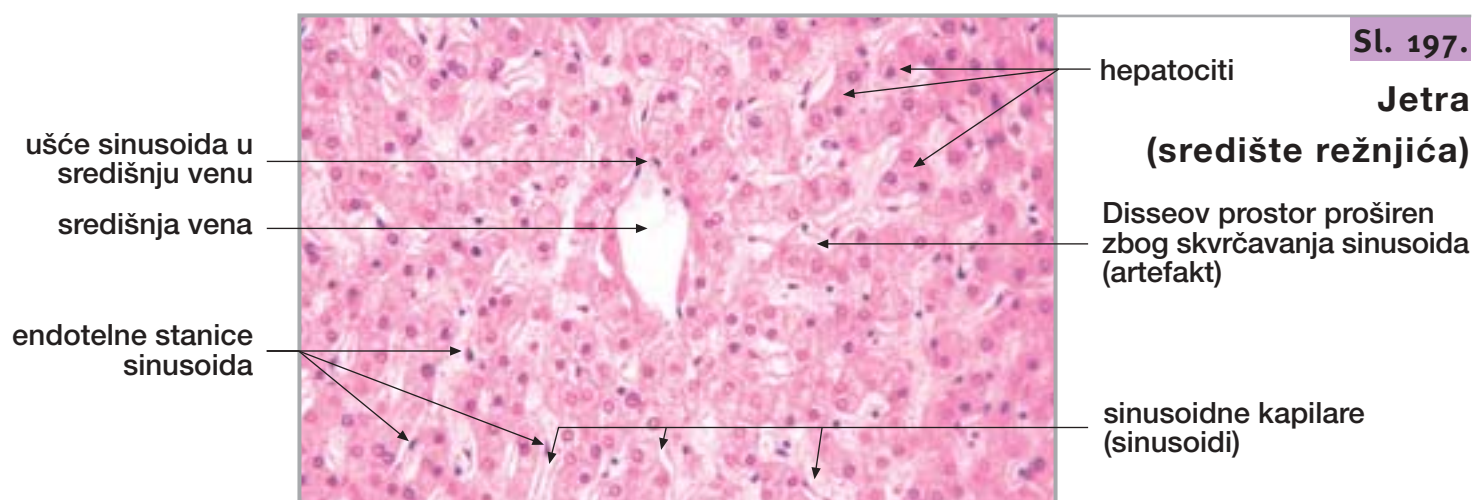
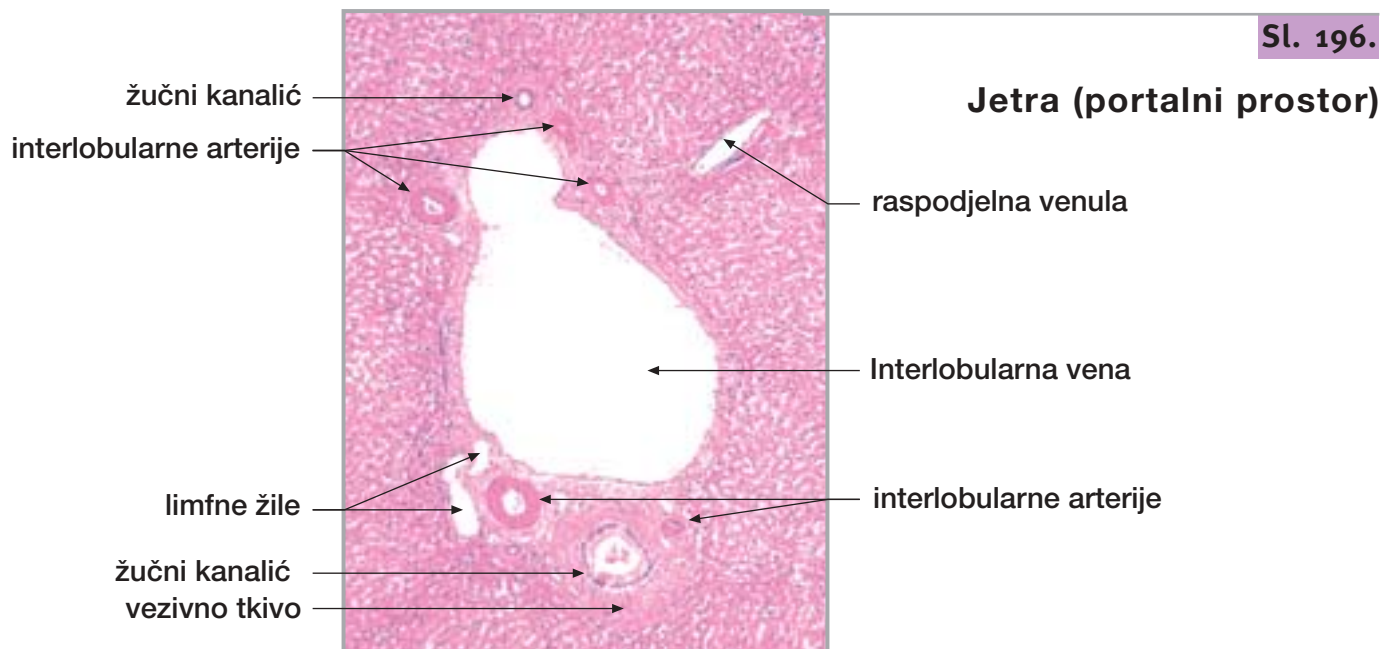
Sl. 195.

Jetra (režnjić i portalni prostor)



23. JETRA I ŽUČNI MJEHUR

nastavak



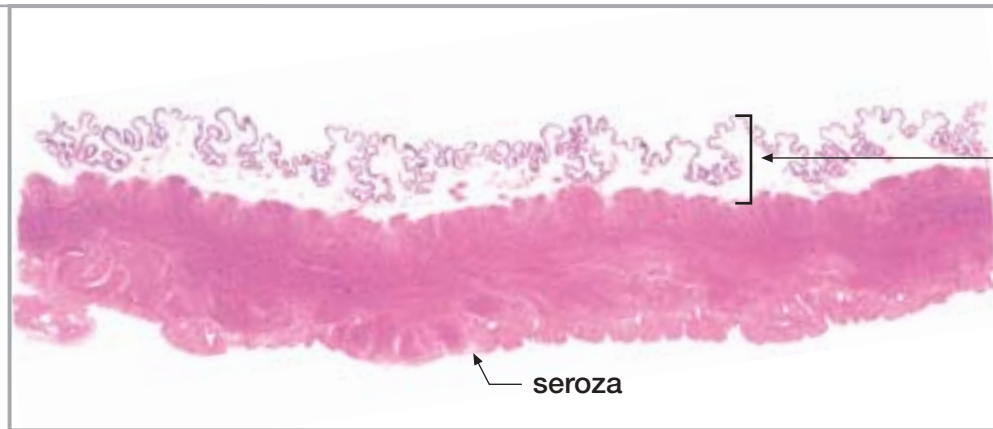23. JETRA I ŽUČNI MJEHUR

nastavak

Sl. 199.

Žučni mjehur

mišićni sloj

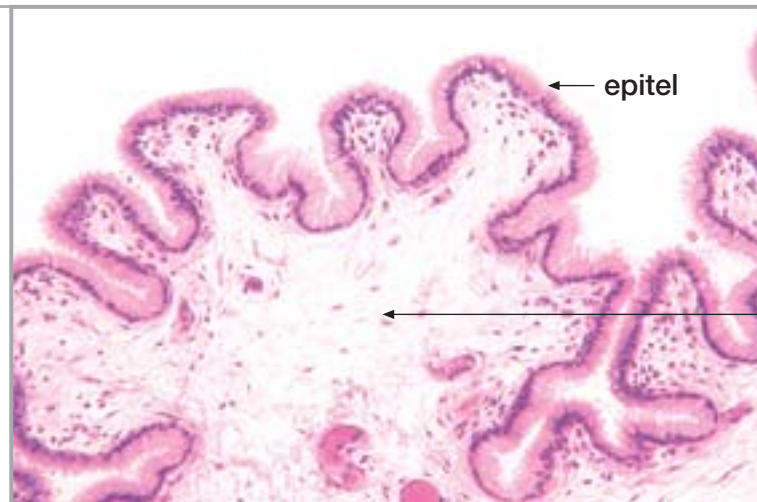


sluznica (nabori)

seroza

Sl. 200.

Žučni mjehur
(sluznica)



epitel

lamina proprija

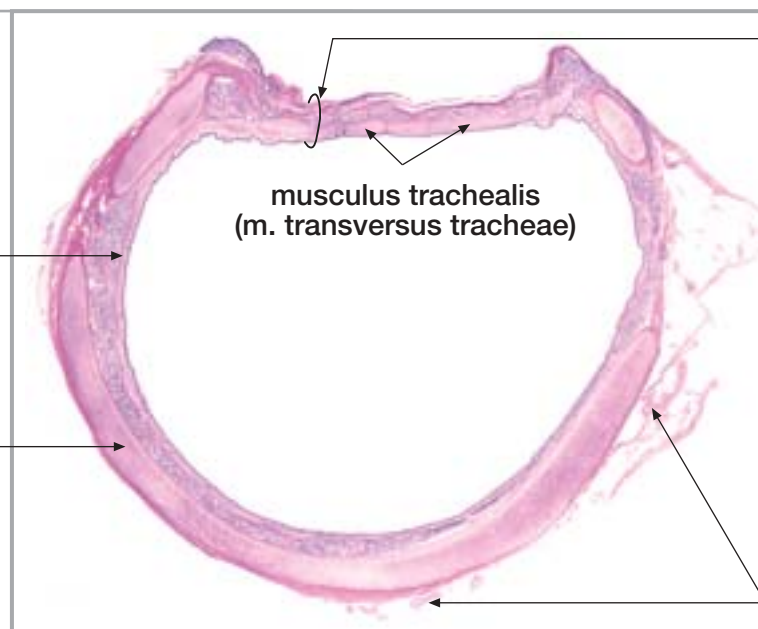
24. DUŠNIK I PLUĆA

Sl. 201.

Dušnik
(poprečni presjek)

sluznica

hrskavica



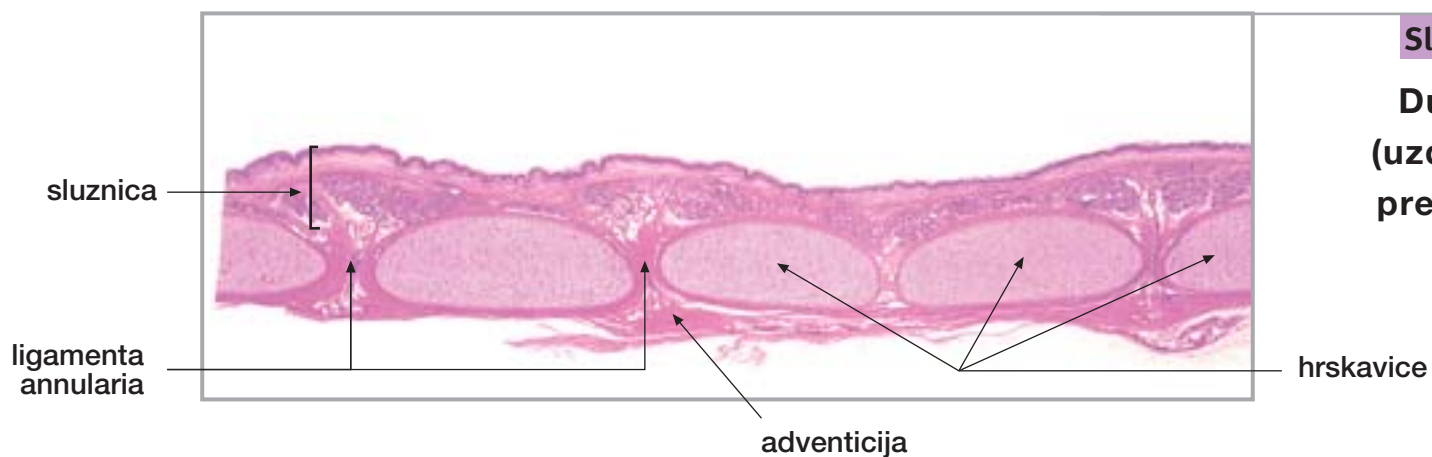
paries membranaceus

musculus trachealis
(m. transversus tracheae)

adventicia

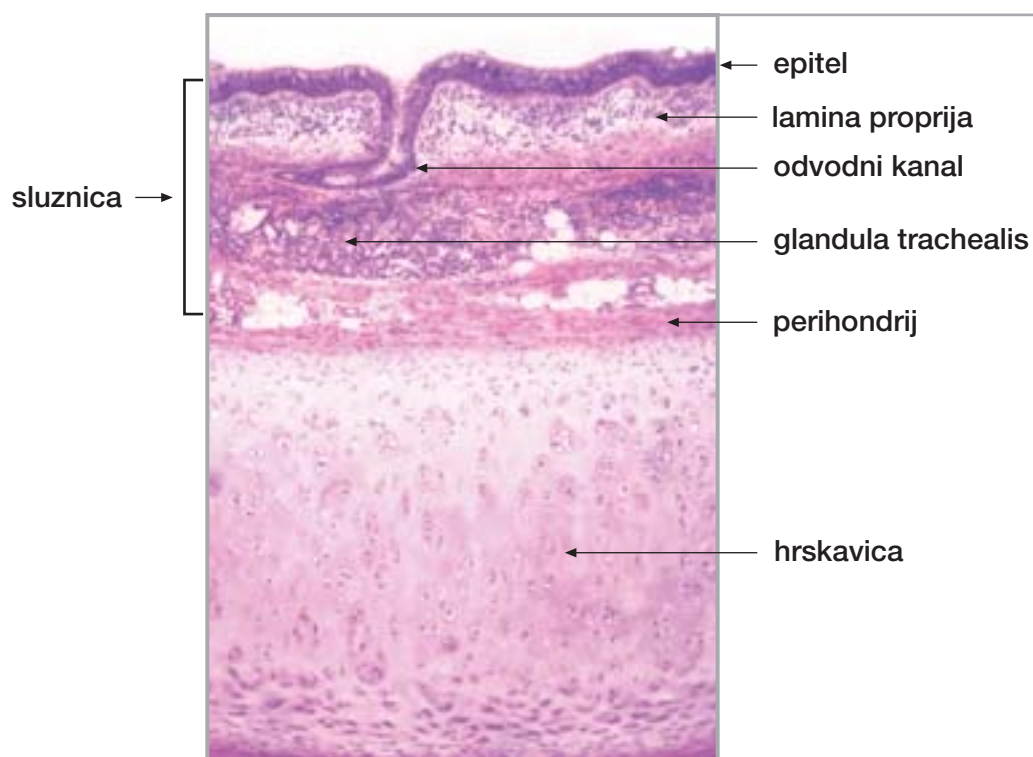
24. DUŠNIK I PLUĆA

nastavak



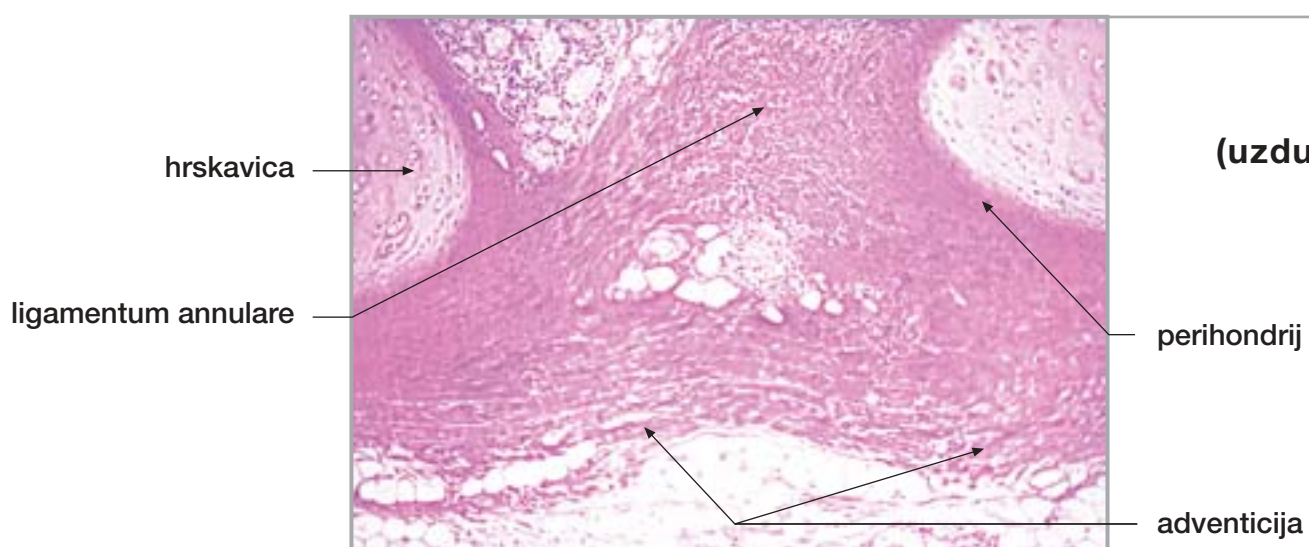
Sl. 202.

Dušnik
(uzdužni presjek)



Sl. 203.

Dušnik

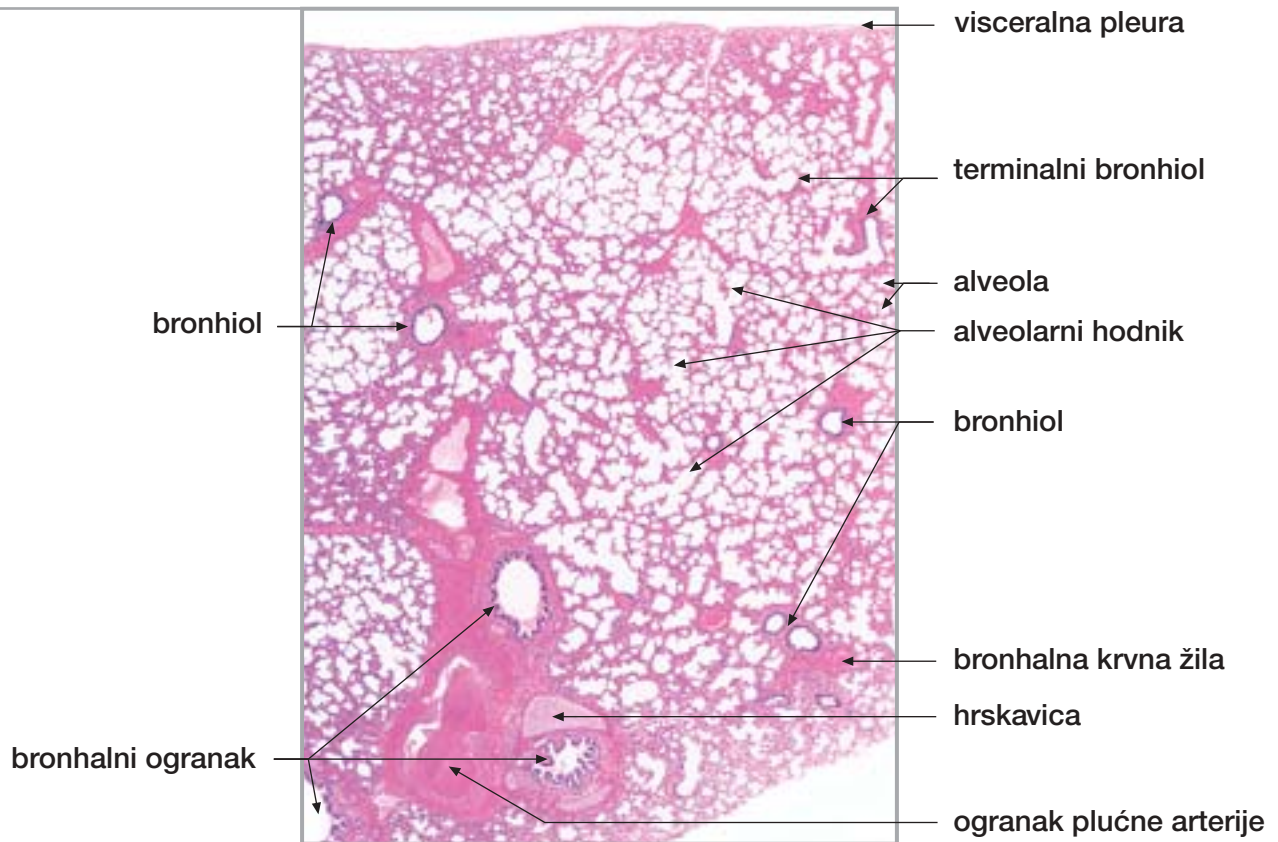


Sl. 204.

Dušnik
(uzdužni presjek)

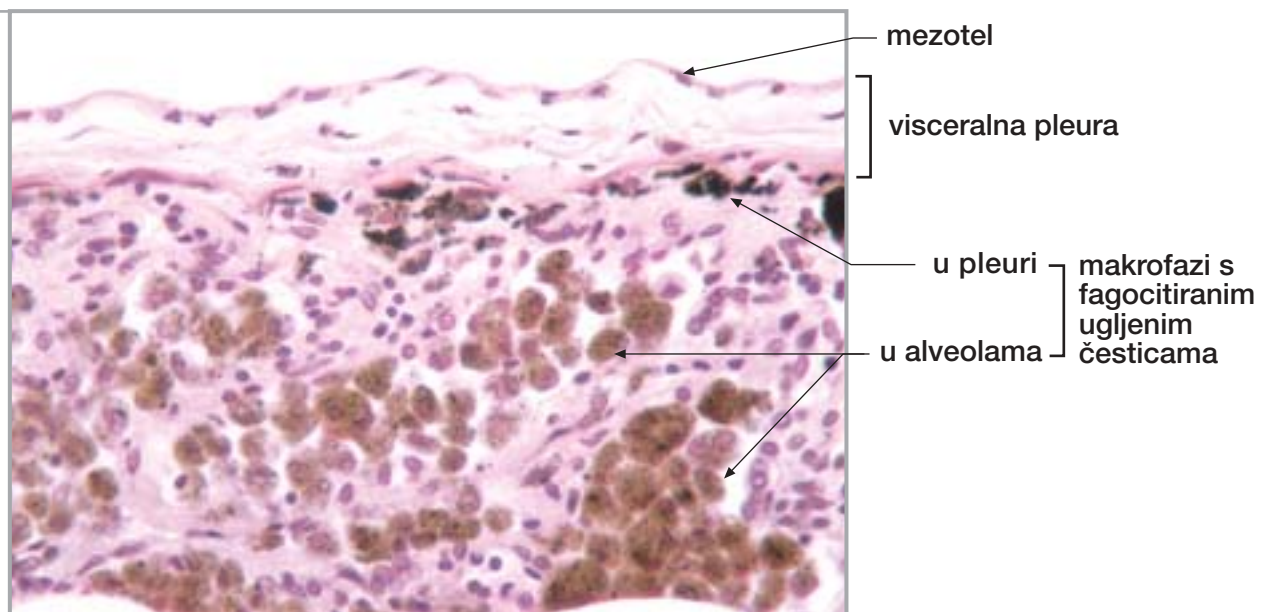
Sl. 205.

Pluća



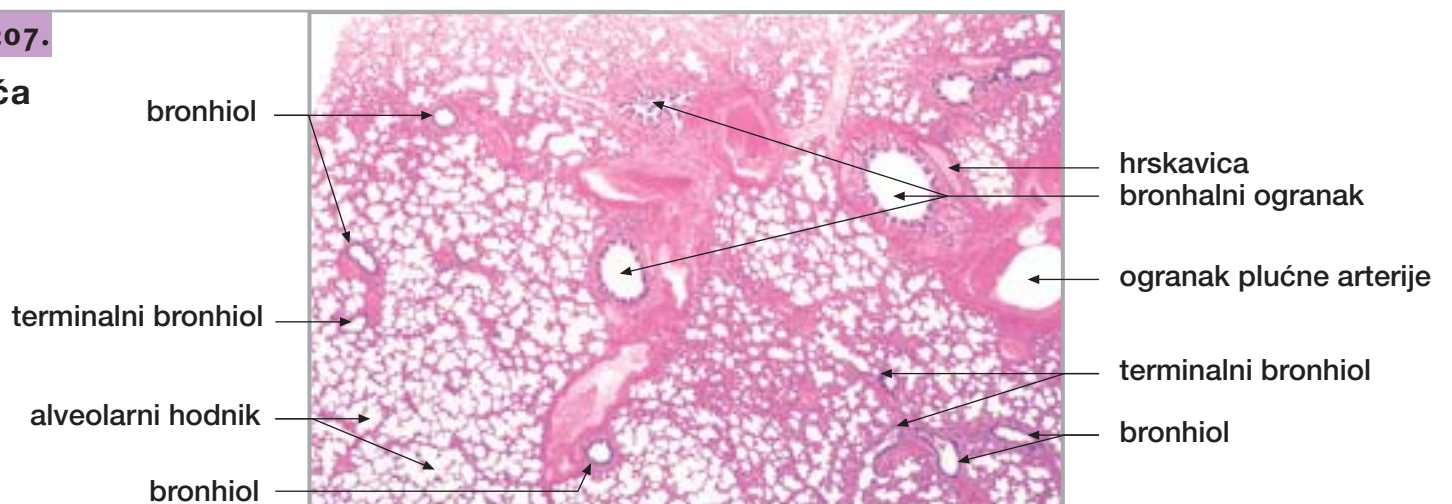
Sl. 206.

Pluća
(periferija)



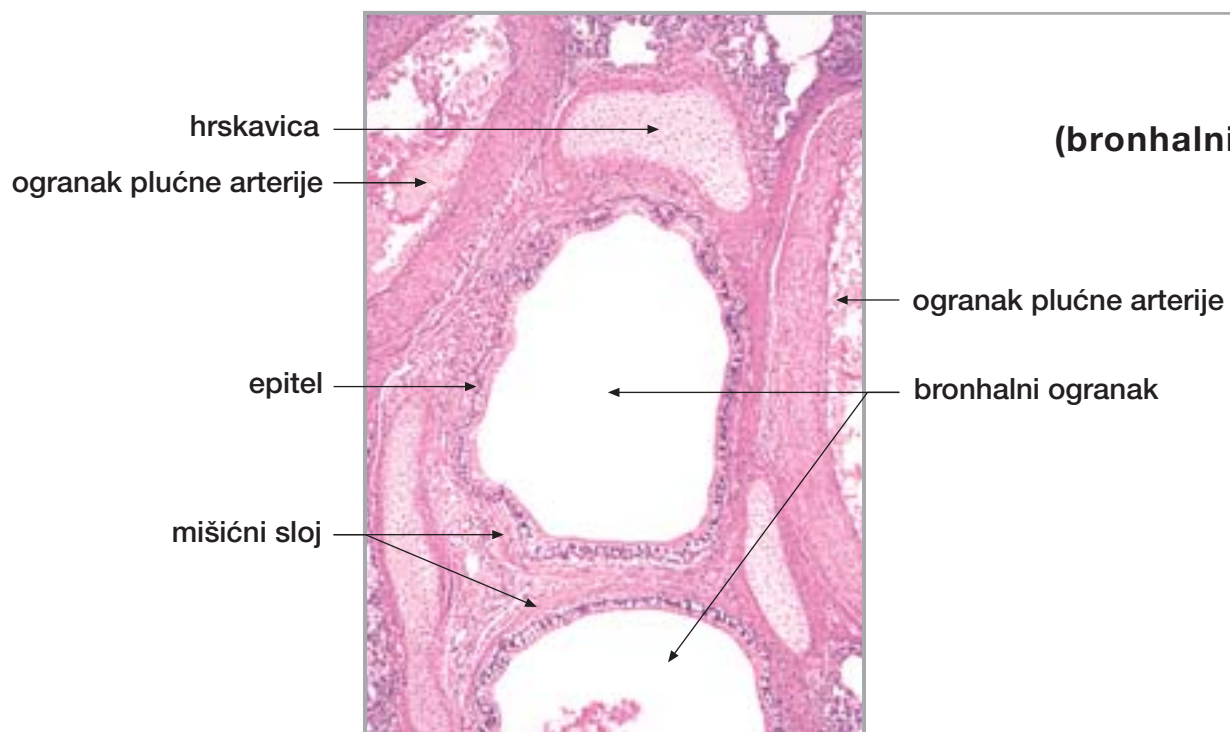
Sl. 207.

Pluća



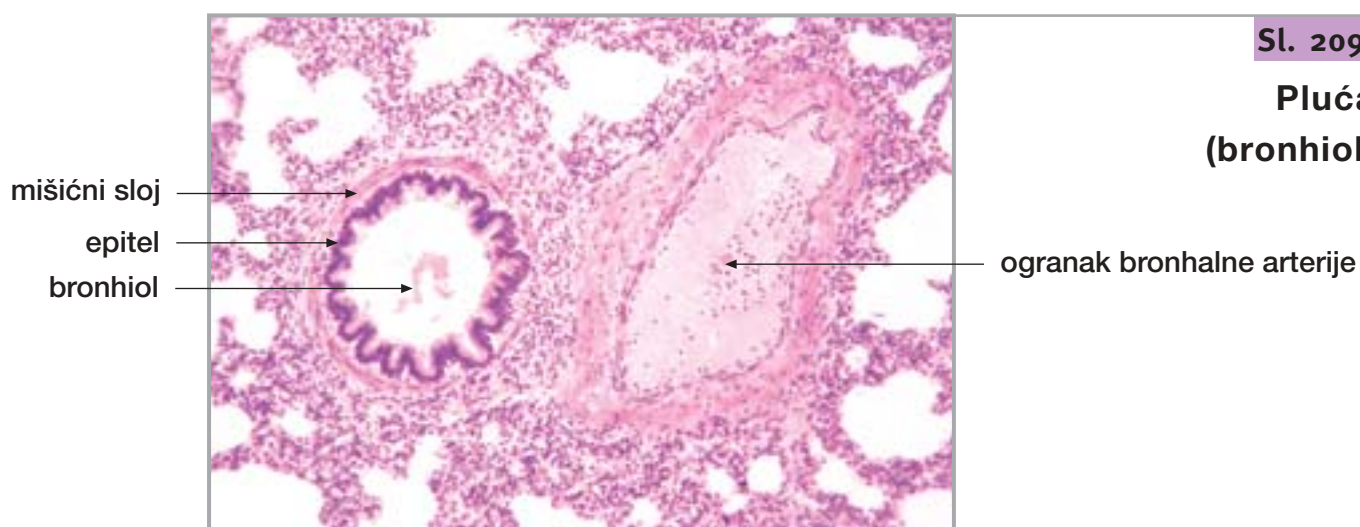
24. DUŠNIK I PLUĆA

nastavak



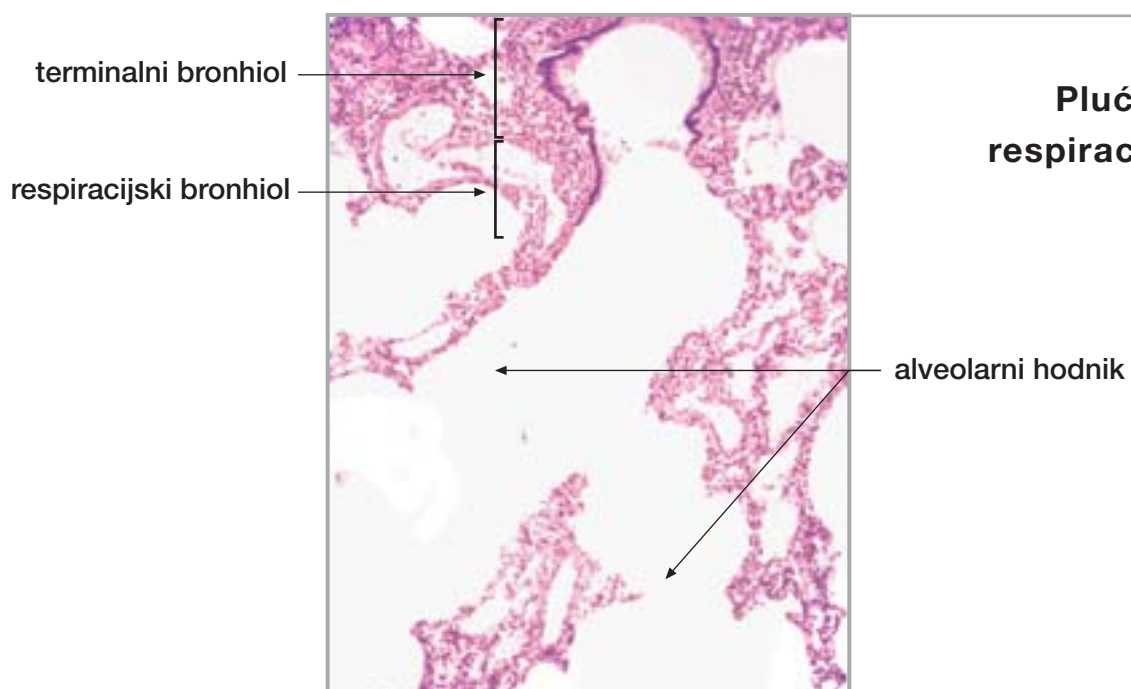
Sl. 208.

**Pluća
(bronhalni ogranak)**



Sl. 209.

**Pluća
(bronhiol)**



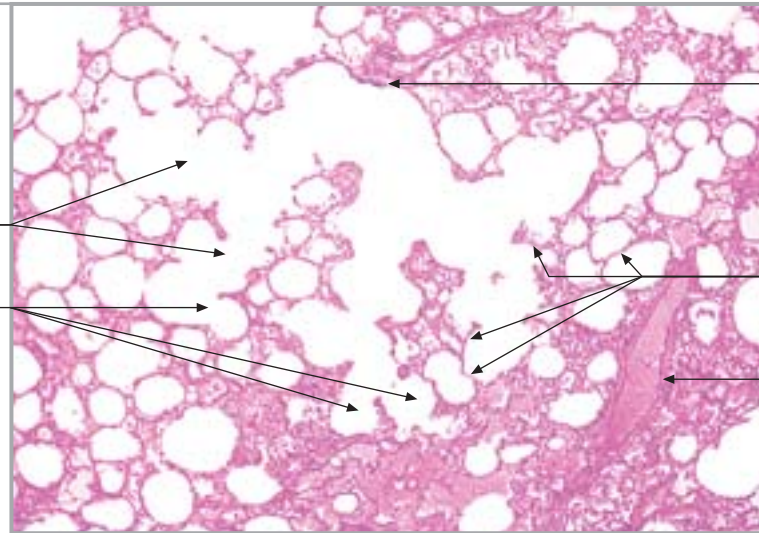
Sl. 210.

**Pluća (terminalni i
respiracijski bronhiol)**

Sl. 211.

Pluća (alveolarni hodnik)

alveolarni hodnik
alveolarna vrećica



epitel respiracijskog bronhiola

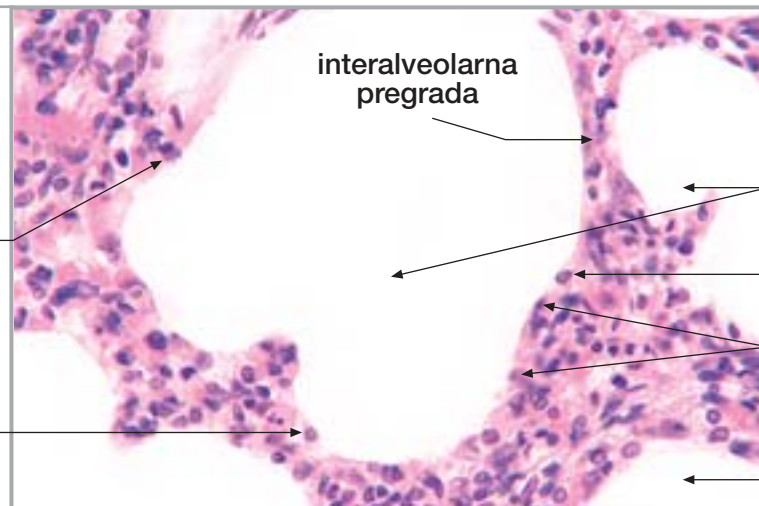
interalveolarna pregrada

ogranak bronhalne arterije

Sl. 212.

Pluća (alveola)

pneumocit I
pneumocit II



interalveolarna pregrada

lumen alveole

pneumocit II

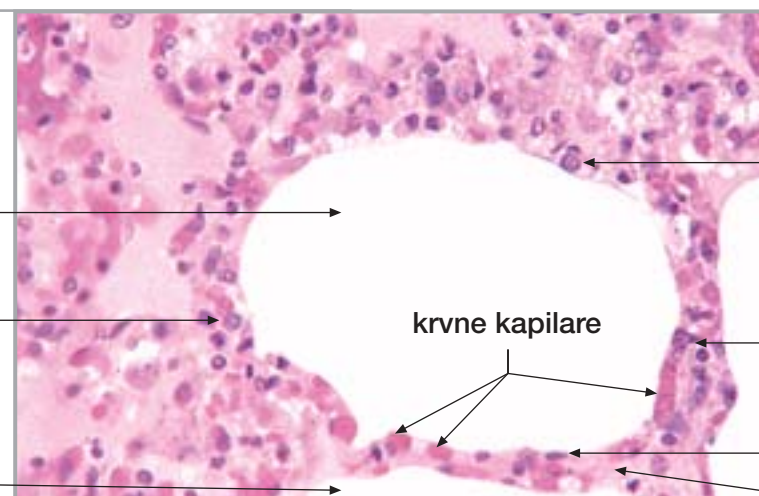
pneumocit I

lumen alveole

Sl. 213.

Pluća (alveola)

lumen alveole
pneumocit II
lumen alveole



krvne kapilare

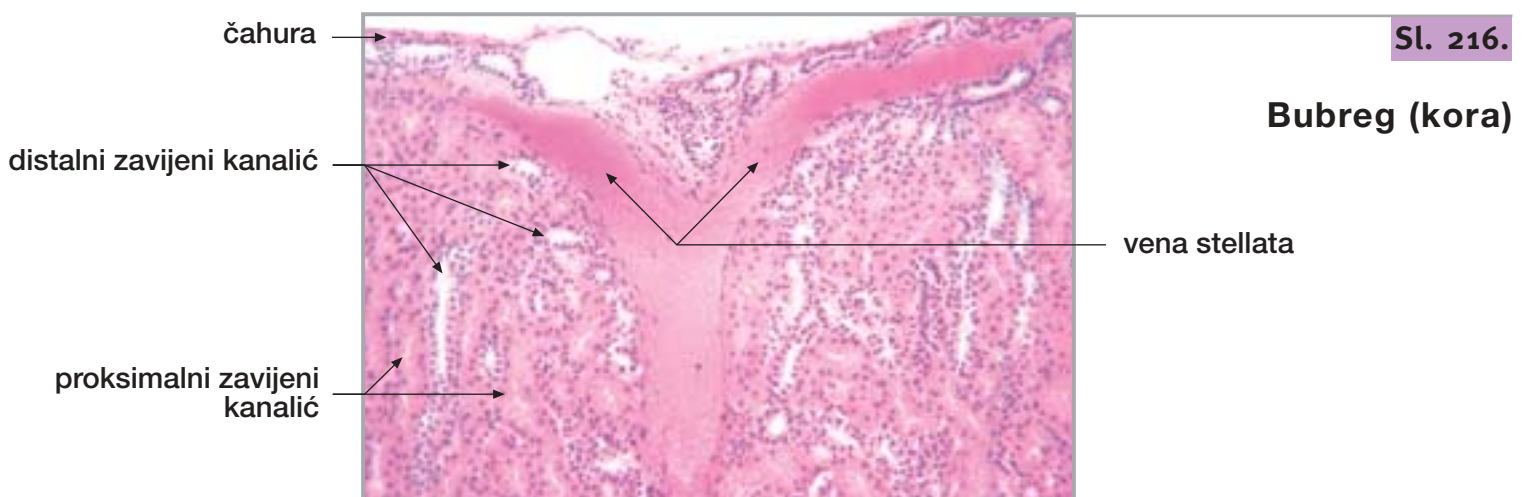
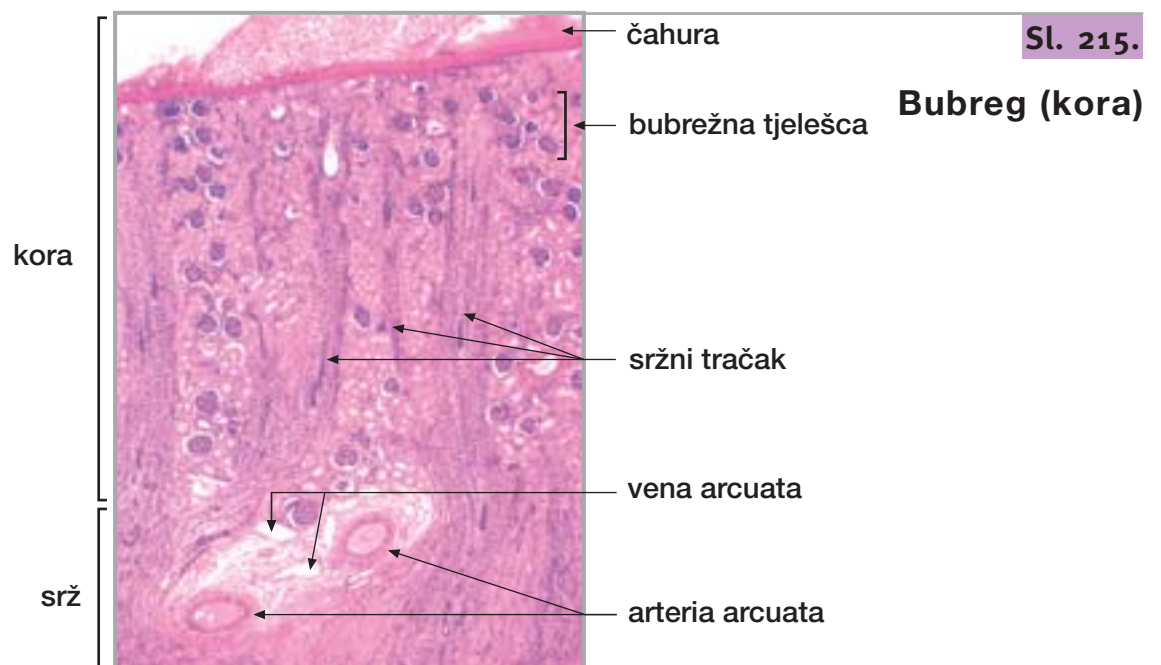
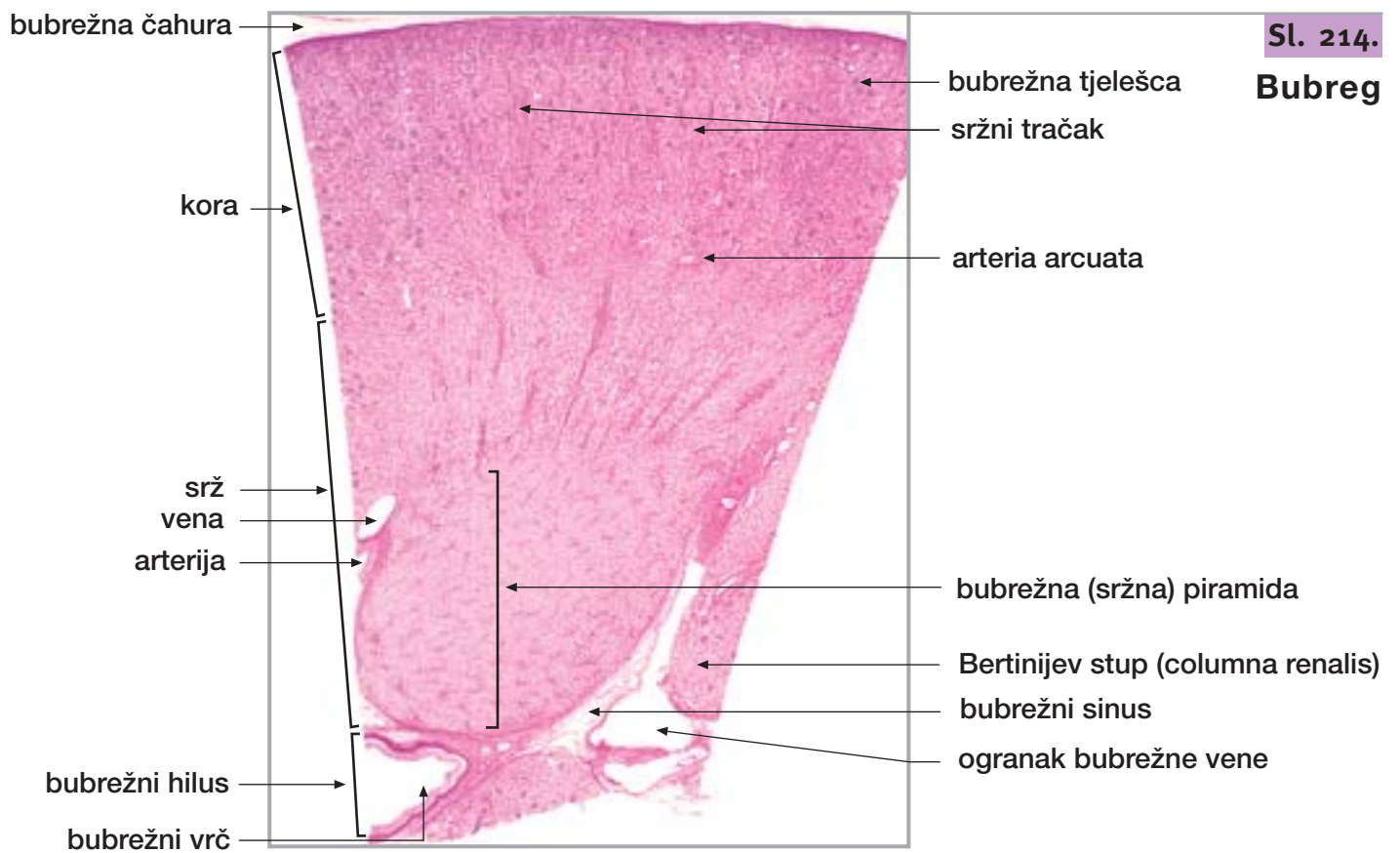
pneumocit II

interalveolarna pregrada

pneumocit I

interalveolarna pregrada

25. BUBREG, MOKRAĆOVOD I MOKRAĆNI MJEHUR



25. BUBREG, MOKRAĆOVOD I MOKRAĆNI MJEHUR

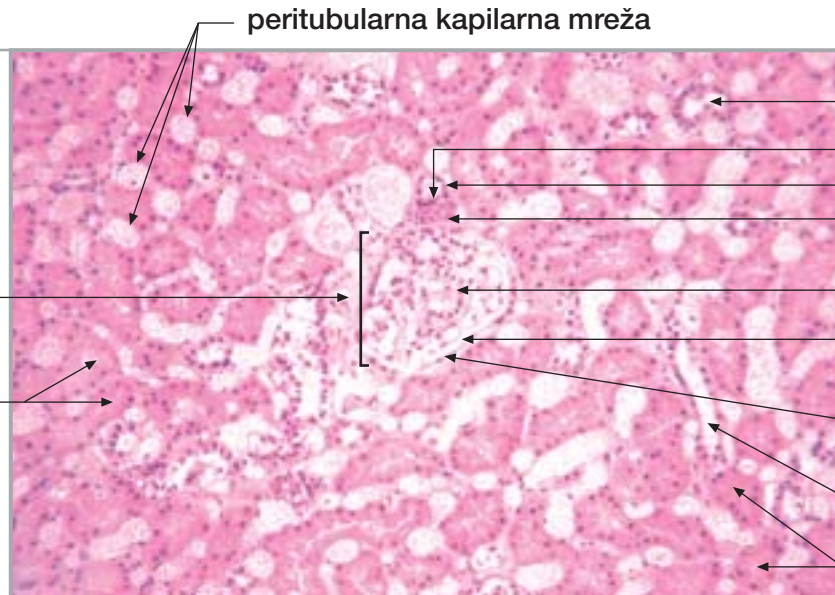
nastavak

Sl. 217.

**Bubreg
(hiperemična
kora)**

bubrežno tjelešce

proksimalni
zavijeni kanalić



peritubularna kapilarna mreža

distalni zavijeni kanalić

macula densa

distalni zavijeni kanalić

dovodna arteriola

glomerul

mokraćni
(interkapsularni) prostor

parijetalni list
Bowmanove čahure

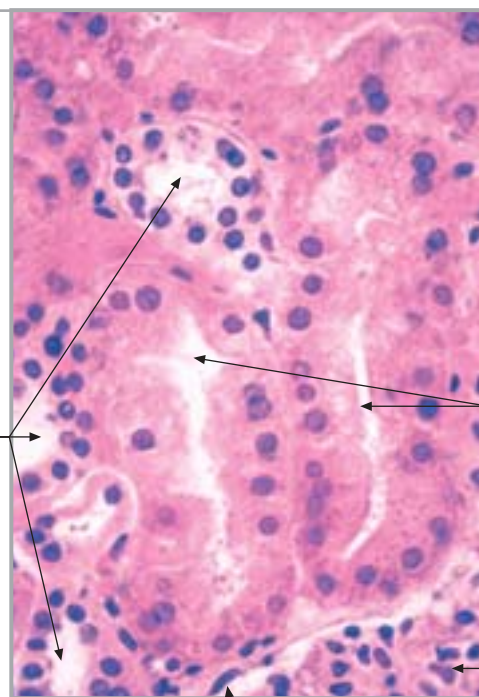
distalni zavijeni kanalić

proksimalni
zavijeni kanalić

Sl. 218.

Bubreg (kora)

distalni zavijeni kanalić



proksimalni zavijeni kanalić

glomerul (periferija)

parijetalni list Bowmanove čahure

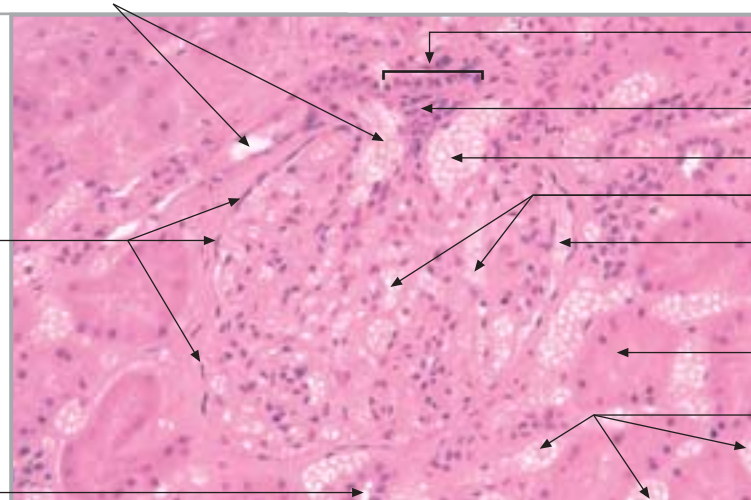
Sl. 219.

**Bubreg
(hiperemična kora)**

parijetalni list
Bowmanove čahure

distalni zavijeni kanalić

odvodna arteriola



macula densa

ekstraglomerularni
mezangij

dovodna arteriola

glomerularne kapilare

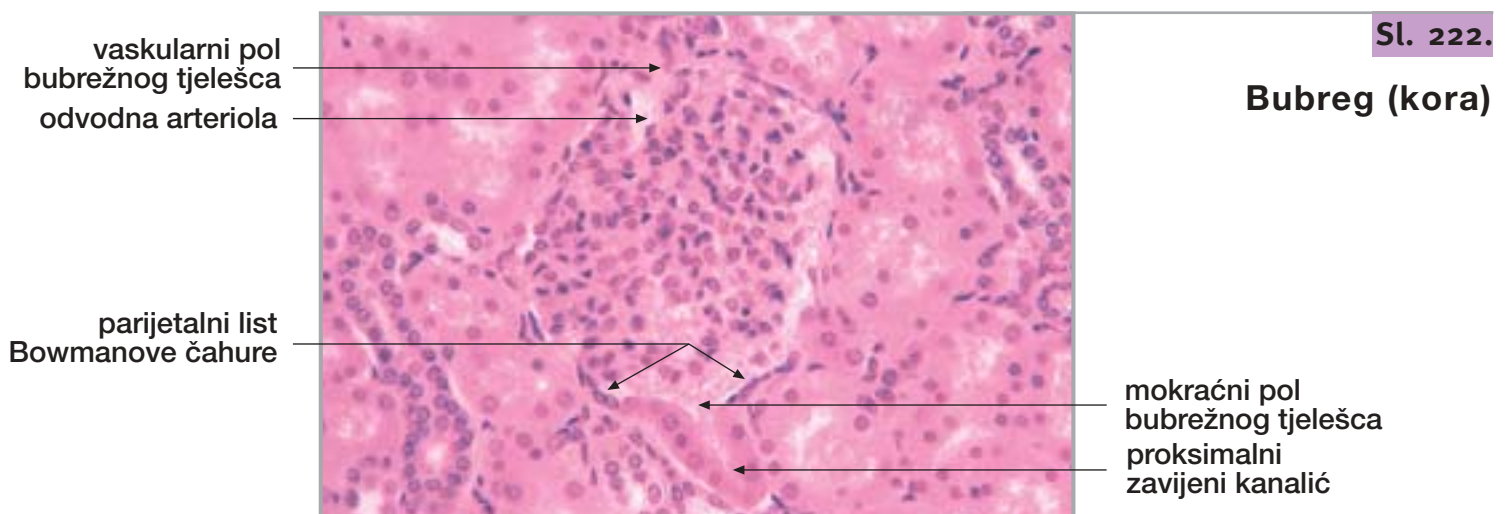
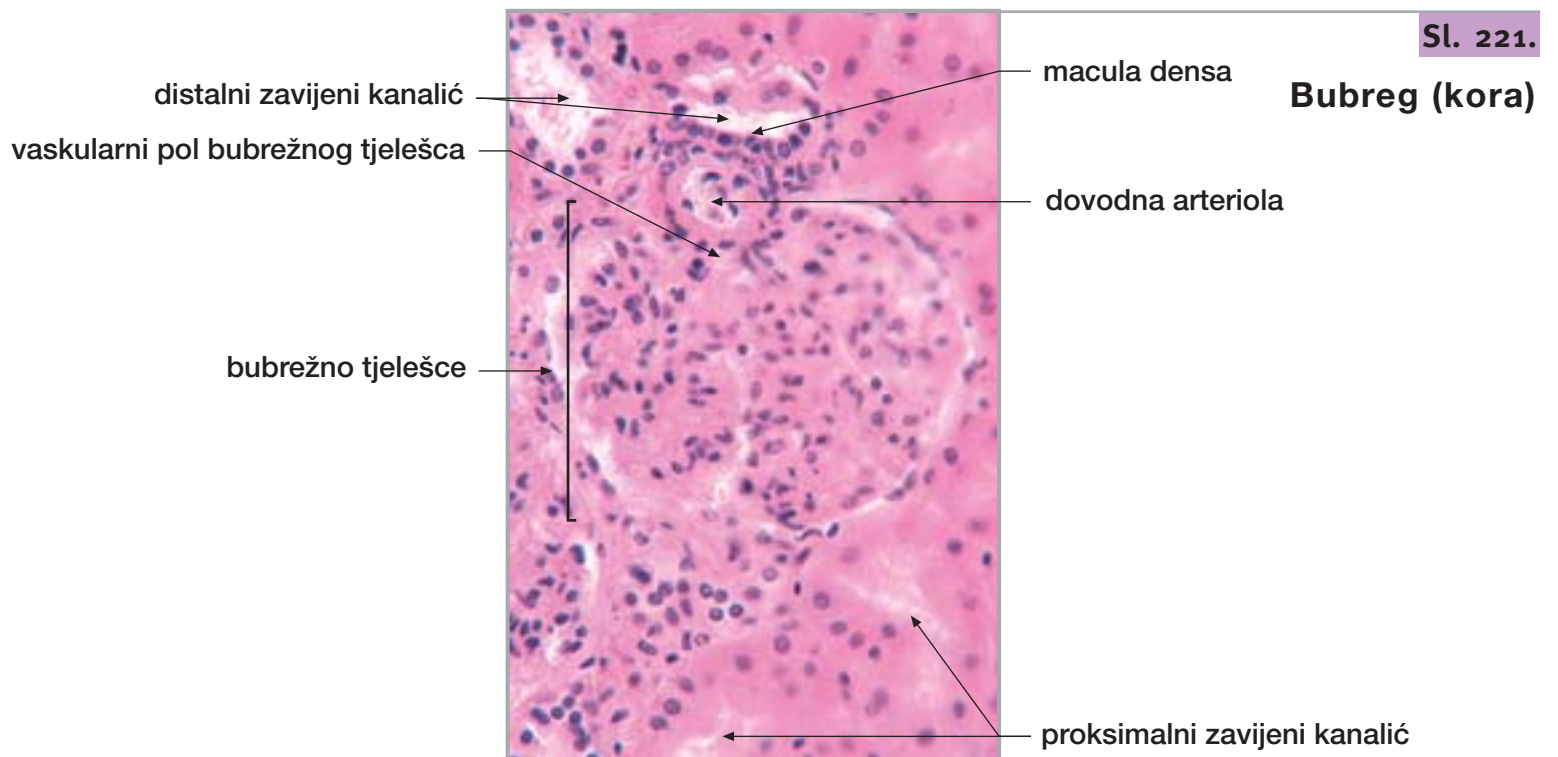
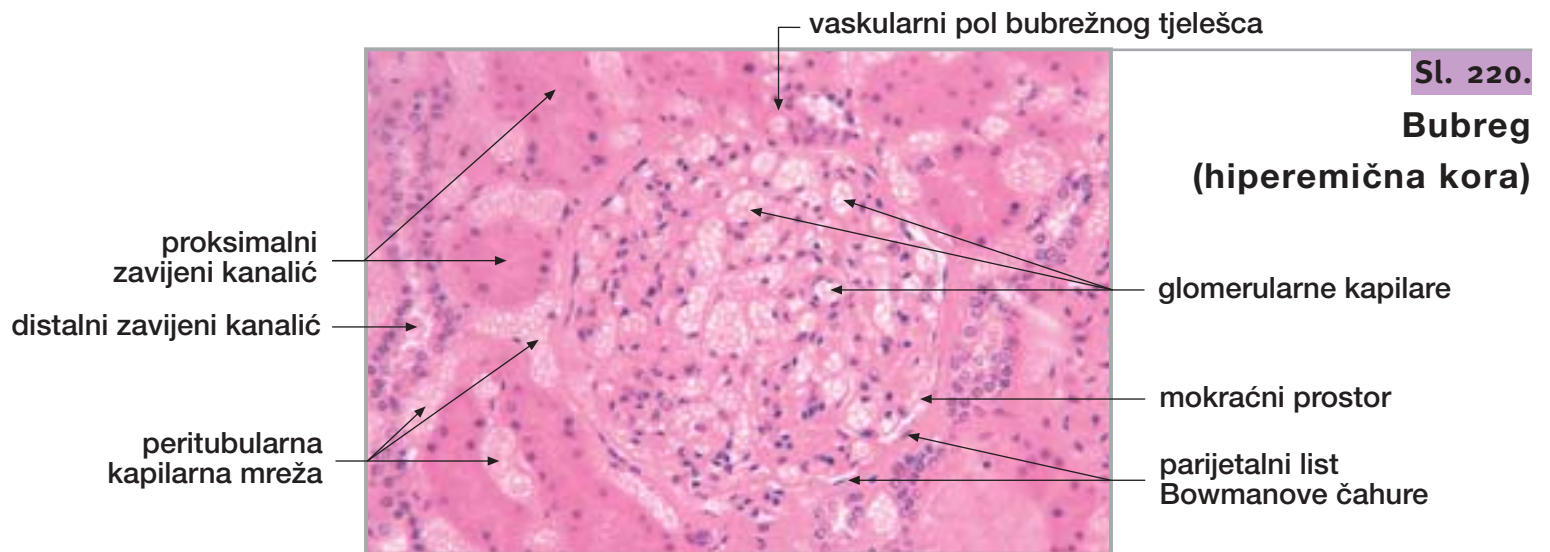
mokraćni prostor

proksimalni
zavijeni kanalići

peritubularna
kapilarna mreža

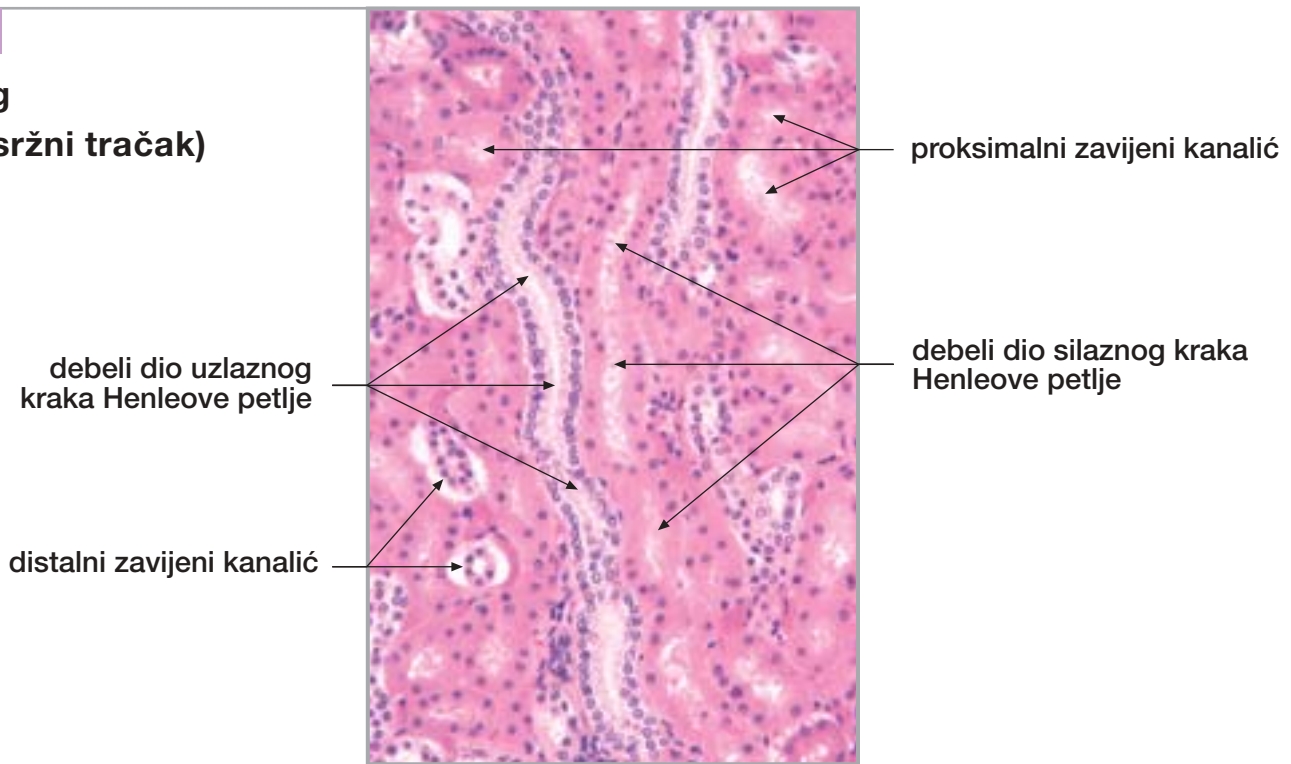
25. BUBREG, MOKRAĆOVOD I MOKRAĆNI MJEHUR

nastavak



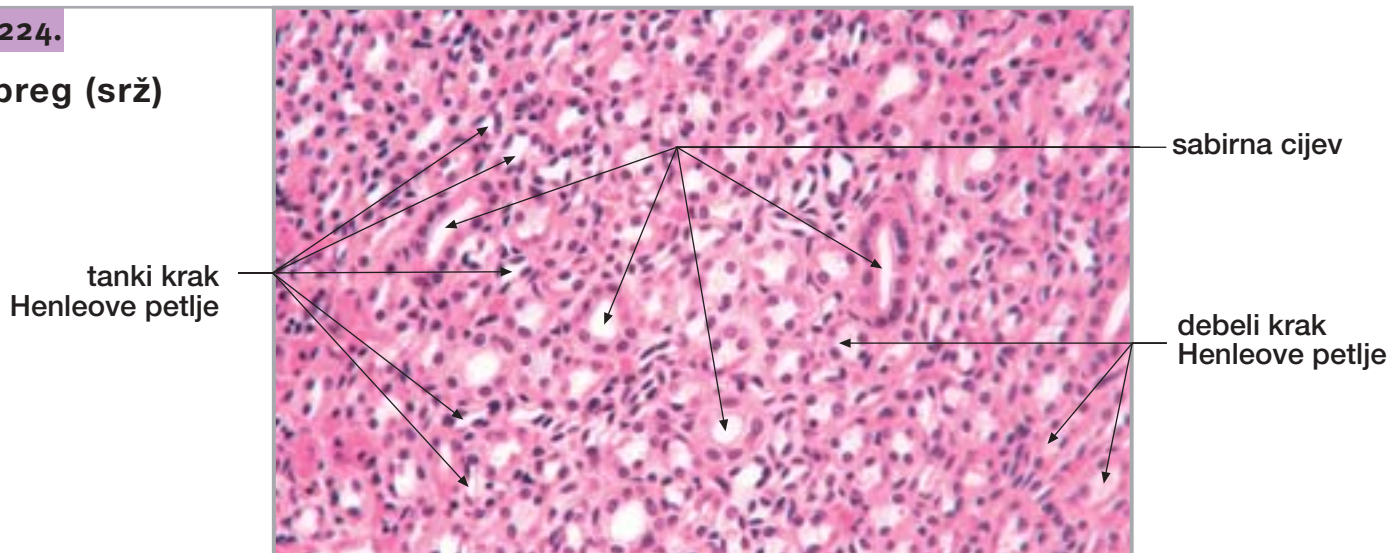
Sl. 223.

Bubreg
(kora, sržni tračak)



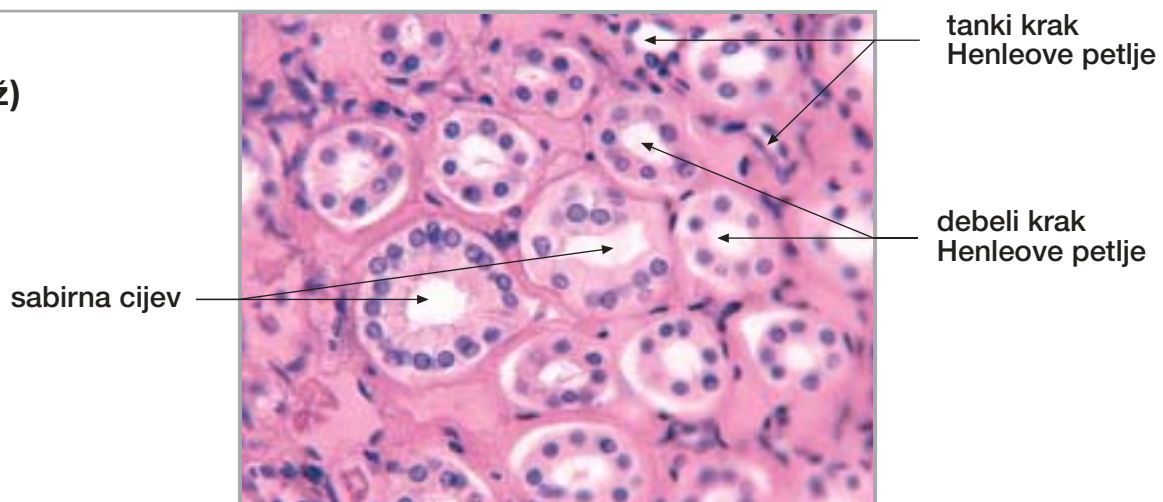
Sl. 224.

Bubreg (srž)



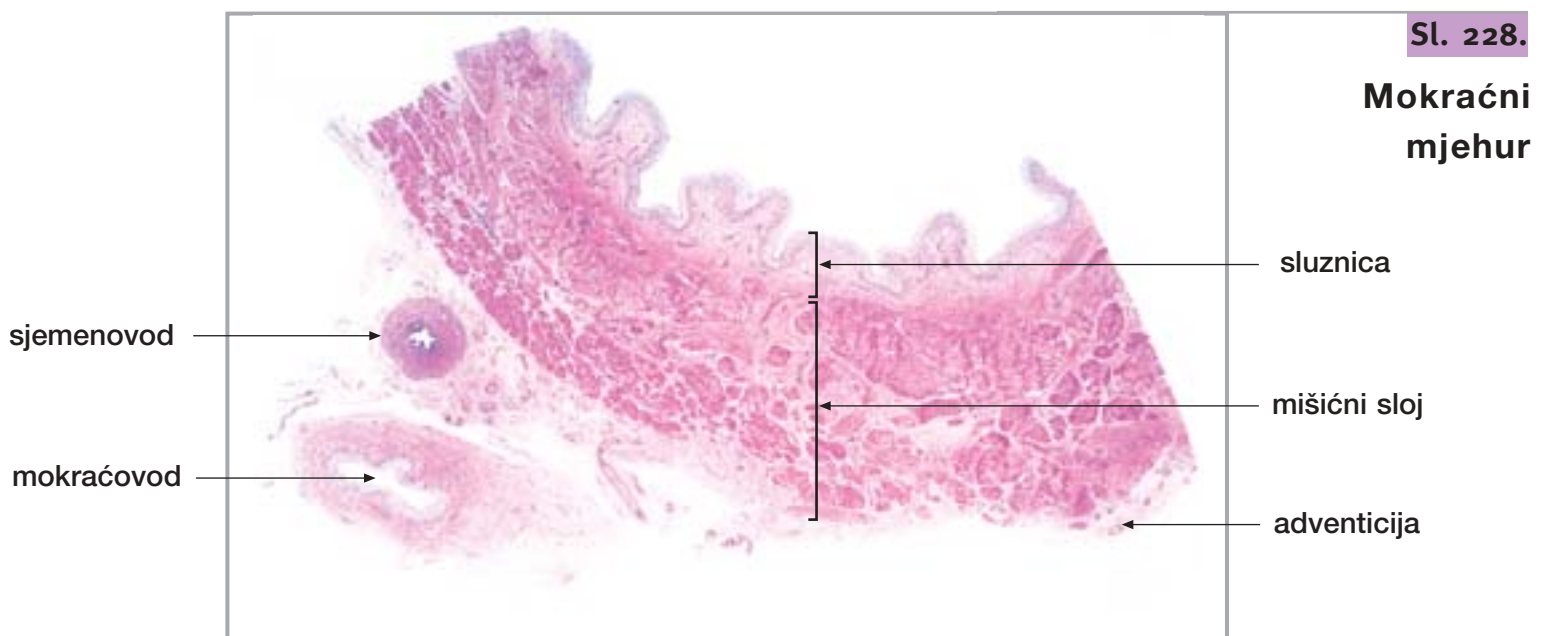
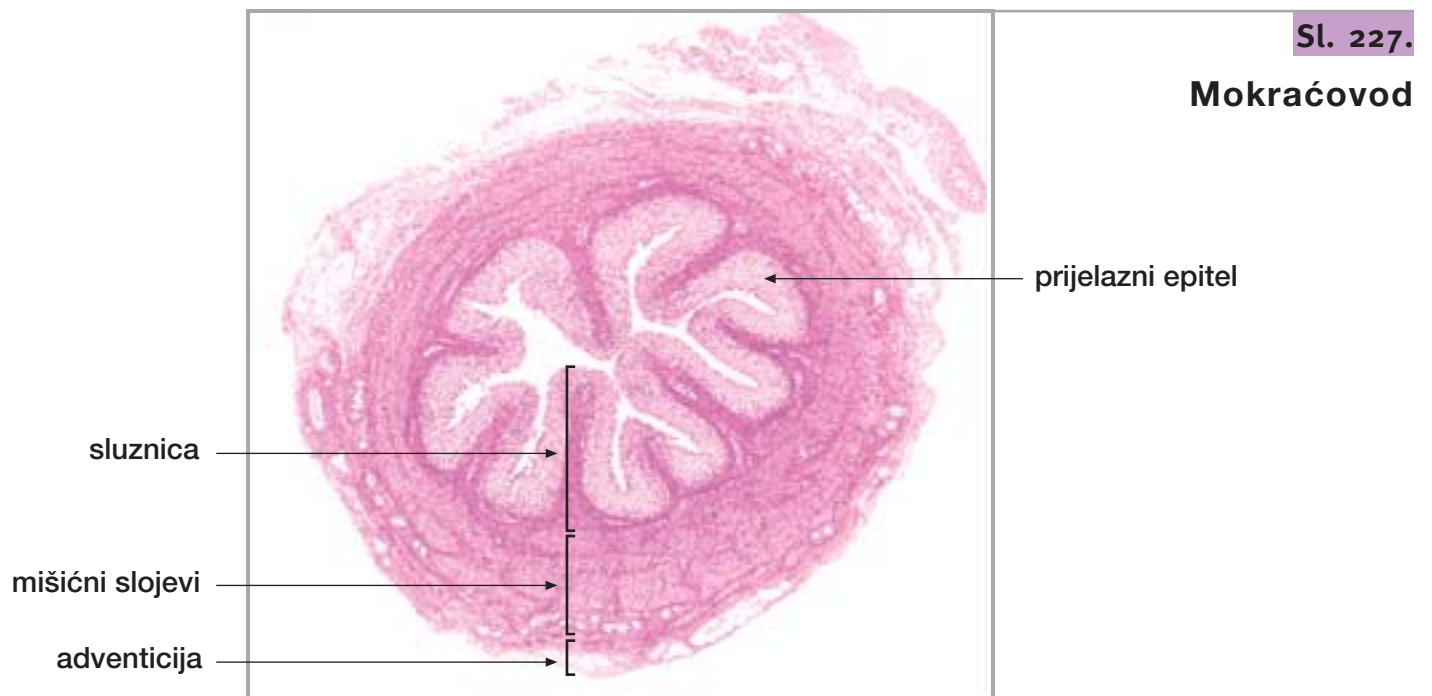
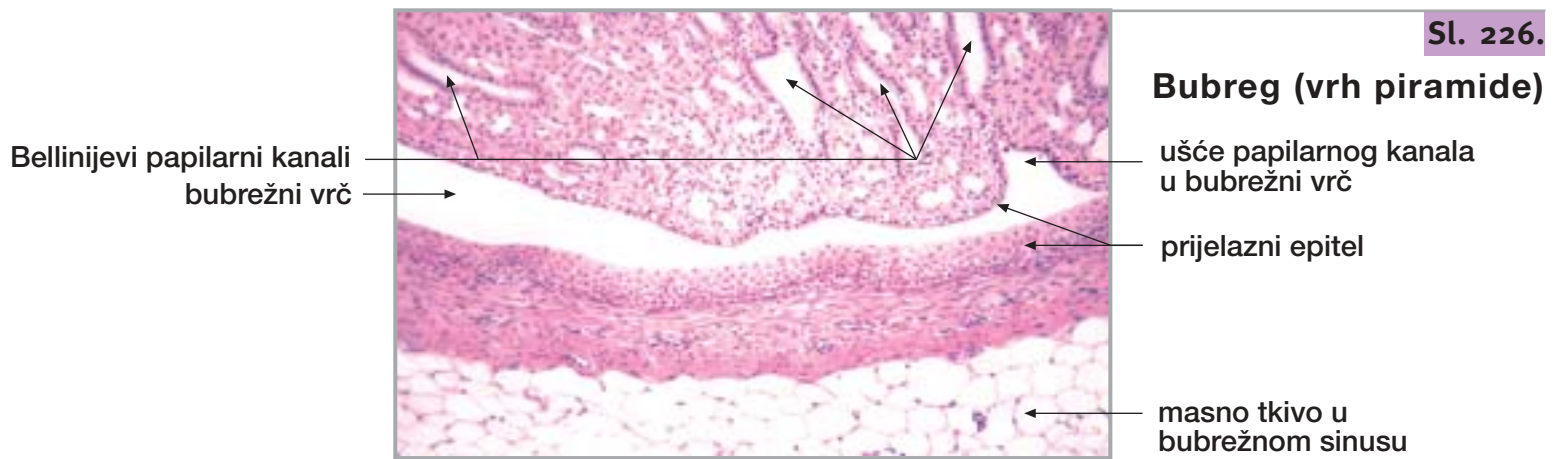
Sl. 225.

Bubreg (srž)



25. BUBREG, MOKRAĆOVOD I MOKRAĆNI MJEHUR

nastavak

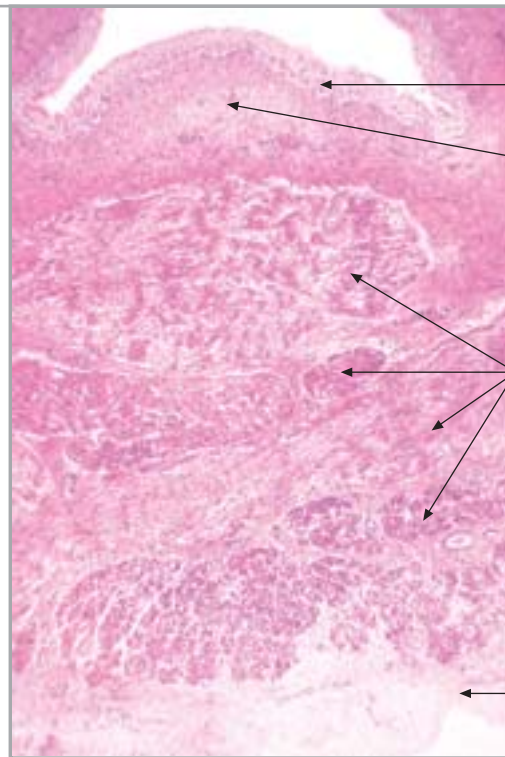


25. BUBREG, MOKRAĆOVOD I MOKRAĆNI MJEHUR

nastavak

Sl. 229.

Mokraćni mjehur



prijelazni epitel

lamina propria

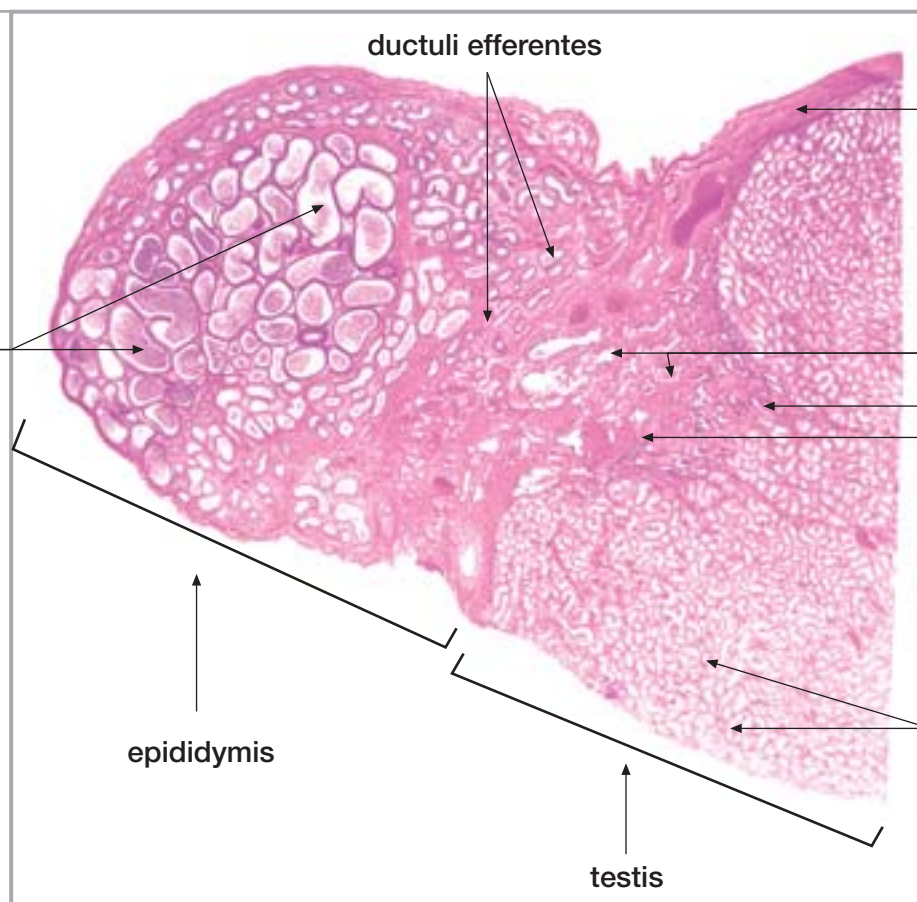
mišićni snopovi

adventicija

26. TESTIS I EPIDIDYMIS

Sl. 230.

Testis s epididimisom



ductuli efferentes

tunica albuginea

ductus epididymidis

rete testis

ravni kanalići
mediastinum testis

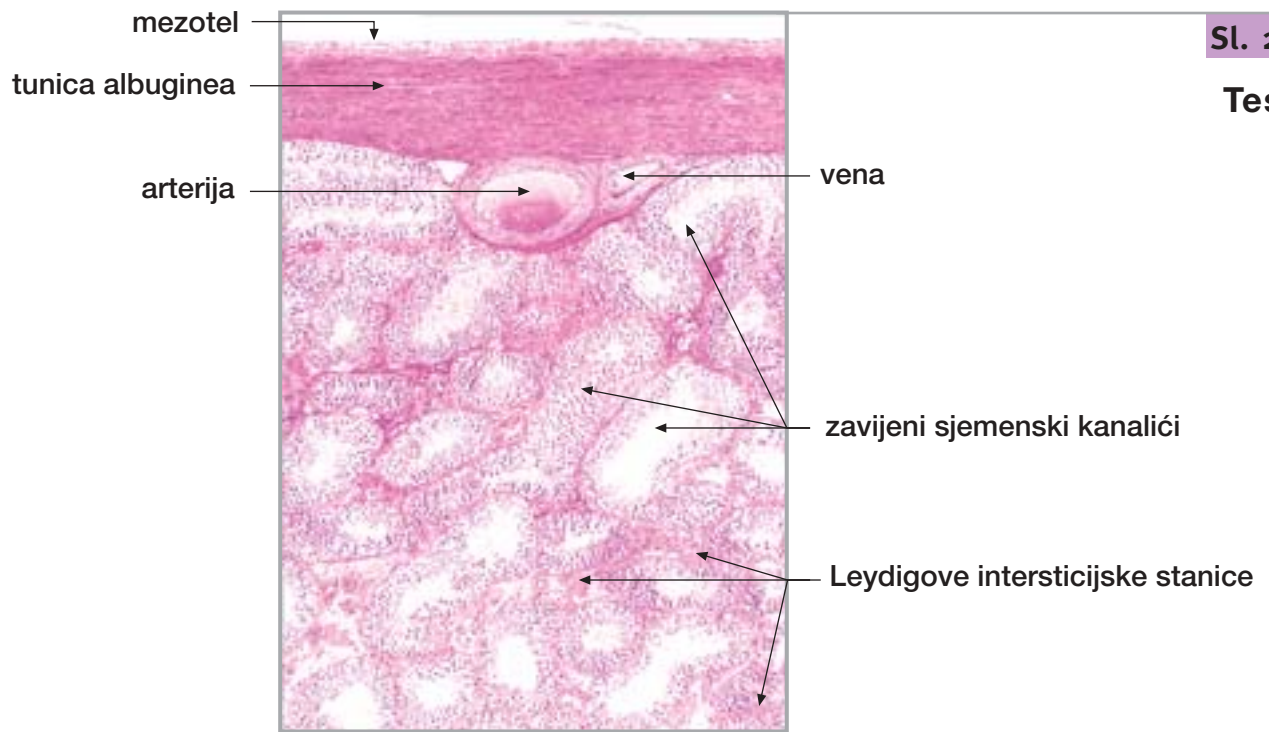
epididymis

zavijeni
sjemenski kanalići

testis

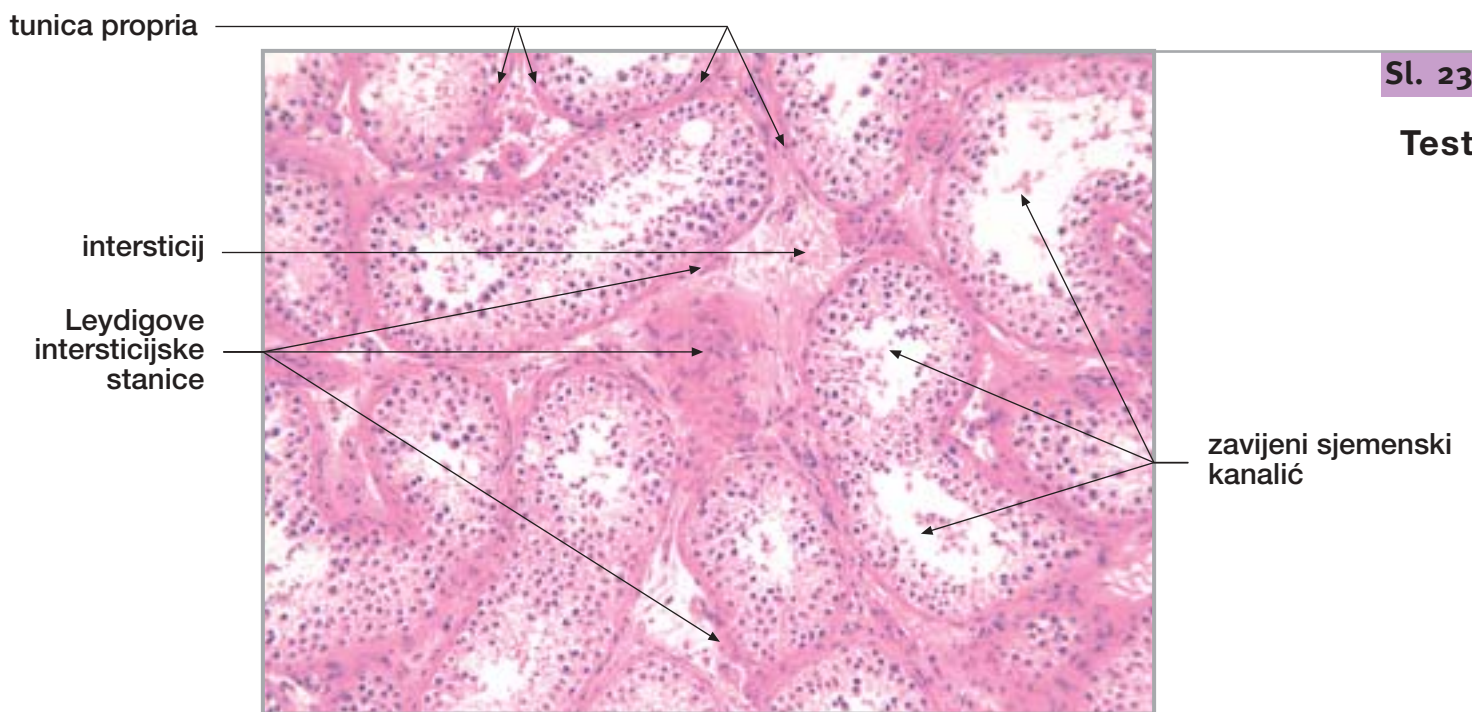
26. TESTIS I EPIDIDYMISS

nastavak



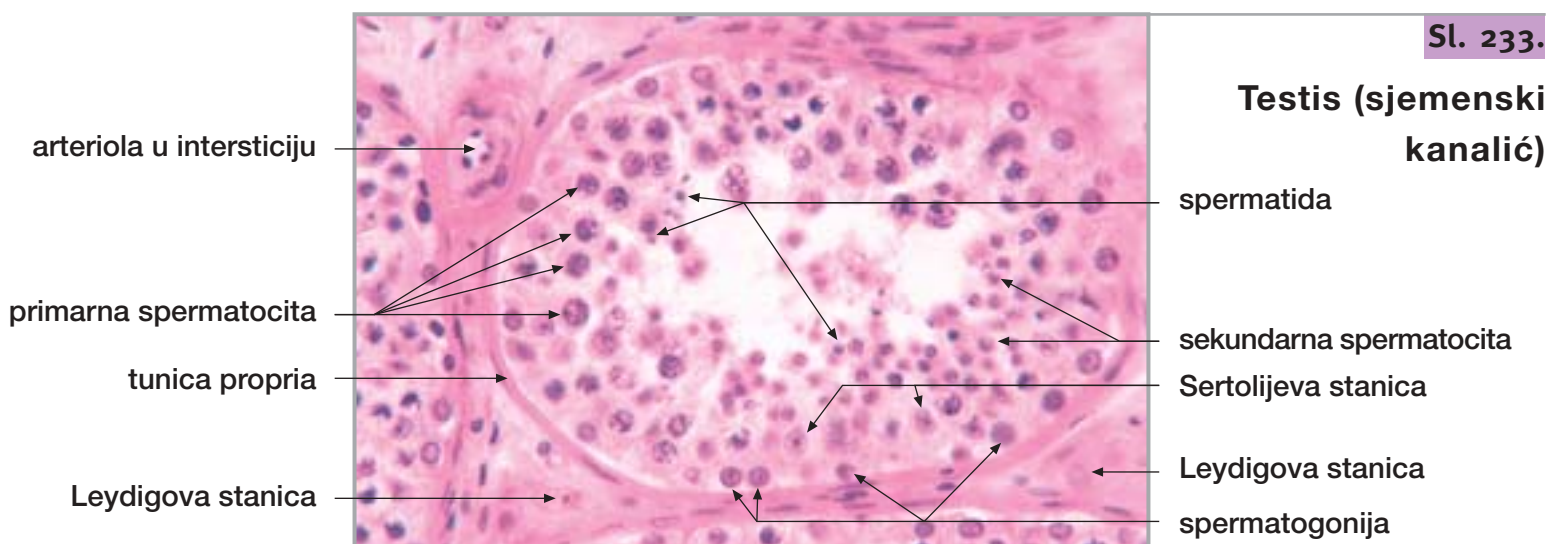
Sl. 231.

Testis



Sl. 232.

Testis



Sl. 233.

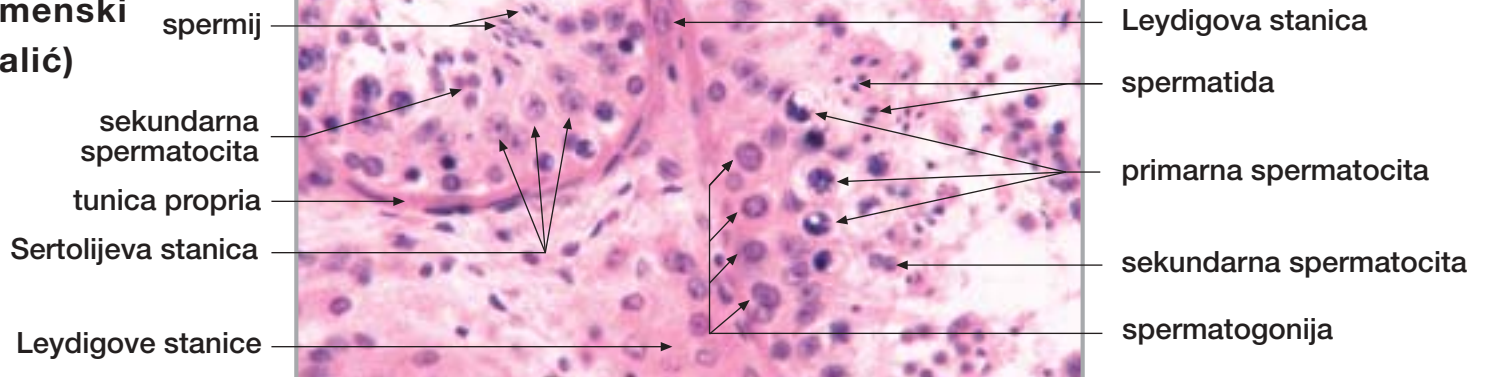
Testis (sjemenski kanalić)

26. TESTIS I EPIDIDYMISS

nastavak

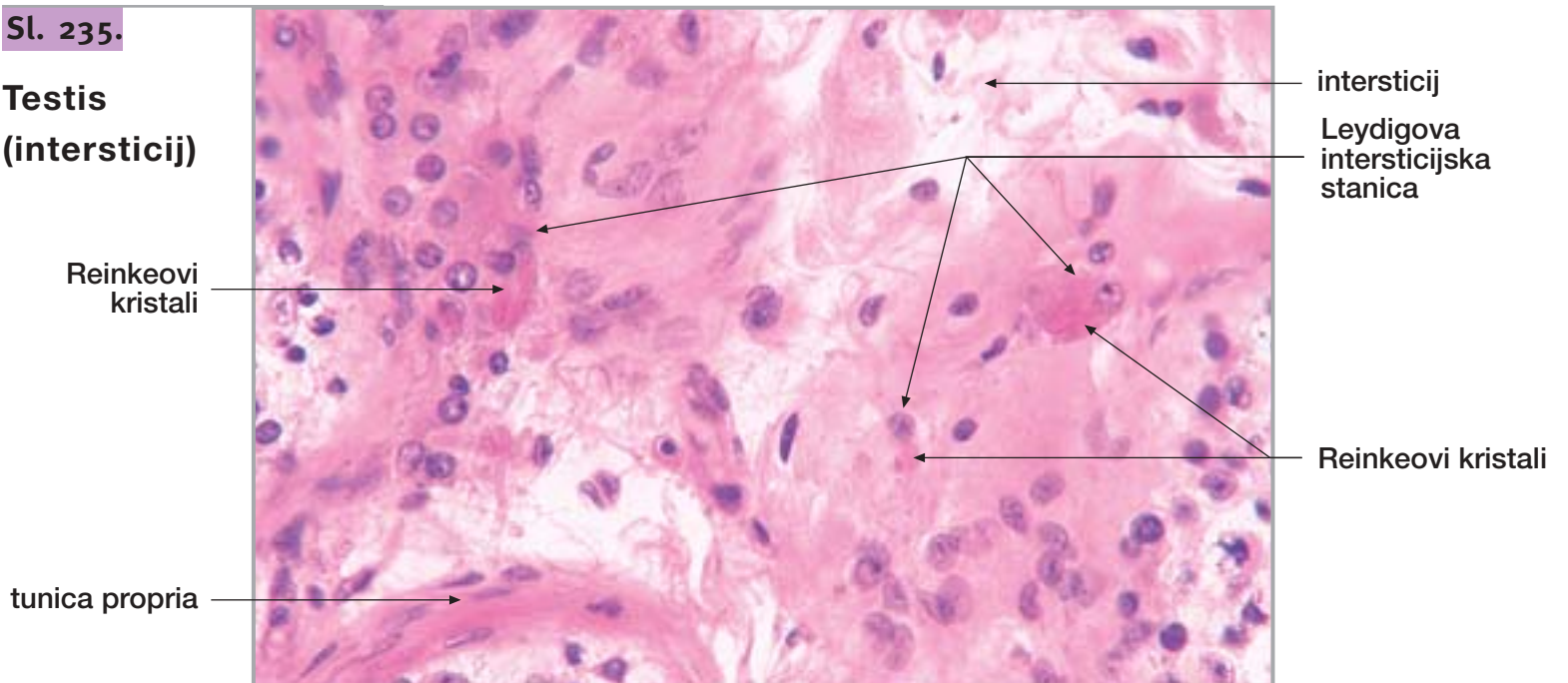
Sl. 234.

**Testis
(sjemenski
kanalić)**



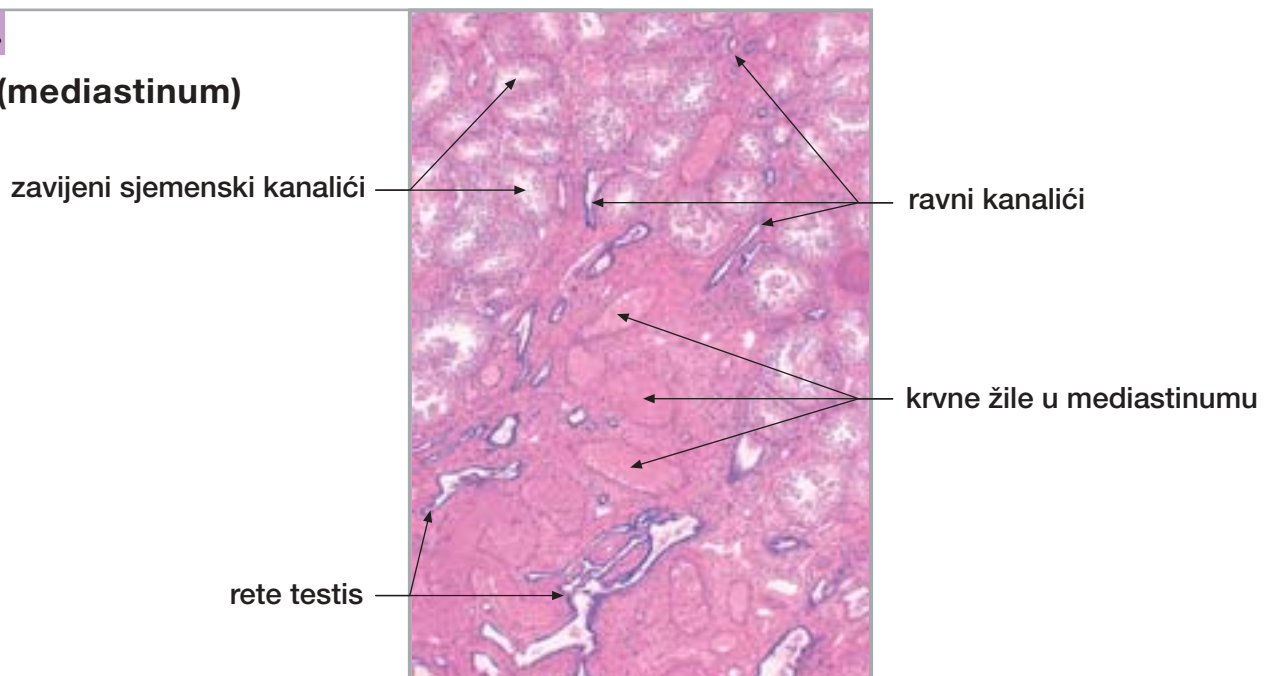
Sl. 235.

**Testis
(intersticij)**



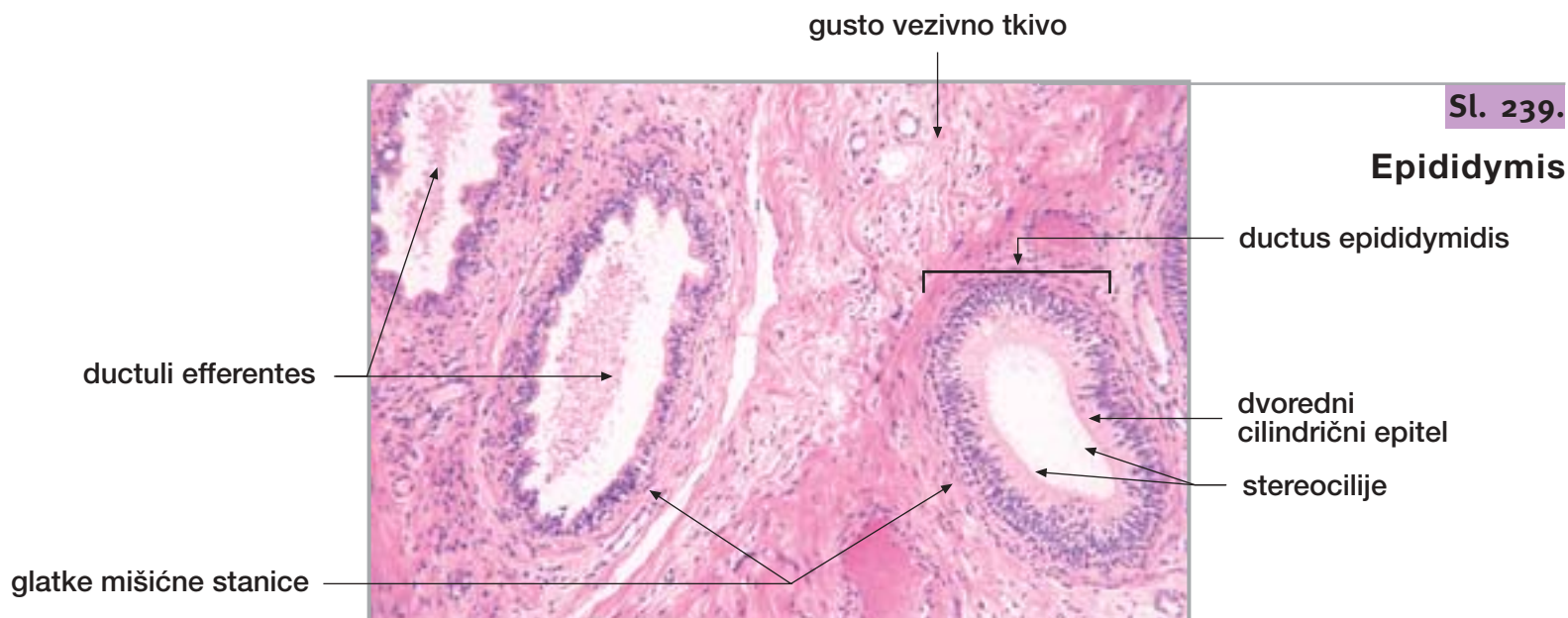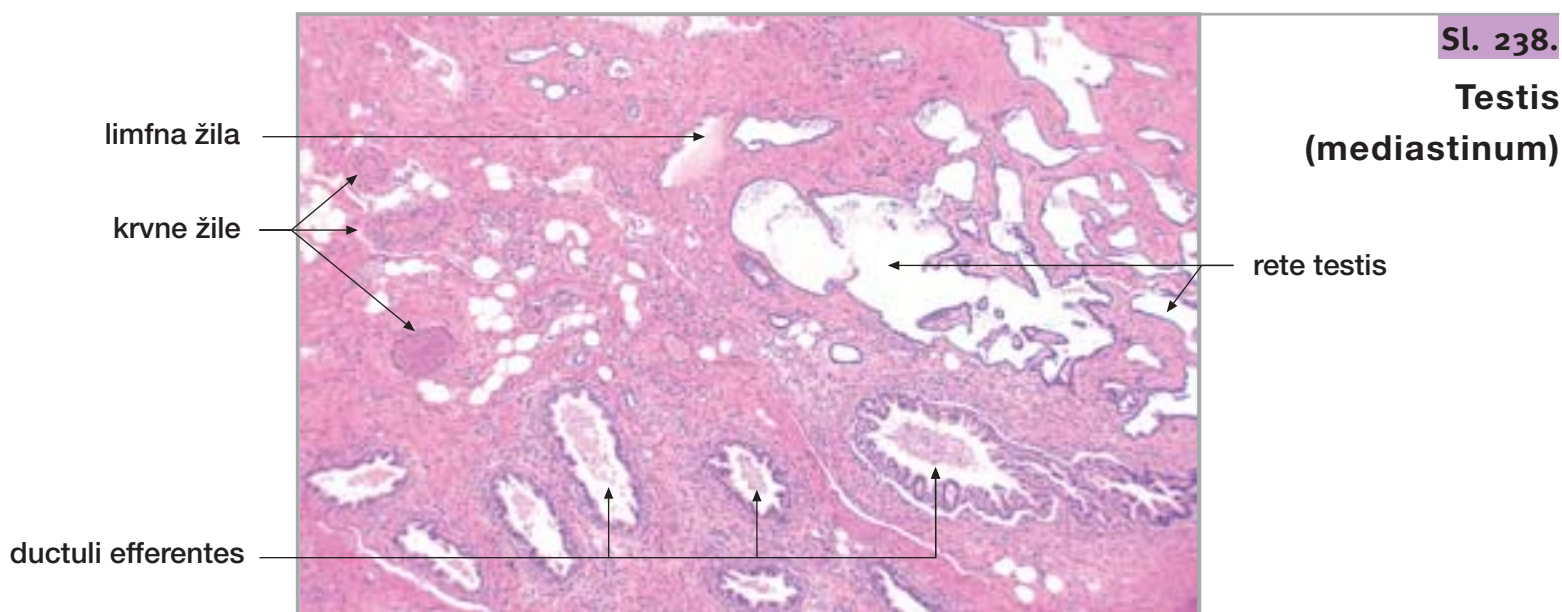
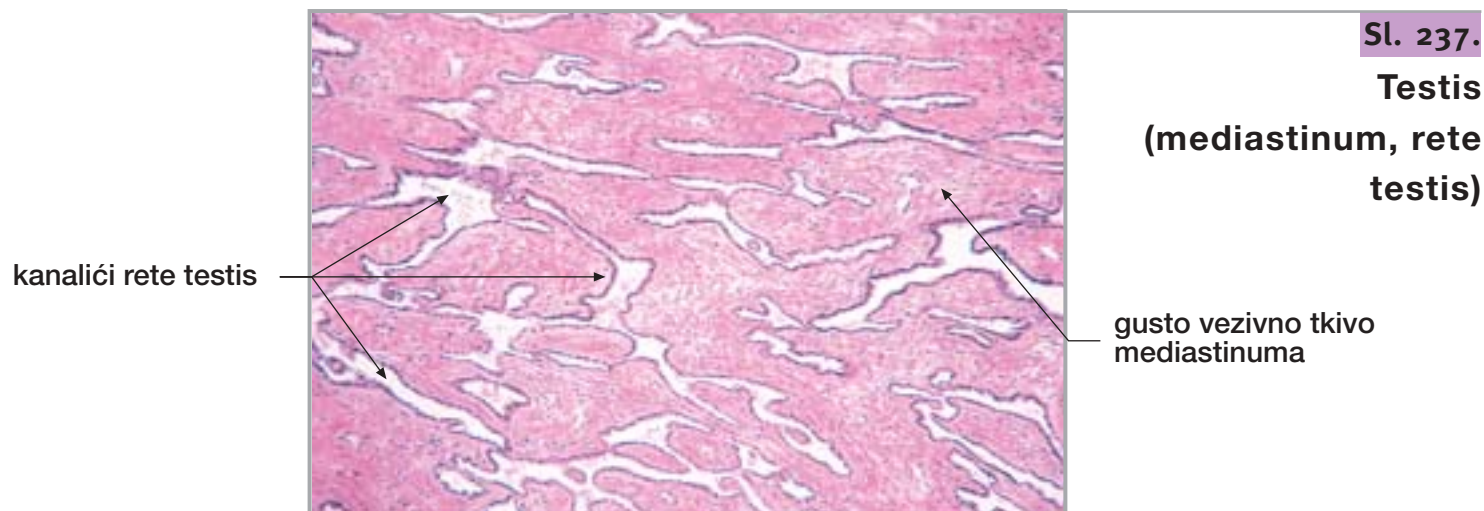
Sl. 236.

Testis (mediastinum)



26. TESTIS I EPIDIDYMIS

nastavak

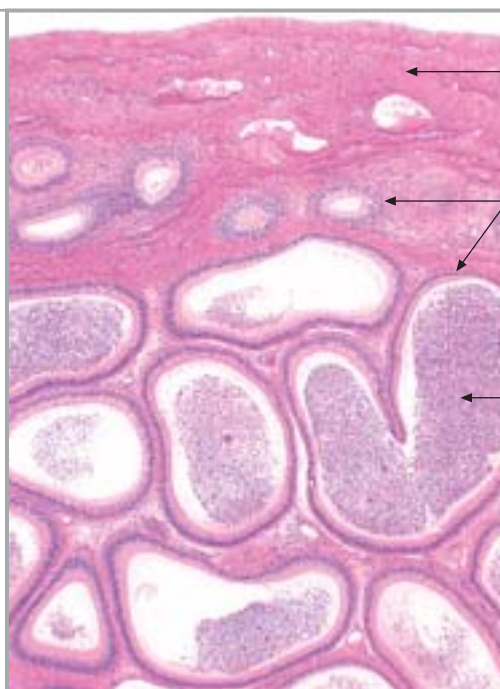


26. TESTIS I EPIDIDYMIS

nastavak

Sl. 240.

Epididymis



vezivna ovojnica

ductus epididymidis

spermiji pohranjeni u proširenim kanalićima

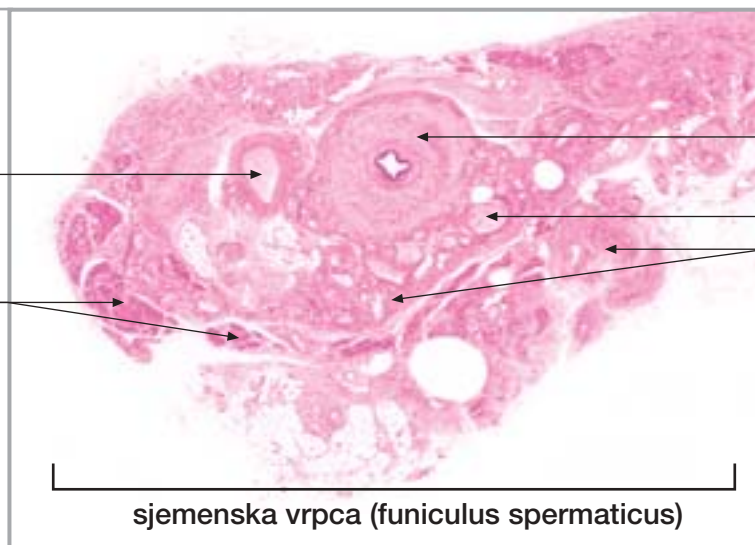
27. SJEMENOVOD, SJEMENSKI MJEHURIĆ I PROSTATA

Sl. 241.

Sjemenovod

arteria testicularis

musculus cremaster



sjemenovod

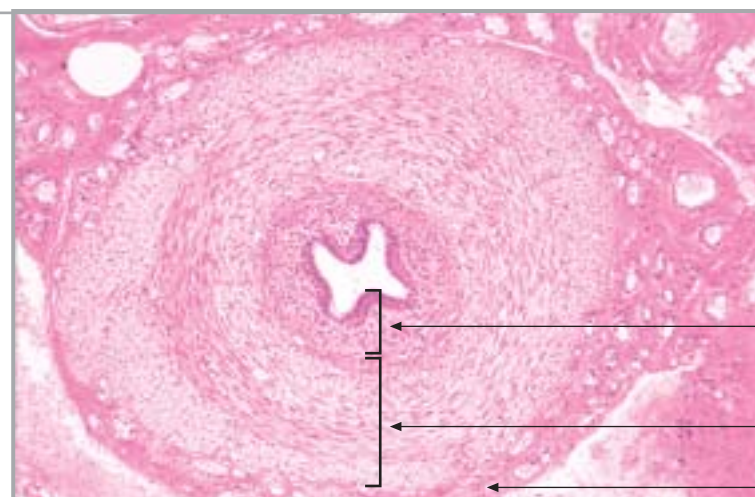
živac

plexus pampiniformis

sjemenska vrpca (funiculus spermaticus)

Sl. 242.

Sjemenovod



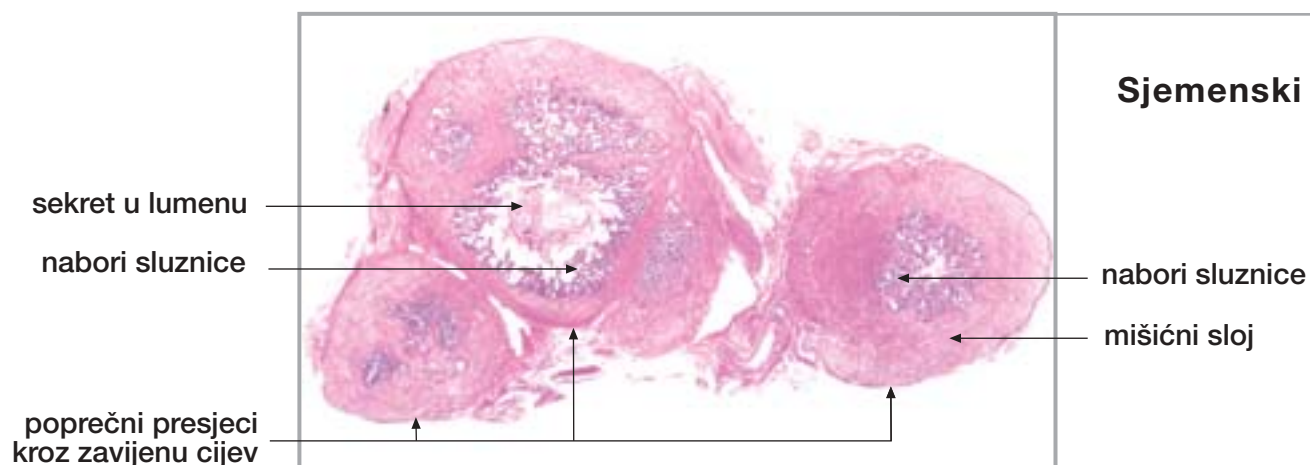
sluznica

mišićni slojevi

adventicija

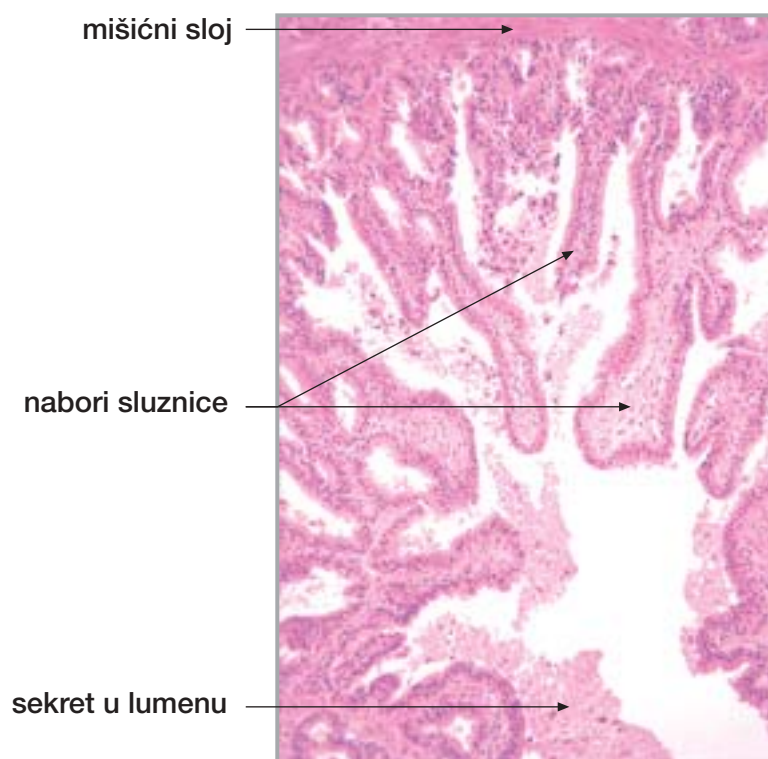
27. SJEMENOVOD, SJEMENSKI MJEHURIĆ I PROSTATA

nastavak



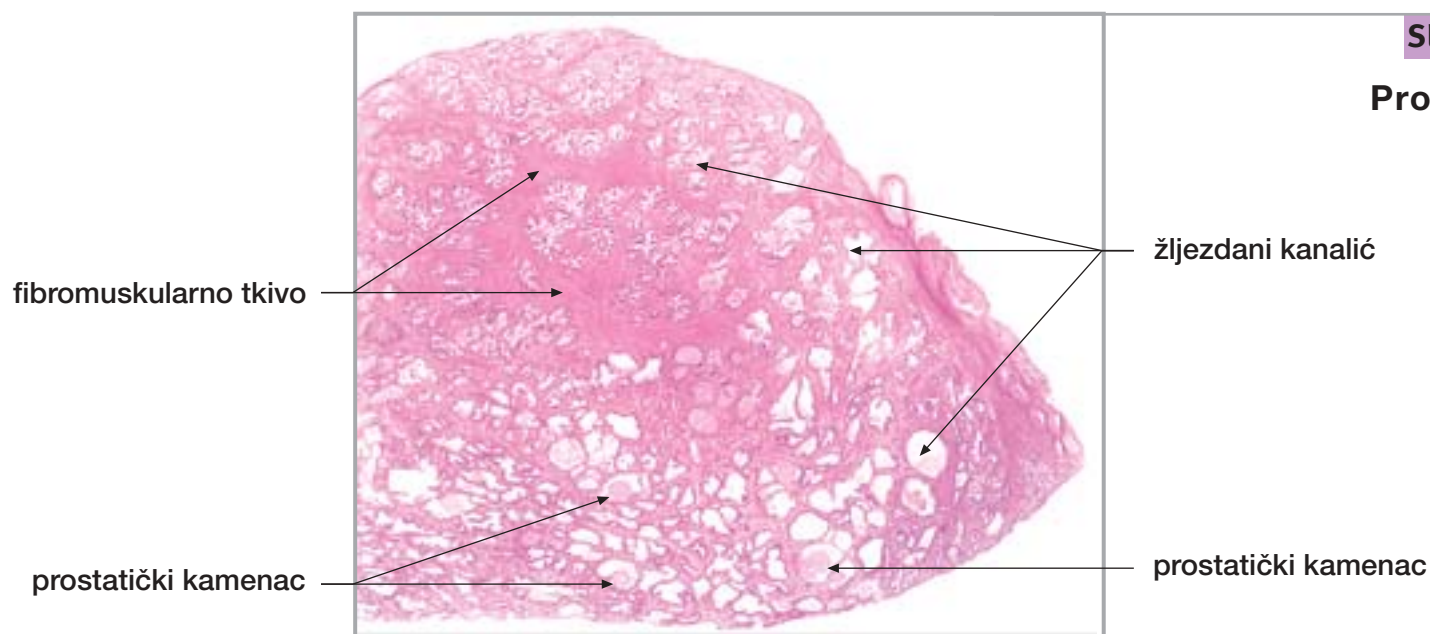
Sl. 243.

Sjemenski mjehurić



Sl. 244.

Sjemenski mjehurić (sluznica)



Sl. 245.

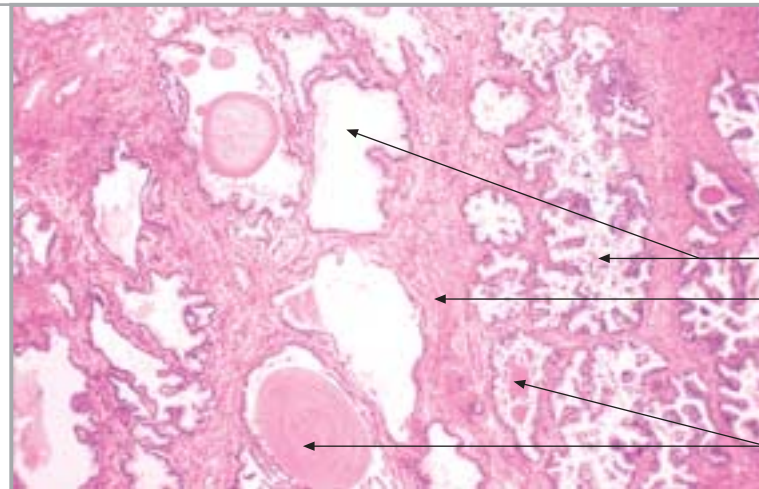
Prostata

27. SJEMENOVOD, SJEMENSKI MJEHURIĆ I PROSTATA

nastavak

Sl. 246.

Prostata



žljezdani kanalić
fibromuskularno tkivo
prostatički kamenac

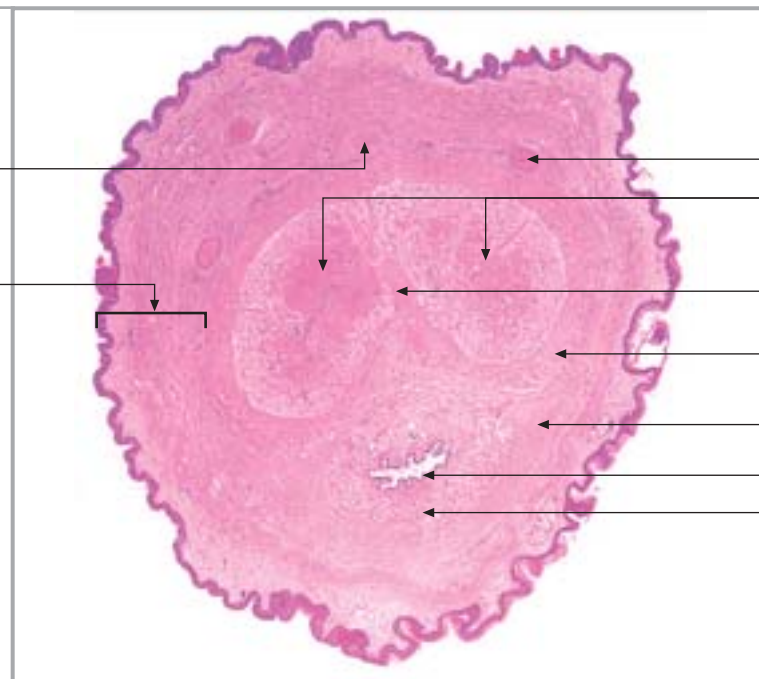
28. PENIS

Sl. 247.

Penis

vena dorsalis
penis profunda

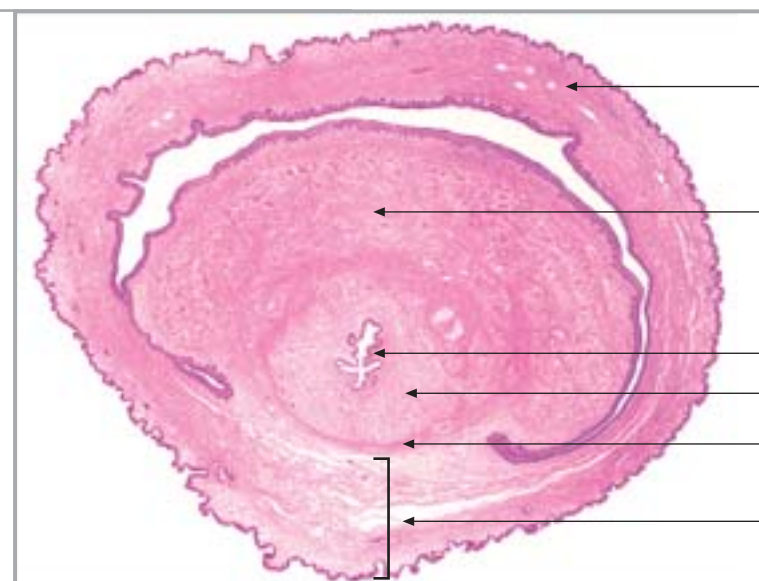
koža



arteria dorsalis penis
corpora cavernosa penis
septum pectiniforme
tunica albuginea
kavernoznih tijela
tunica albuginea
spongioznog tijela
mokraćna cijev
corpus spongiosum urethrae

Sl. 248.

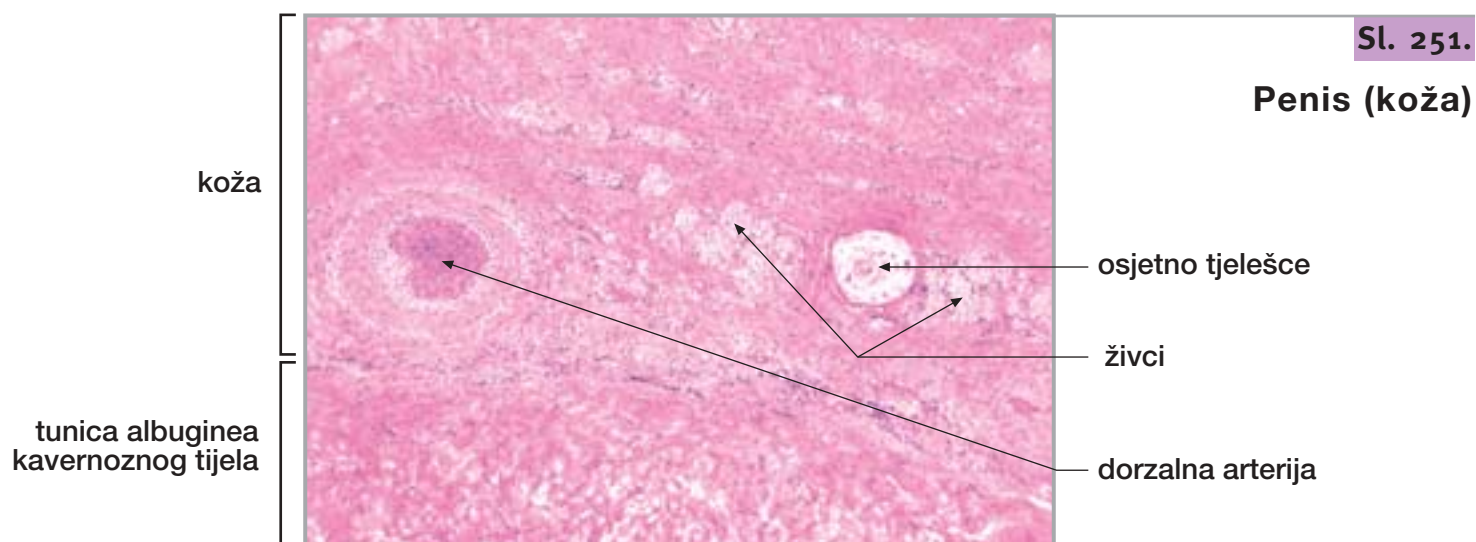
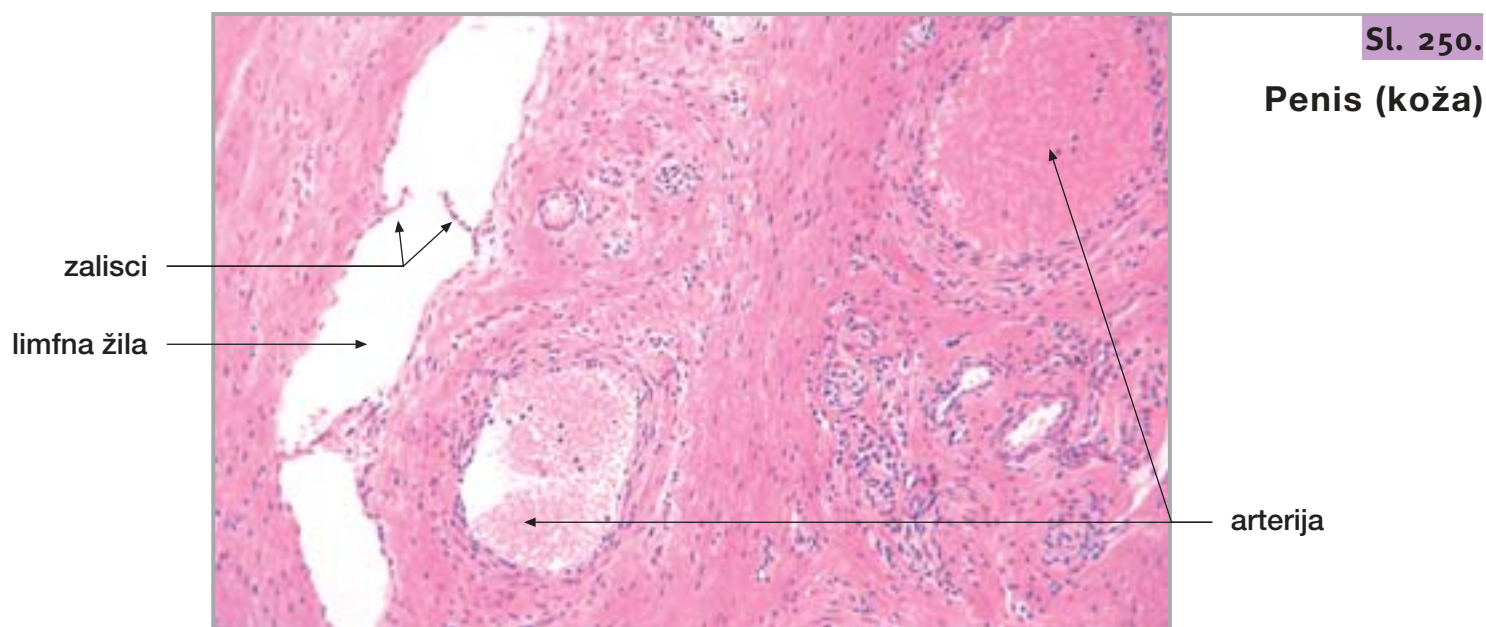
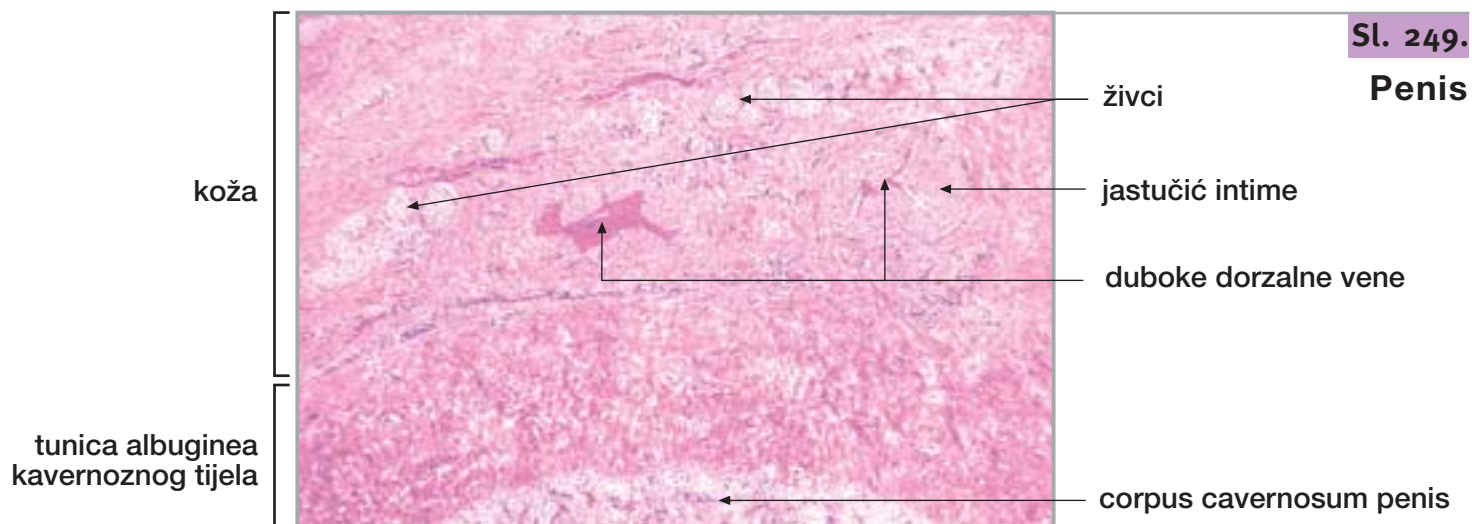
Penis (glans penis
s prepucijem)



prepucij
glans penis
(kavernožno tijelo)
mokraćna cijev
corpus spongiosum urethrae
tunica albuginea
spongioznog tijela
koža

28. PENIS

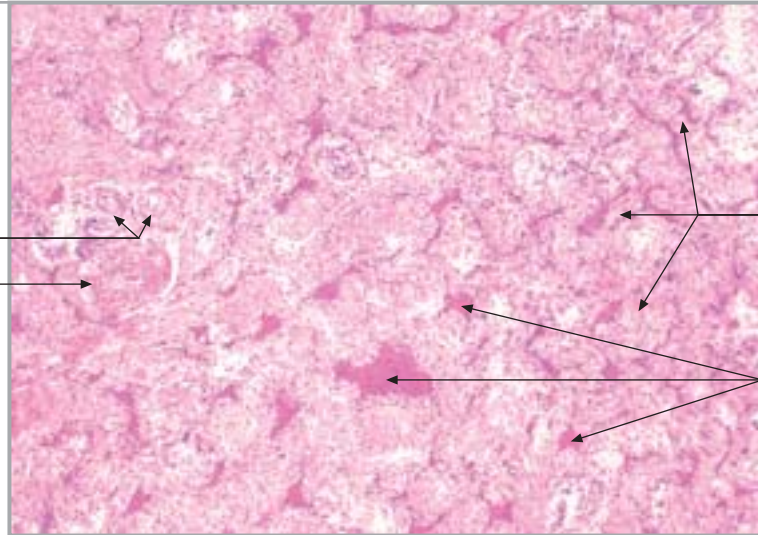
nastavak



Sl. 252.

Penis (corpus cavernosum penis)

arteria helicina
arteria profunda penis



trabekula

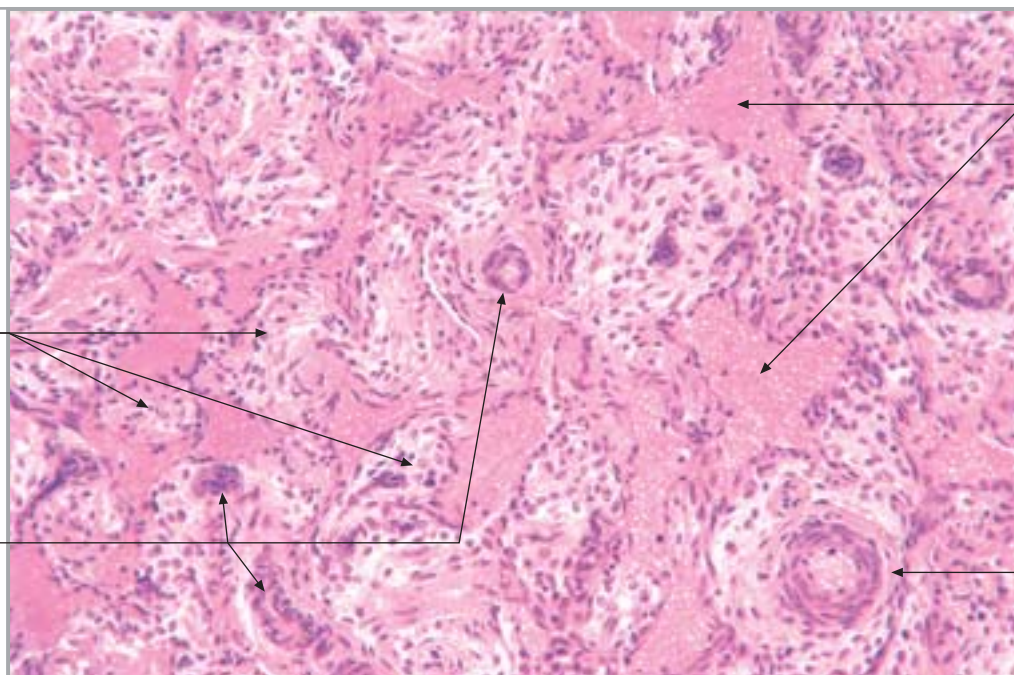
kaverna

Sl. 253.

Penis (corpus cavernosum penis)

trabekula

arteria helicina



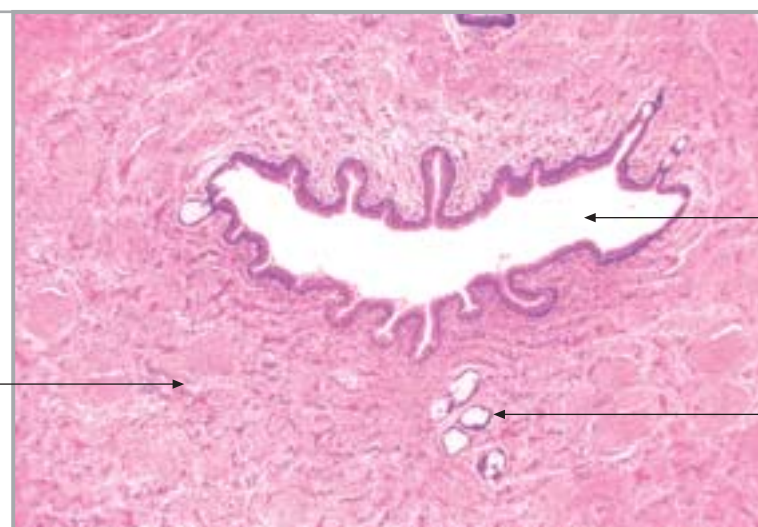
kaverna

arteria profunda penis

Sl. 254.

Penis (corpus spongiosum urethrae)

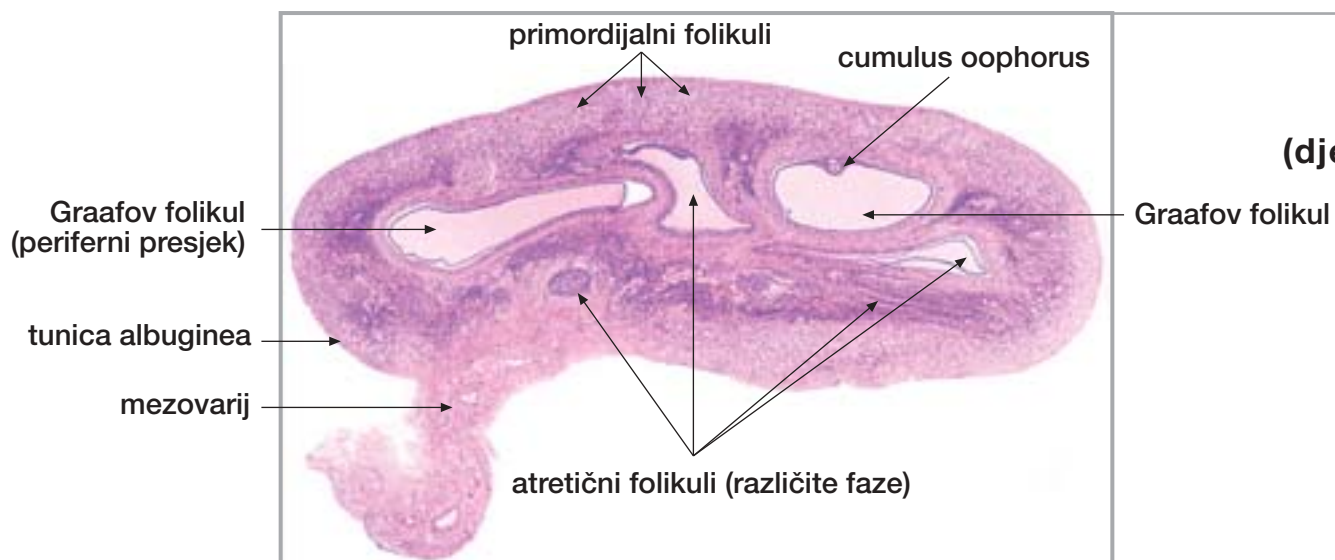
corpus spongiosum urethrae



mokraćna cijev

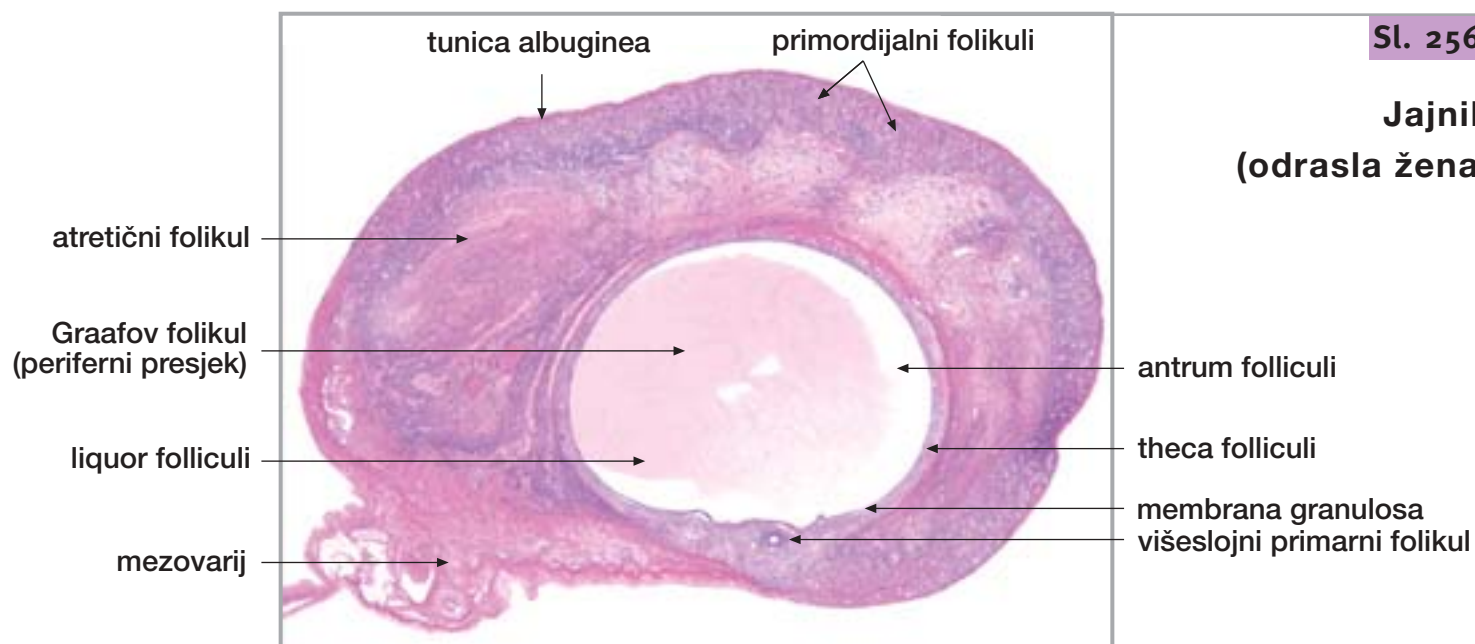
gl. urethralis
(Littreova žlijezda)

29. JAJNIK I JAJOVOD



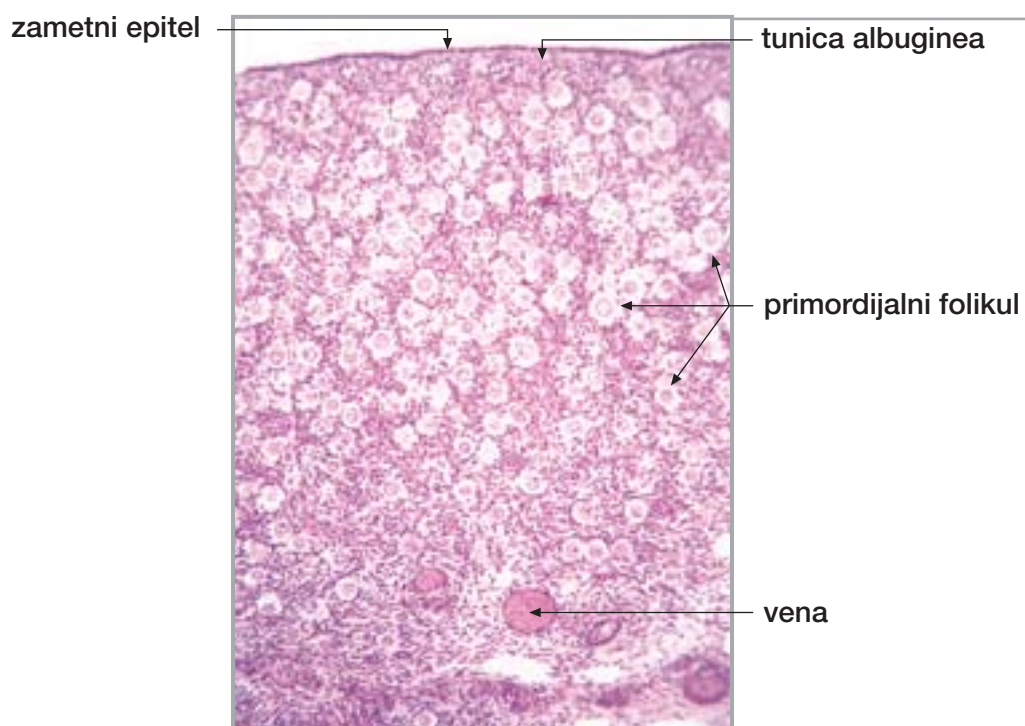
Sl. 255.

**Jajnik
(djevojčica)**



Sl. 256.

**Jajnik
(odrasla žena)**



Sl. 257.

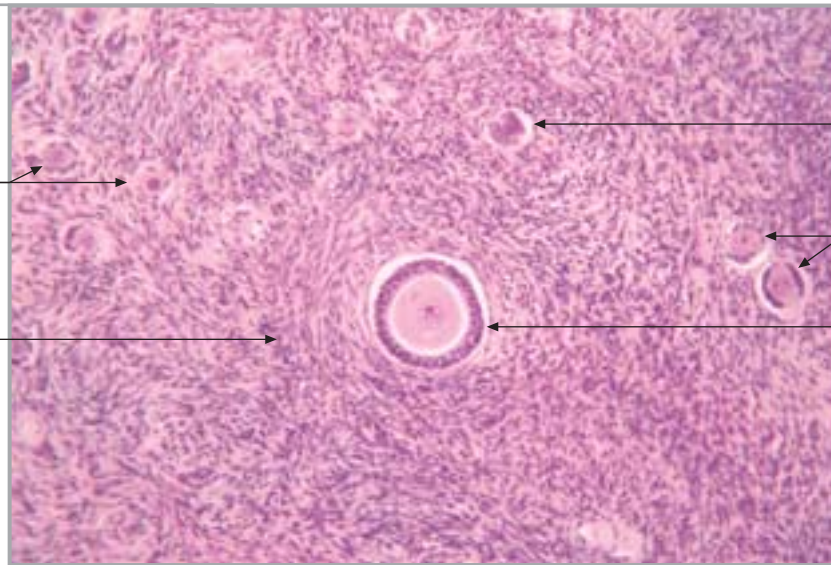
Jajnik (kora)

Sl. 258.

Jajnik (kora)

primordijalni folikul

stroma jajnika



atretični primarni folikul

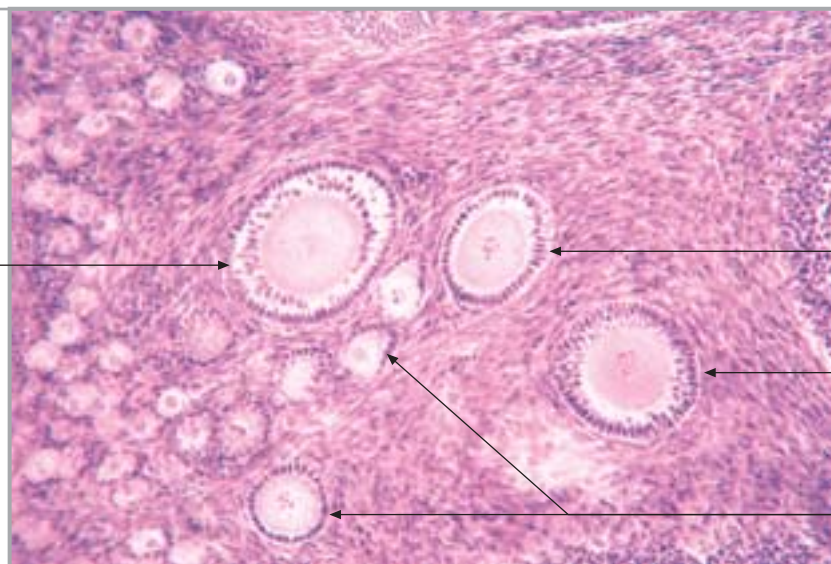
jednoslojni primarni folikul

višeslojni primarni folikul

Sl. 259.

Jajnik (primarni folikul)

višeslojni primarni folikul



jednoslojni primarni folikul

višeslojni primarni folikul

jednoslojni primarni folikul

Sl. 260.

Jajnik (sekundarni folikul)

antrum folliculi

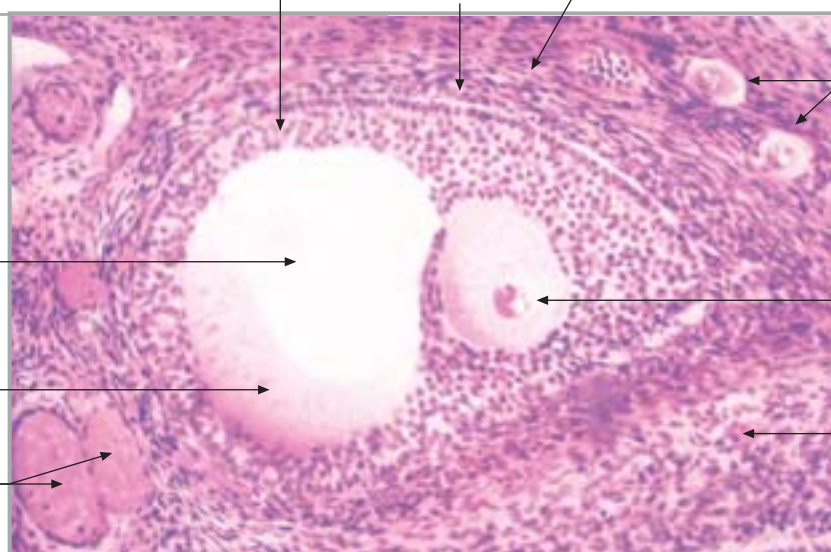
liquor folliculi

vene

membrana granulosa

theca interna

theca externa



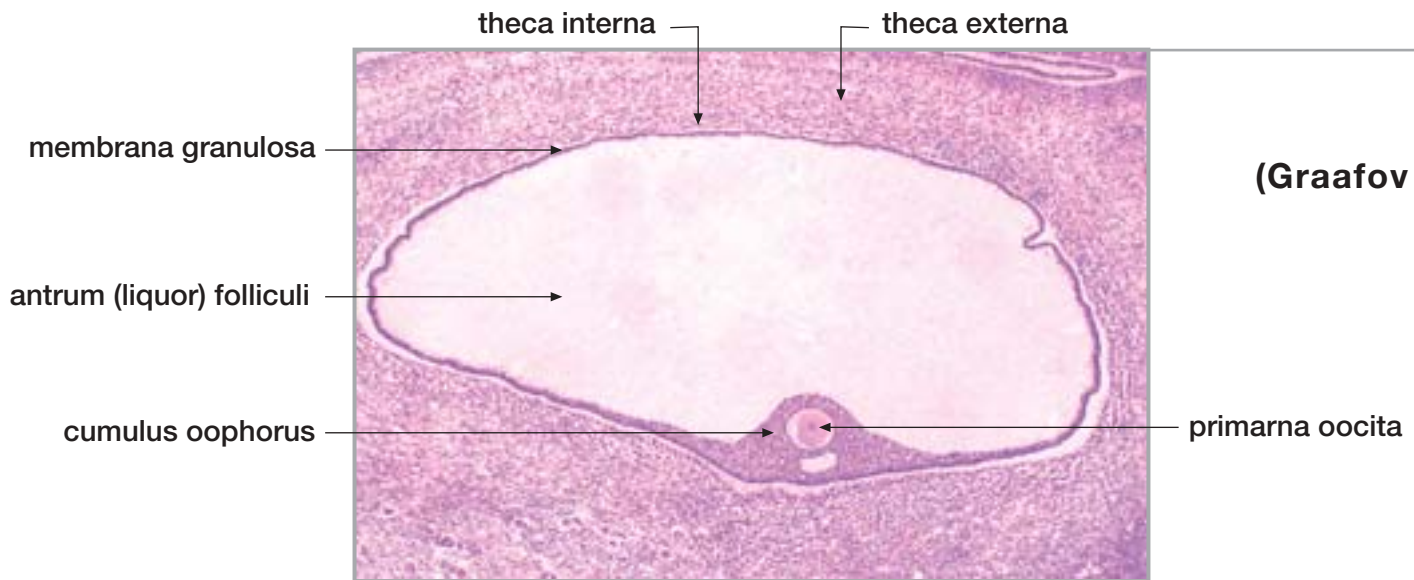
primordijalni folikul

primarna oocita

stroma jajnika

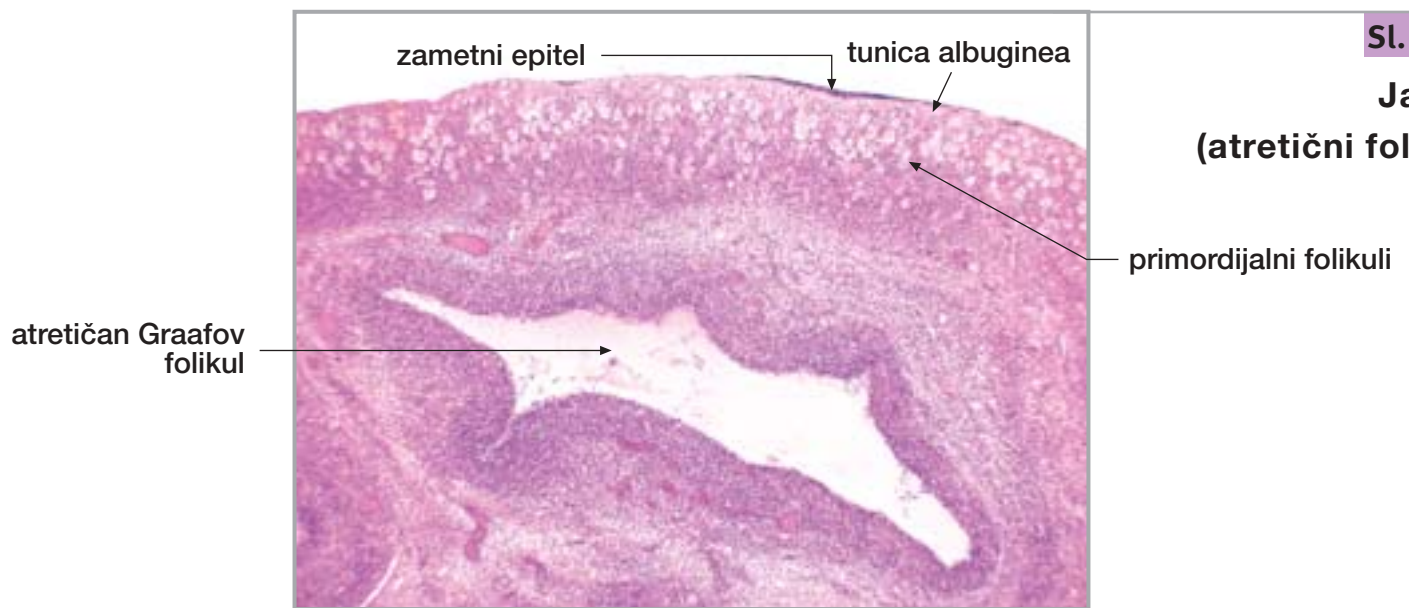
29. JAJNIK I JAJOVOD

nastavak



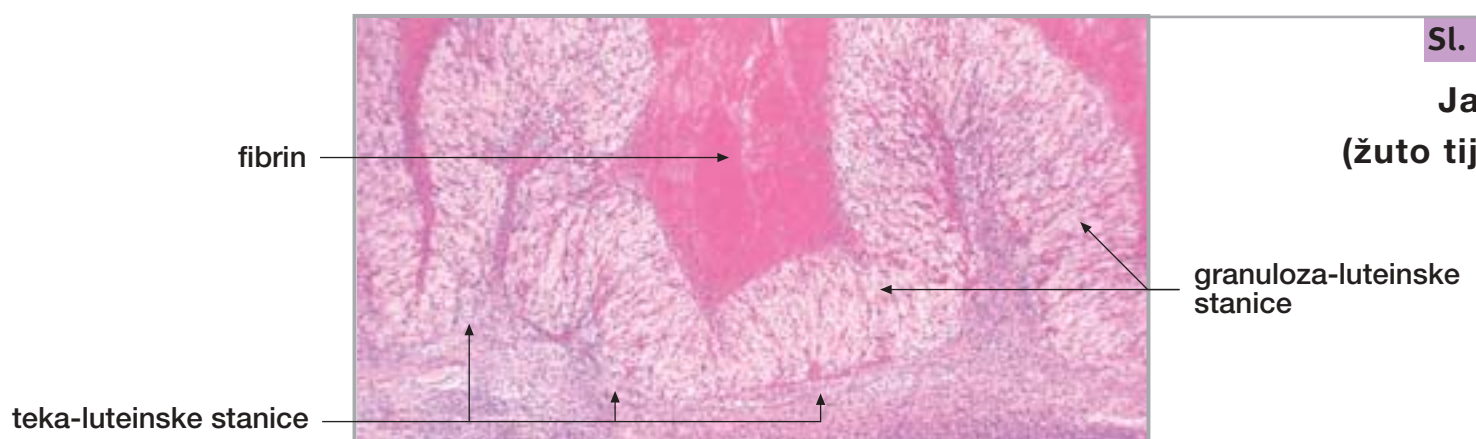
Sl. 261.

**Jajnik
(Graafov folikul)**



Sl. 262.

**Jajnik
(atretični folikul)**



Sl. 263.

**Jajnik
(žuto tijelo)**

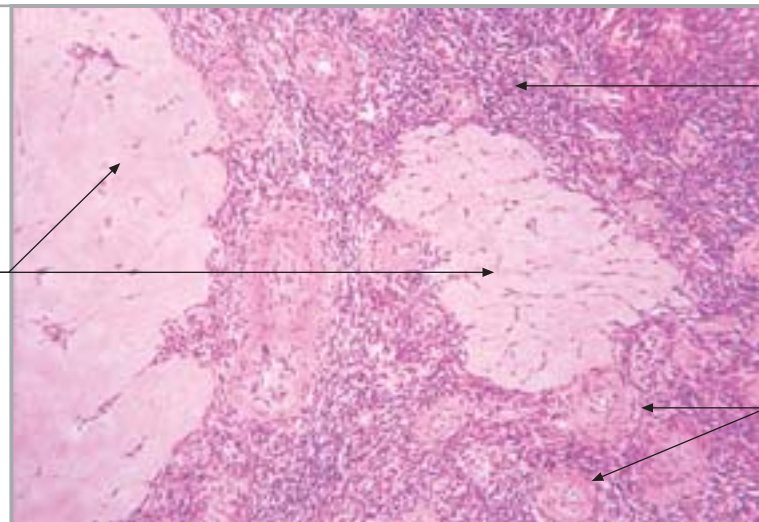
29. JAJNIK I JAJOVOD

nastavak

Sl. 264.

Jajnik
(corpus albicans)

corpus albicans
(fibrosum)



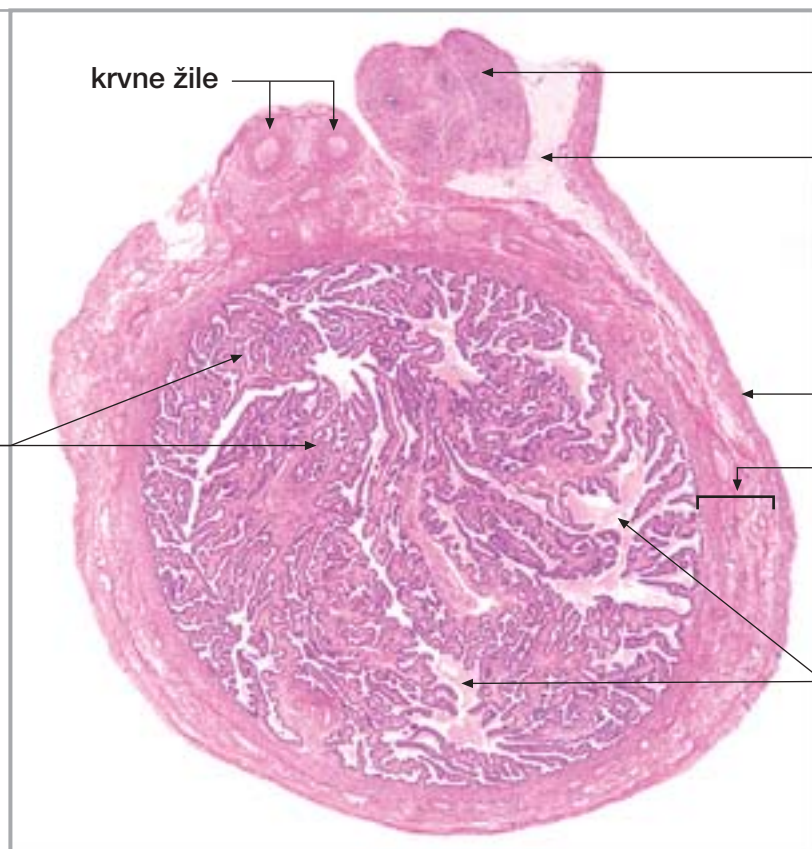stroma jajnika

arterije u srži jajnika

Sl. 265.

Jajovod (ampulla)

nabori sluznice



krvne žile

paroophoron

mesosalpinx

seroza

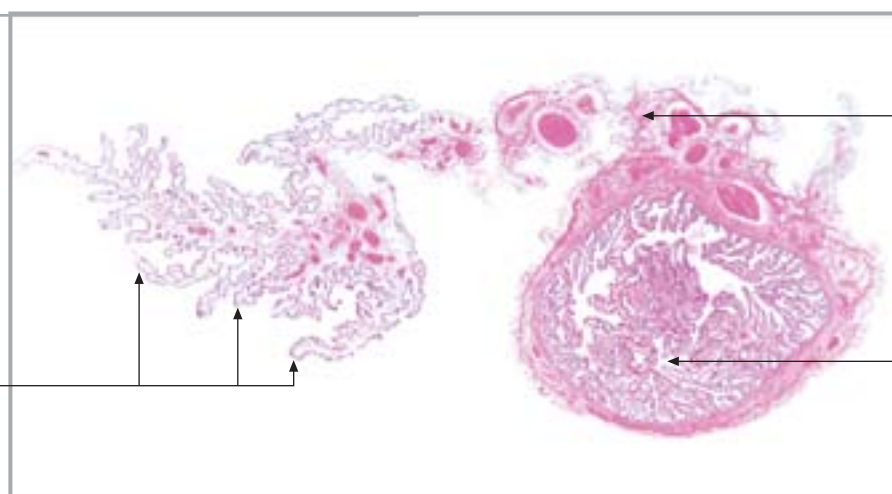
mišićni slojevi

lumen

Sl. 266.

Jajovod
(fimbrije)

fimbrije

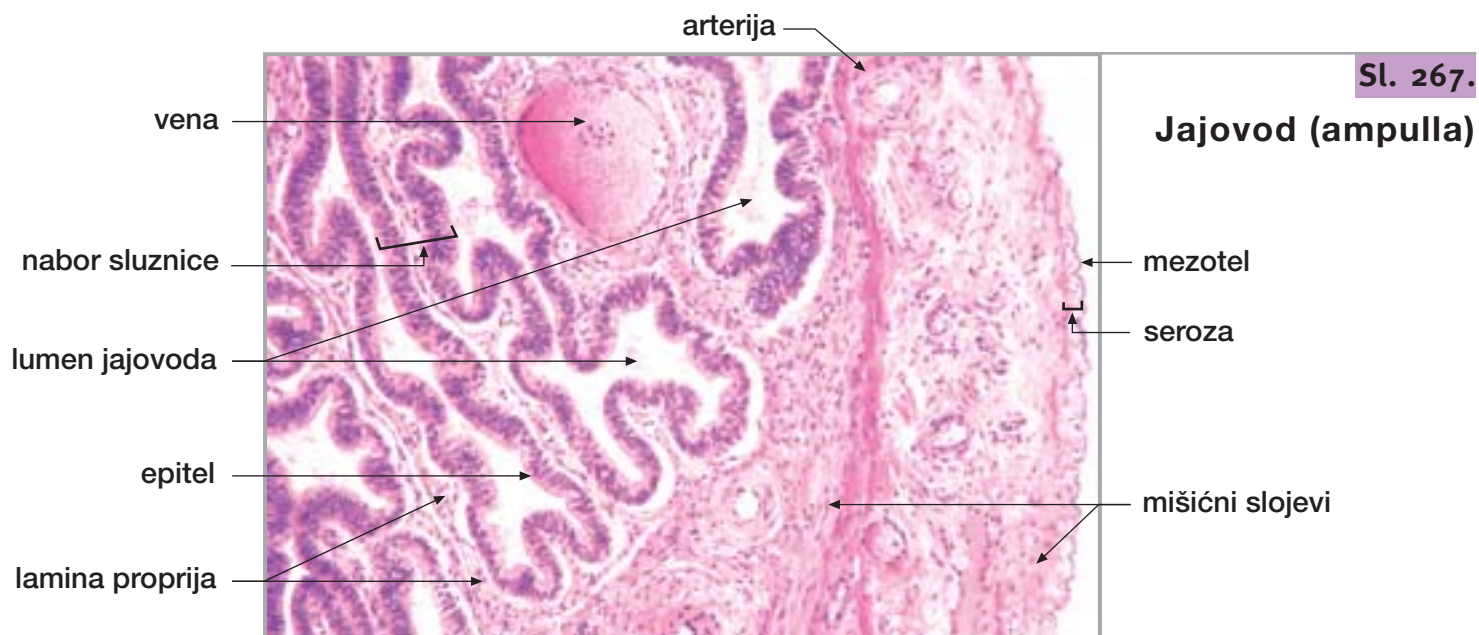


mesosalpinx s
krvnim žilama

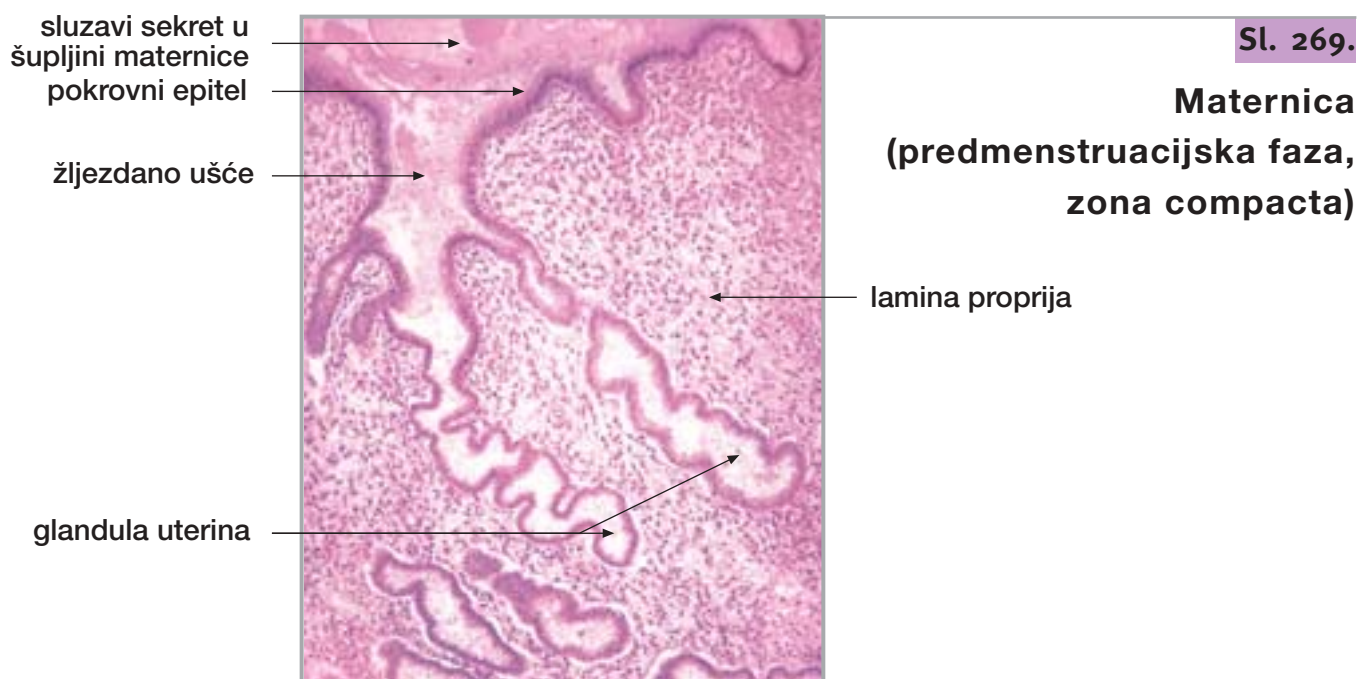
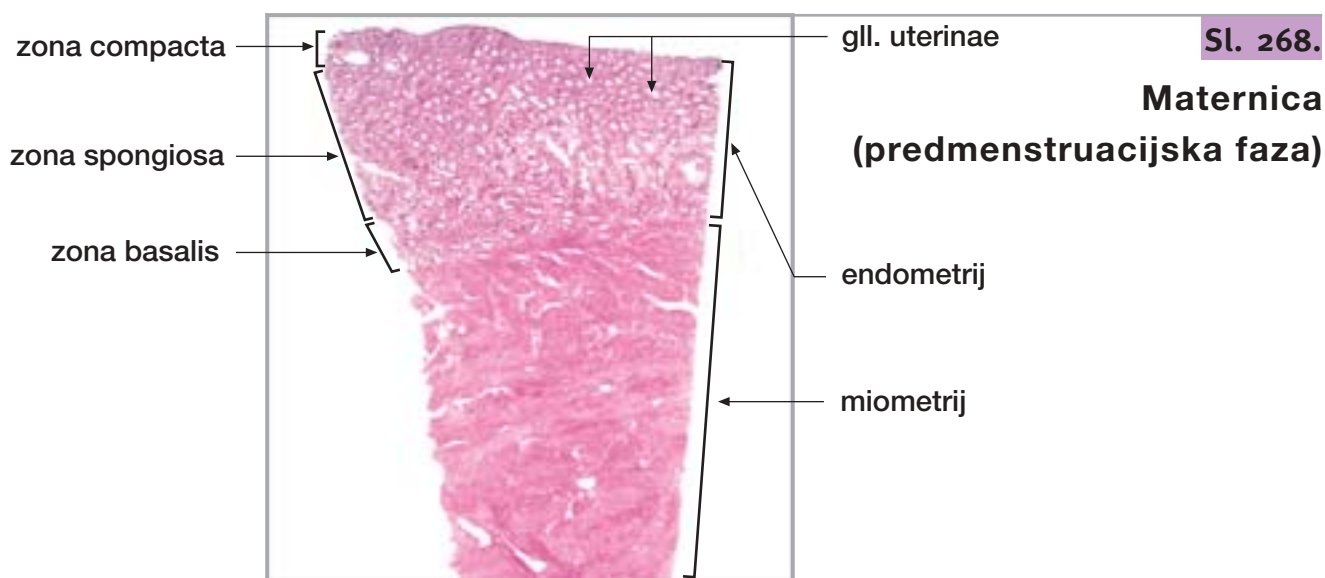
ampulla jajovoda

29. JAJNIK I JAJOVOD

nastavak



30. MATERNICA I RODNICA

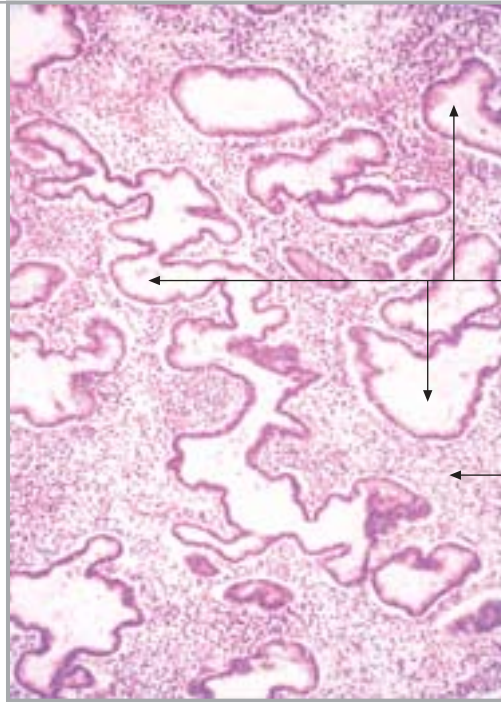


30. MATERNICA I RODNICA

nastavak

Sl. 270.

Maternica
(predmenstruacijska faza,
zona spongiosa)

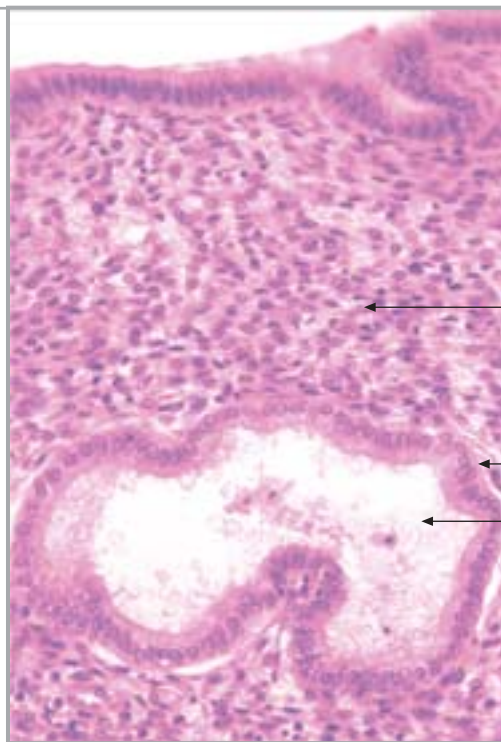


glandula uterina

lamina propria

Sl. 271.

Maternica
(predmenstruacijska faza,
zona compacta)



epitel

lamina propria

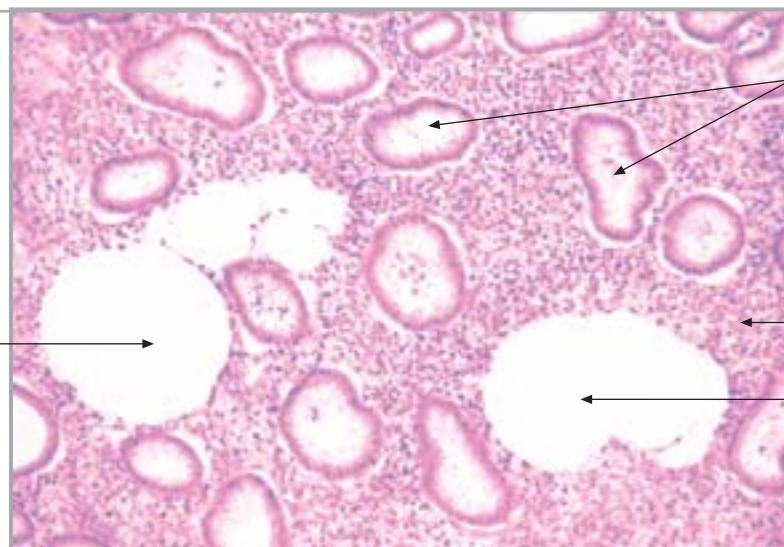
žljezdani epitel

sekret u lumenu

glandula uterina

Sl. 272.

Maternica
(predmenstruacijska
faza, zona
spongiosa)



edem strome

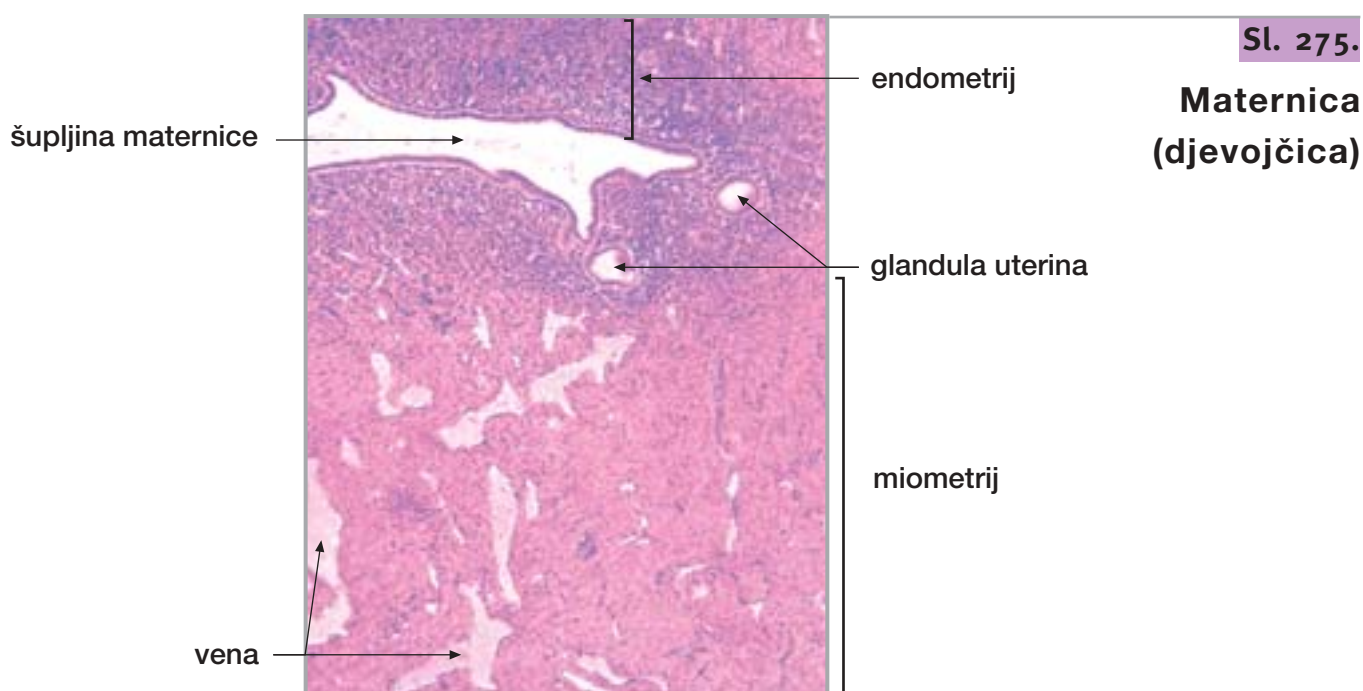
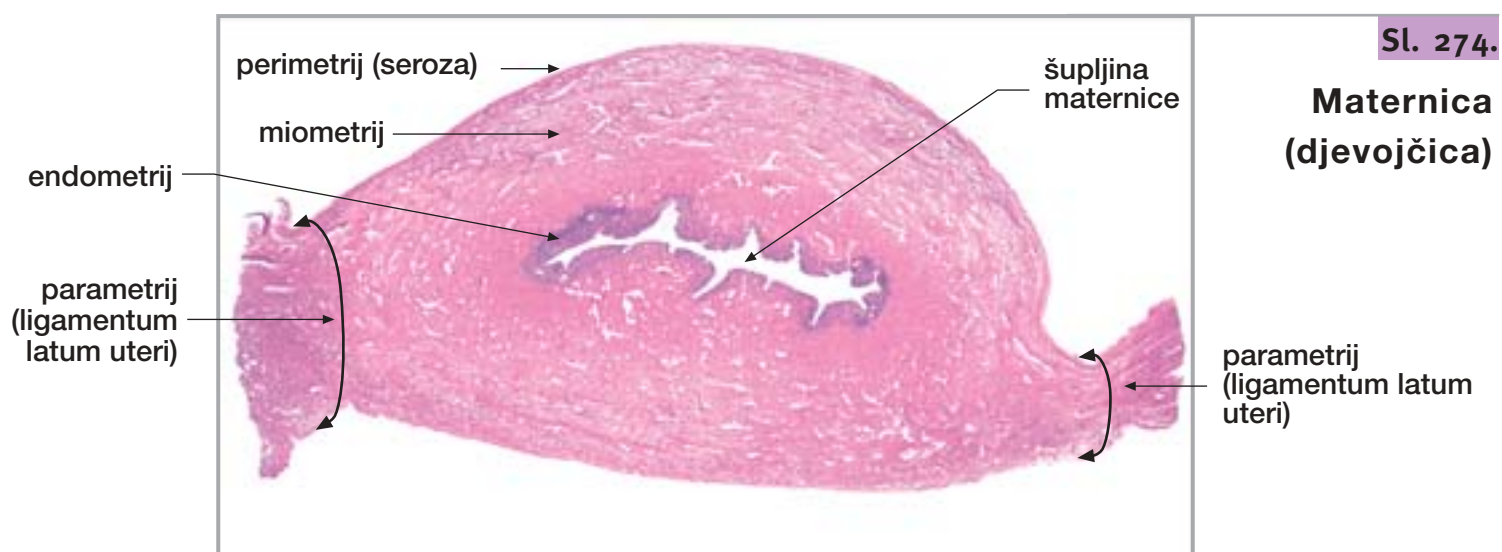
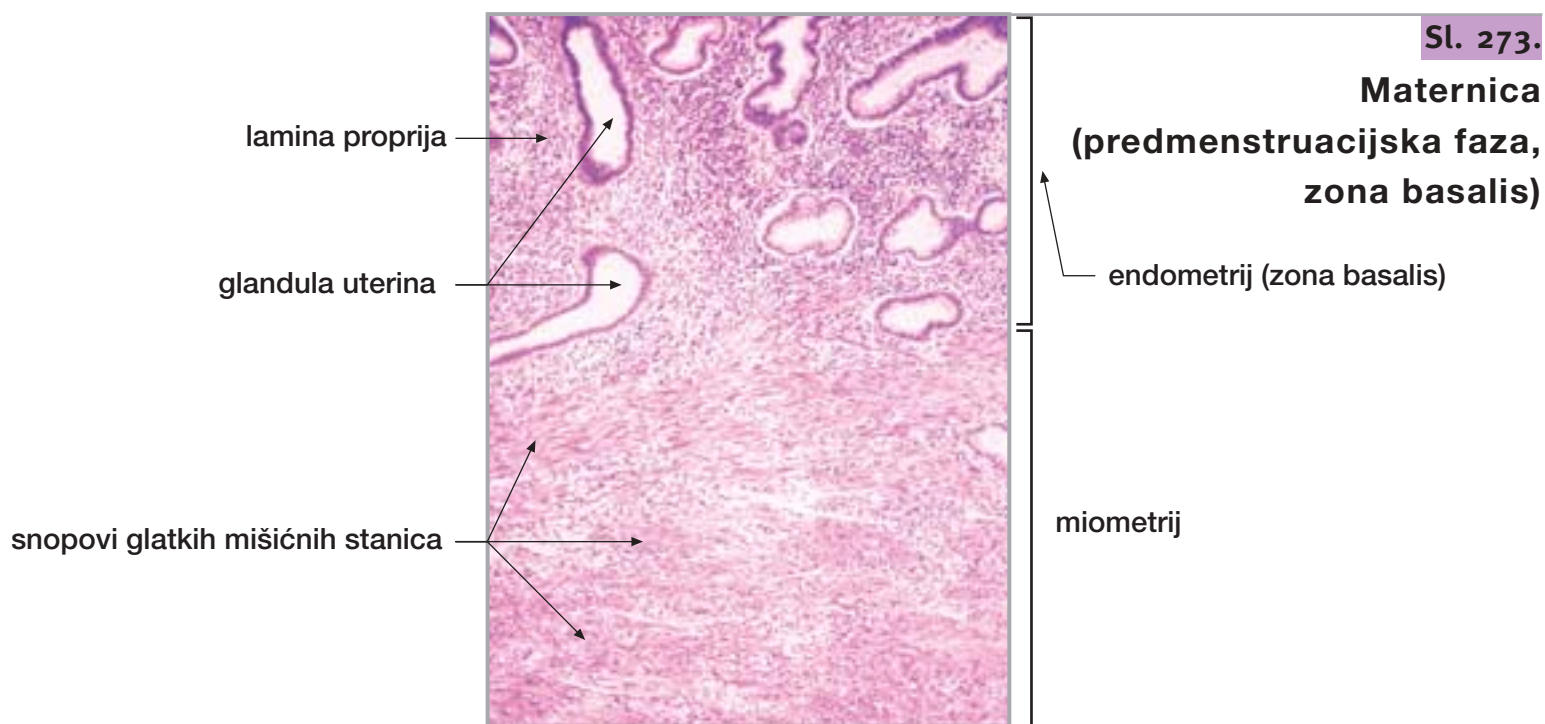
glandula uterina

lamina propria

edem strome

30. MATERNICA I RODNICA

nastavak

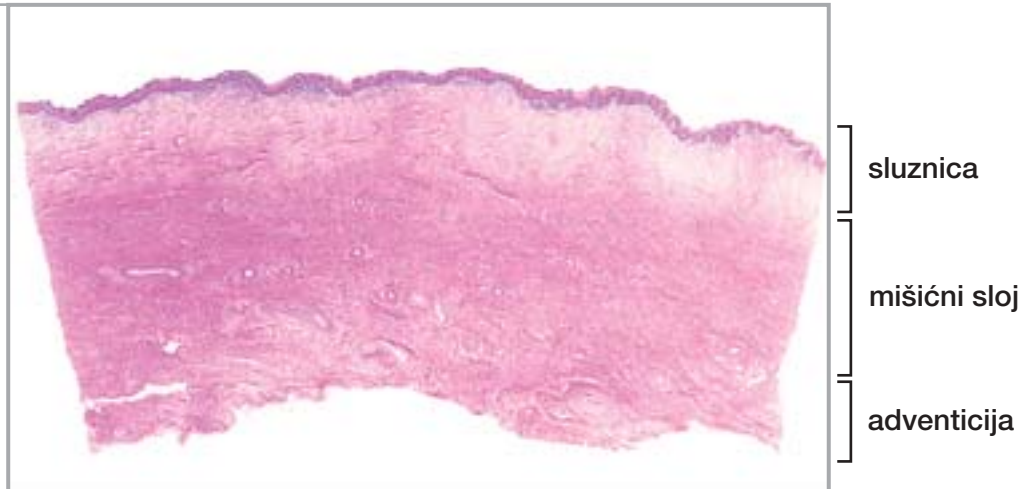


30. MATERNICA I RODNICA

nastavak

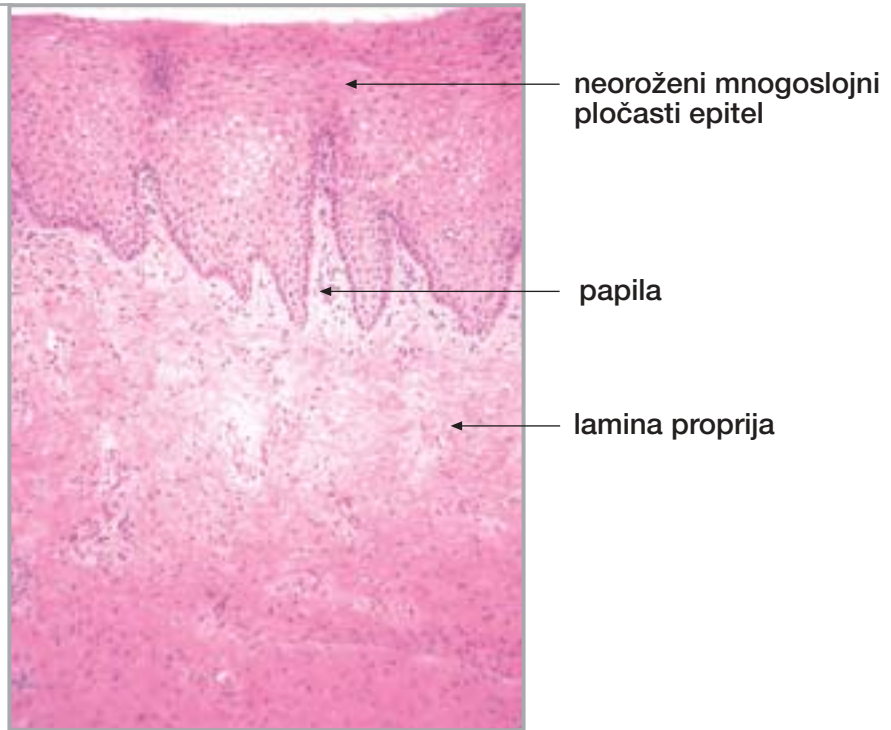
Sl. 276.

Rodnica



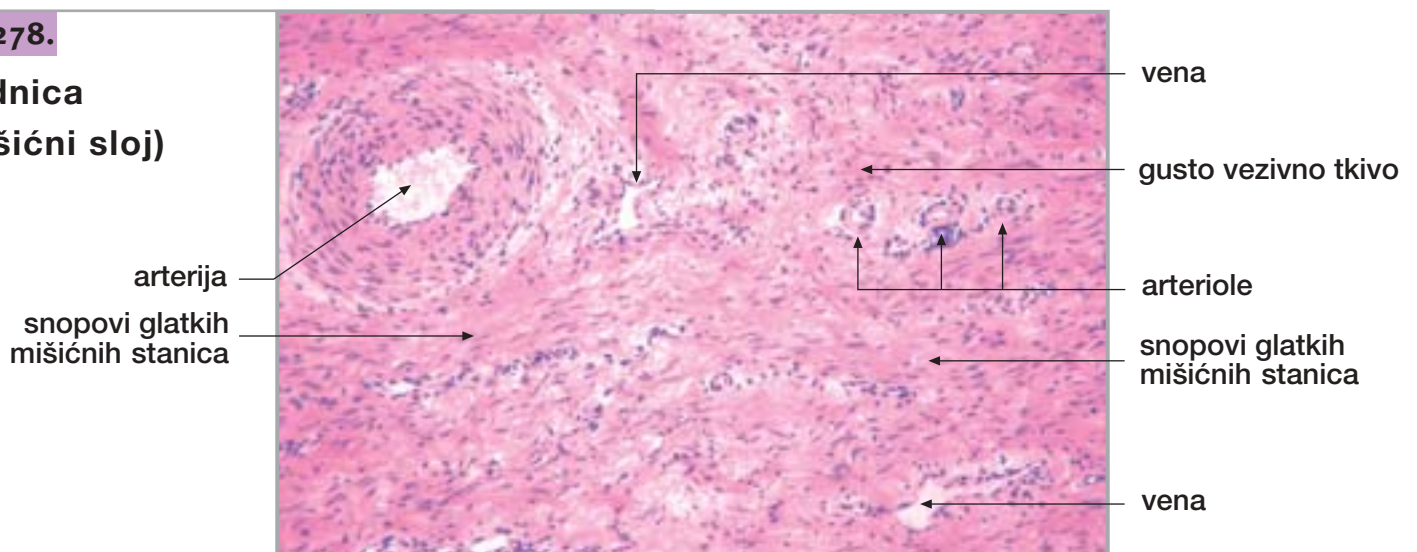
Sl. 277.

Rodnica (sluznica)

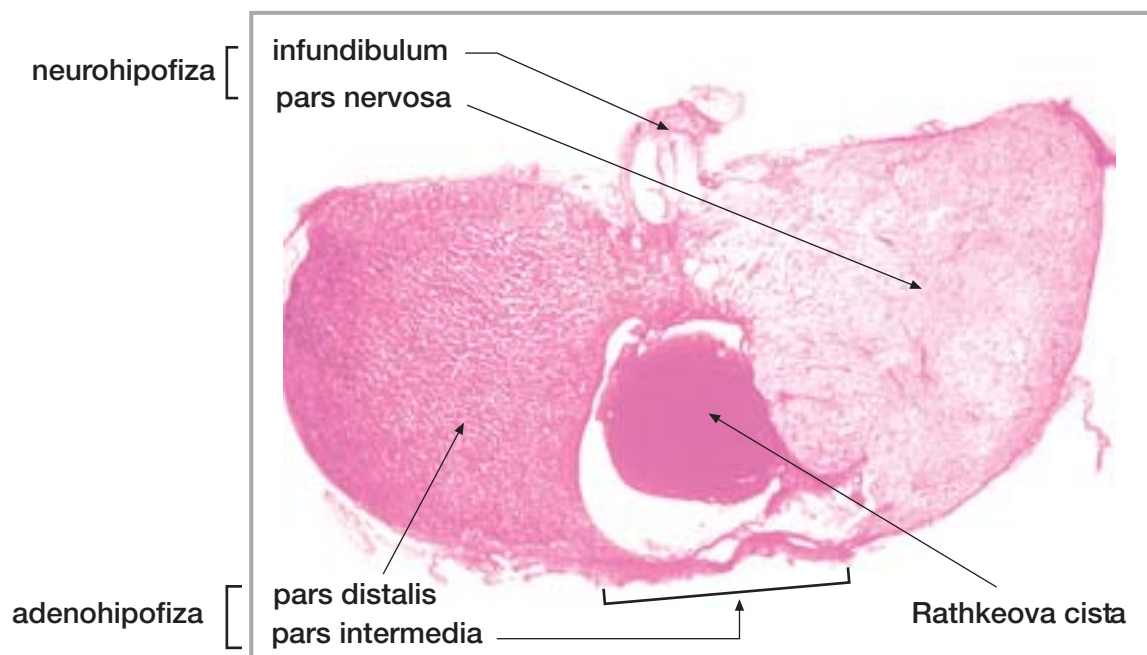


Sl. 278.

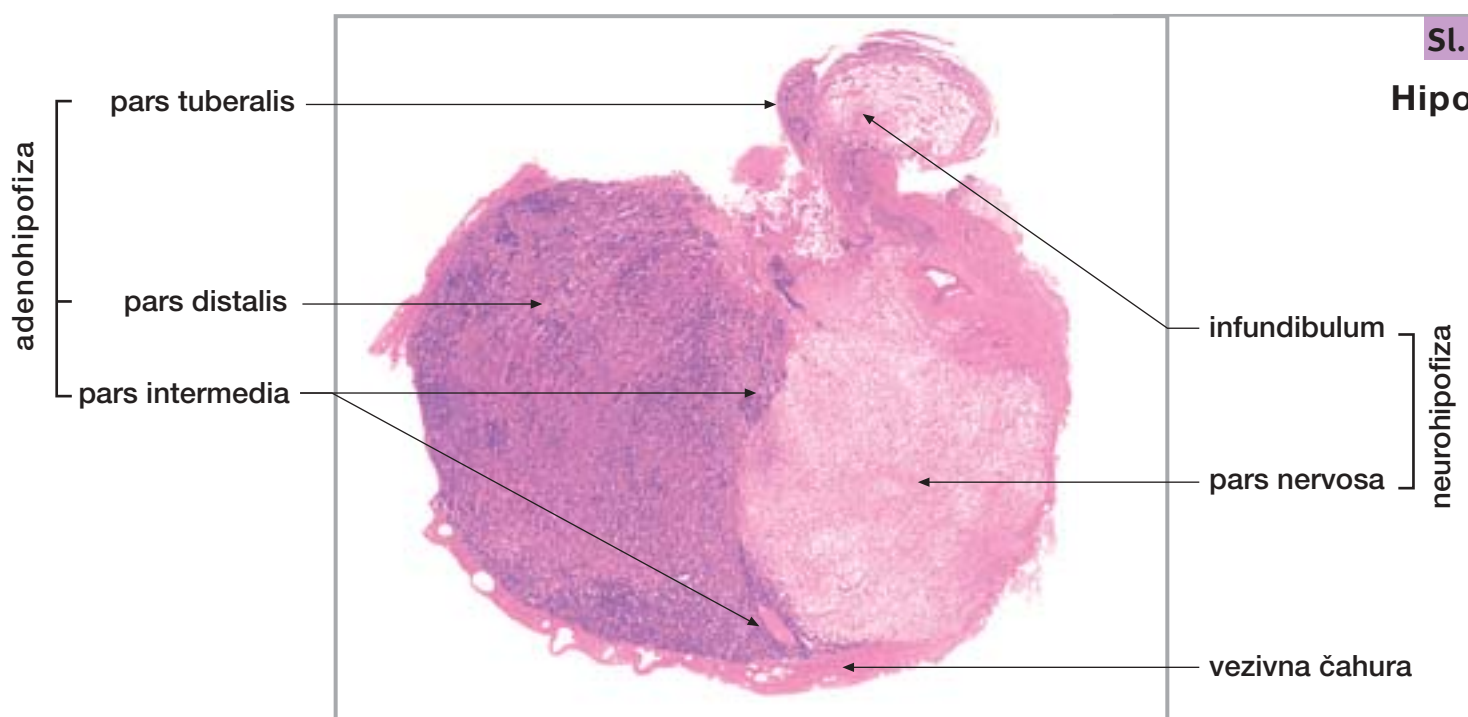
Rodnica
(mišićni sloj)



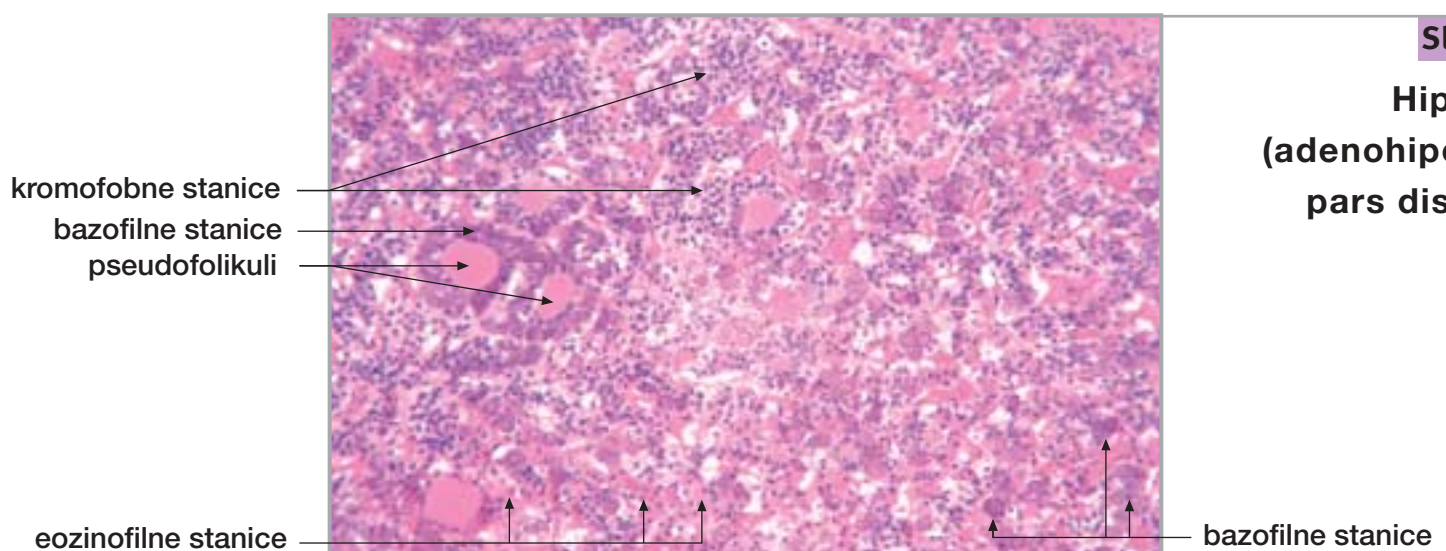
31. ENDOKRINE ŽLIJEZDE



Sl. 279.
Hipofiza



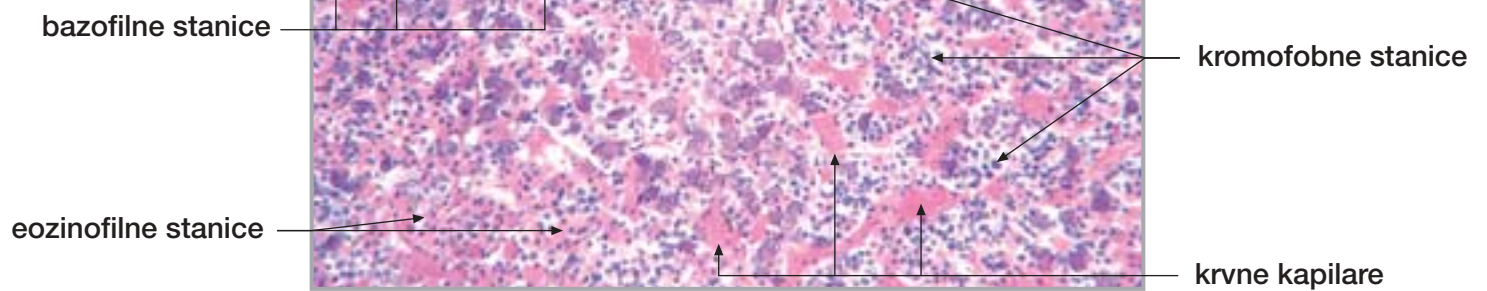
Sl. 280.
Hipofiza



Sl. 281.
Hipofiza
(adenohipofiza,
pars distalis)

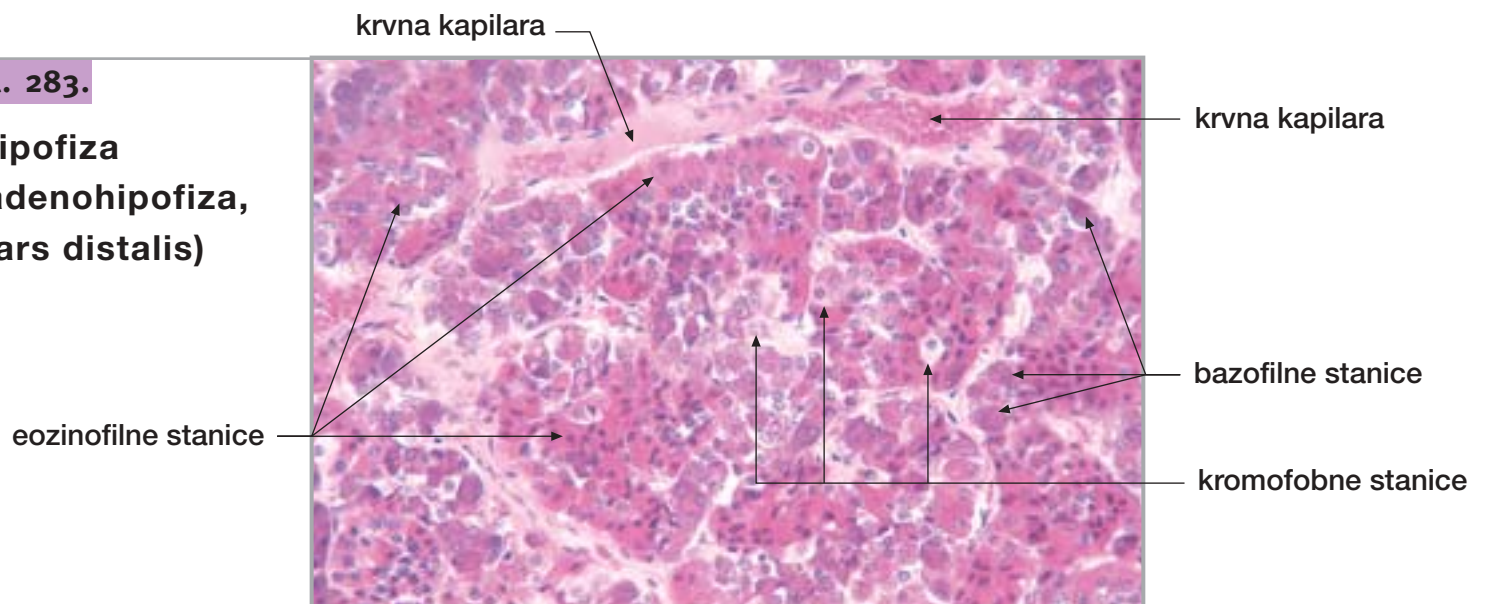
Sl. 282.

Hipofiza
(adenohipofiza,
pars distalis)



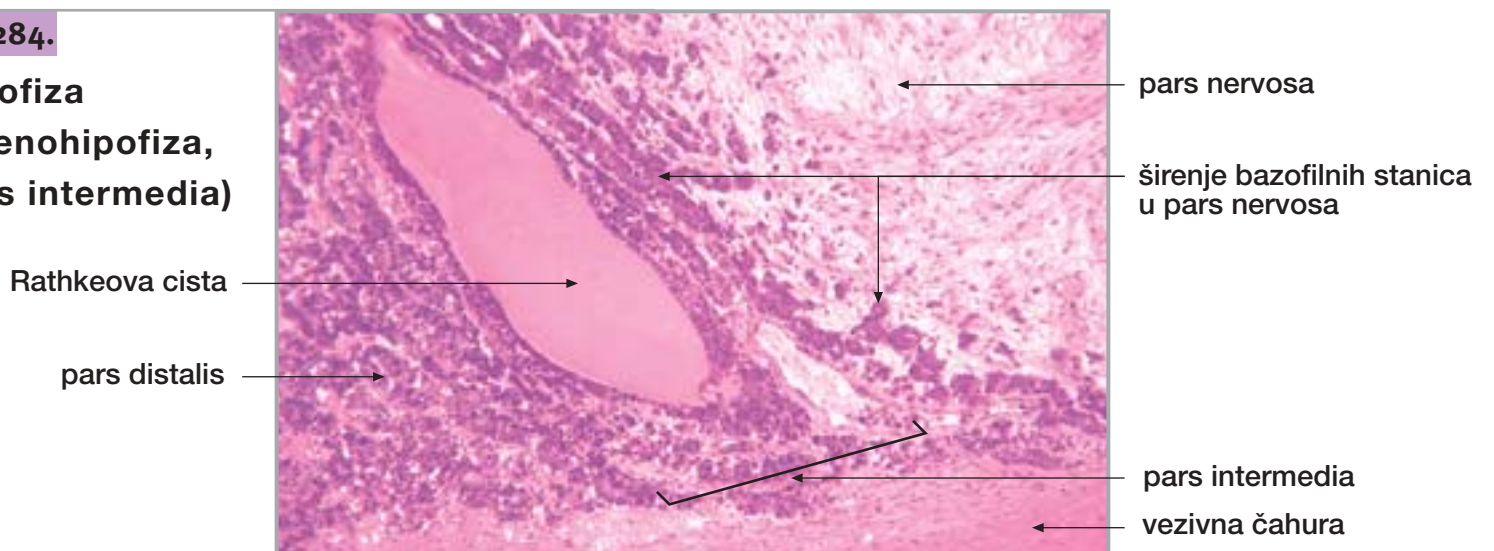
Sl. 283.

Hipofiza
(adenohipofiza,
pars distalis)



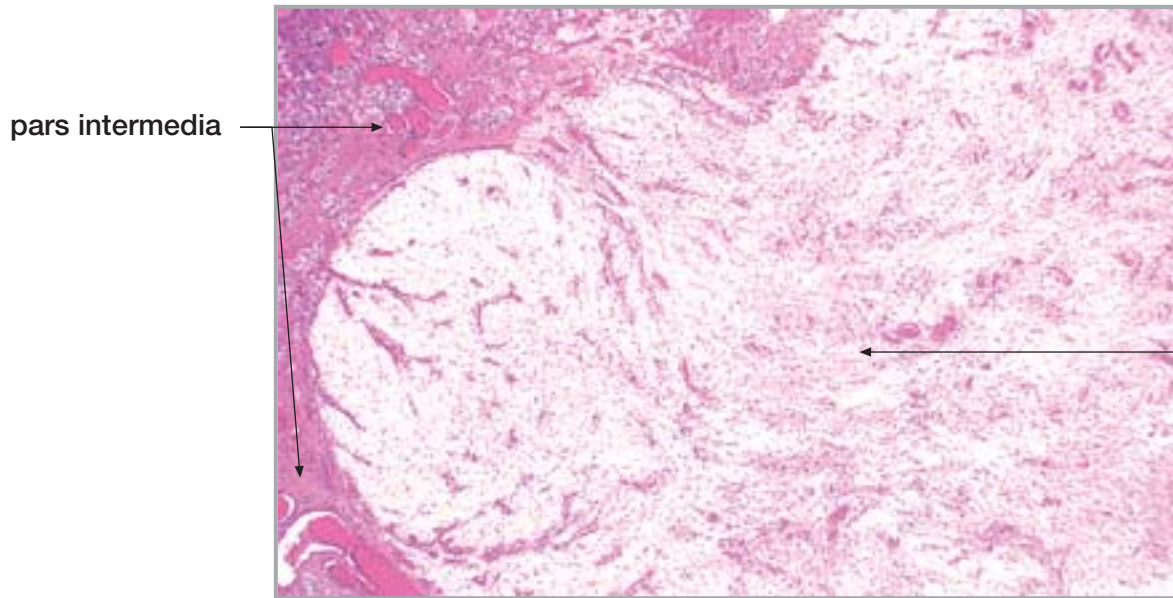
Sl. 284.

Hipofiza
(adenohipofiza,
pars intermedia)



31. ENDOKRINE ŽLIJEZDE

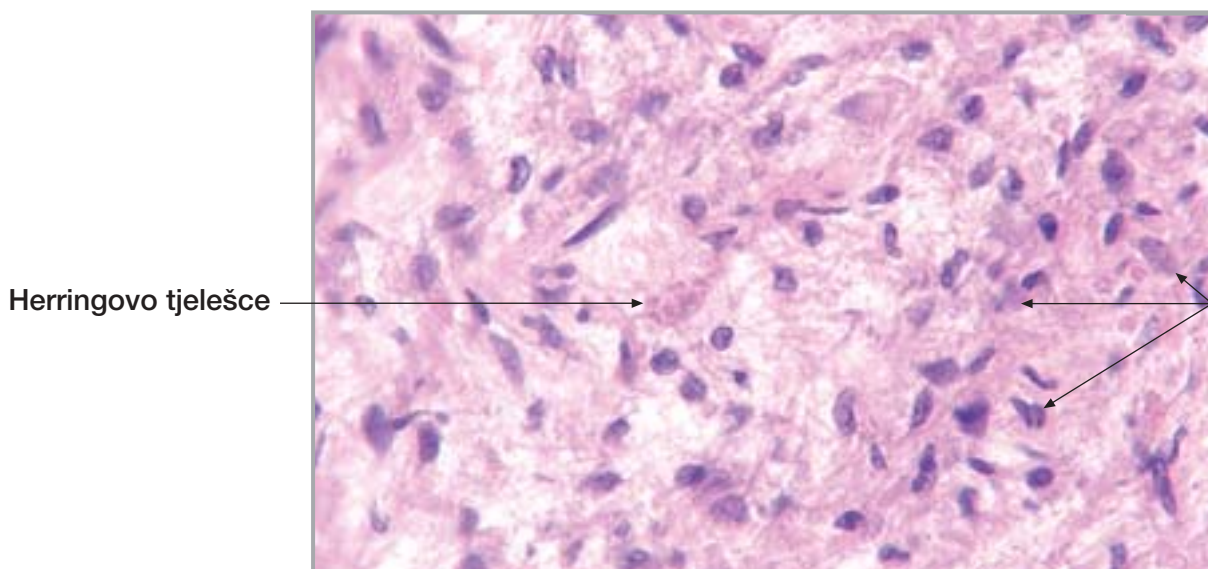
nastavak



Sl. 285.

**Hipofiza
(neurohipofiza,
pars nervosa)**

pars nervosa

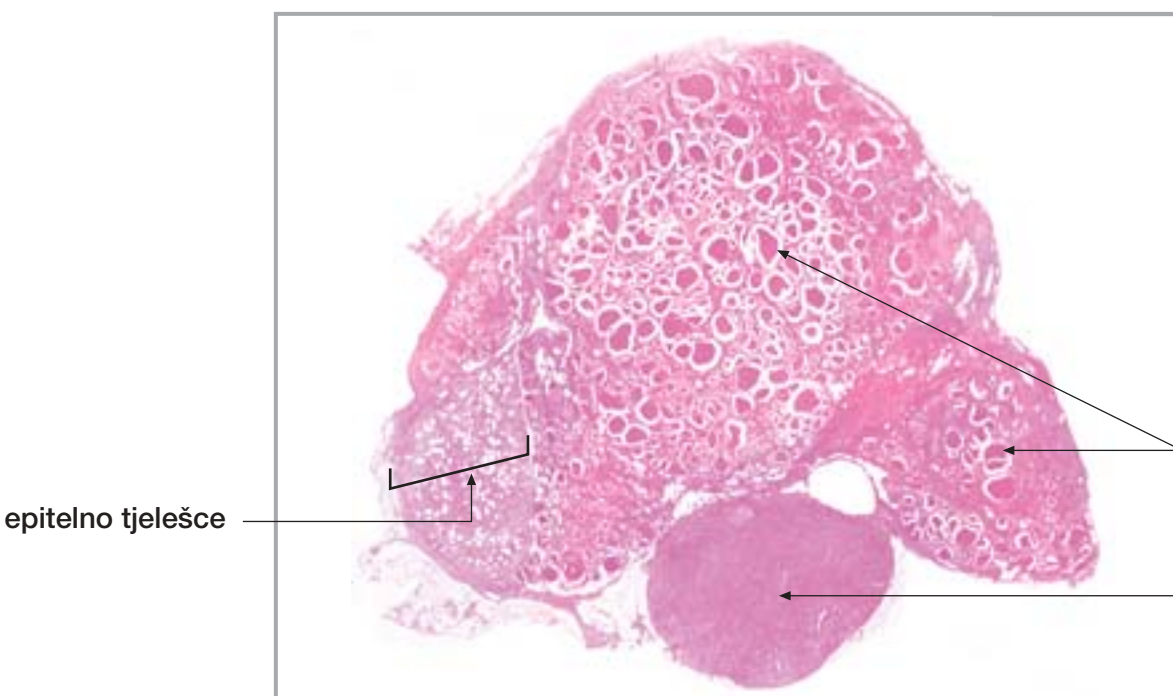


Sl. 286.

**Hipofiza
(neurohipofiza,
pars nervosa)**

Herringovo tjelešce

pituiciti



Sl. 287.

Štitna žlijezda

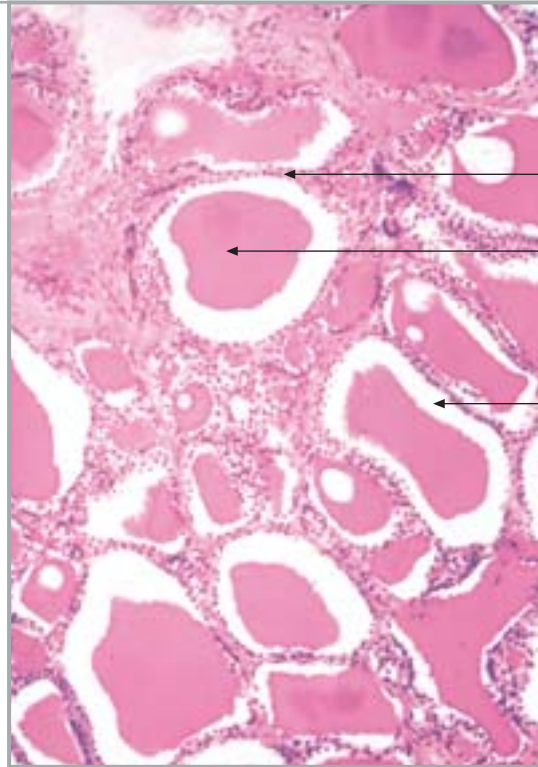
folikuli u
štitnoj žlijezdi

limfni čvor

epitelno tjelešce

Sl. 288.

Štitna žlijezda



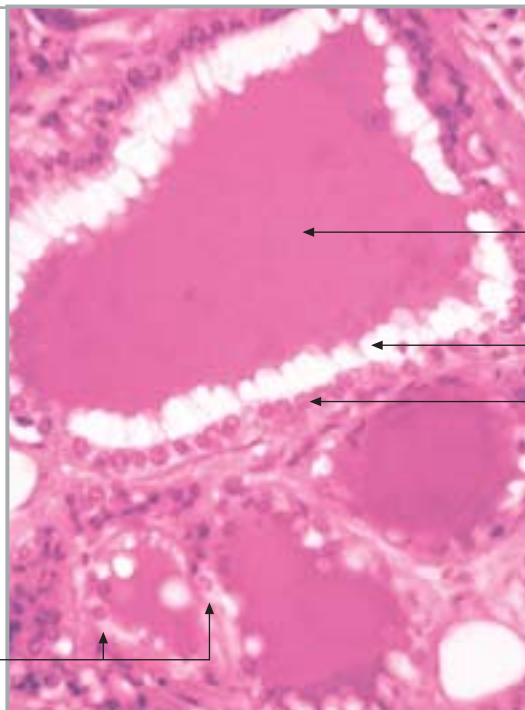
folikularni epitel

koloid

artefakt (skvrčavanje koloida)

Sl. 289.

Štitna žlijezda



koloid

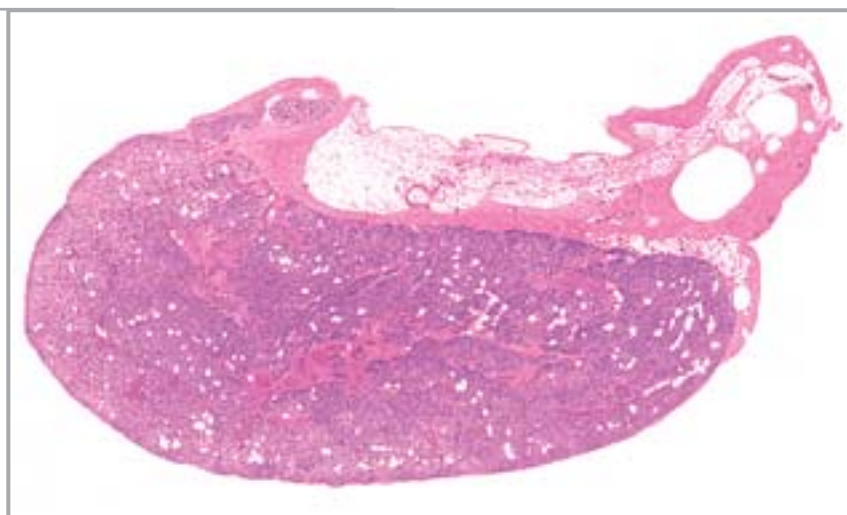
artefakt (skvrčavanje koloida)

folikularni epitel

C-stanice

Sl. 290.

Epitelno tjelešce

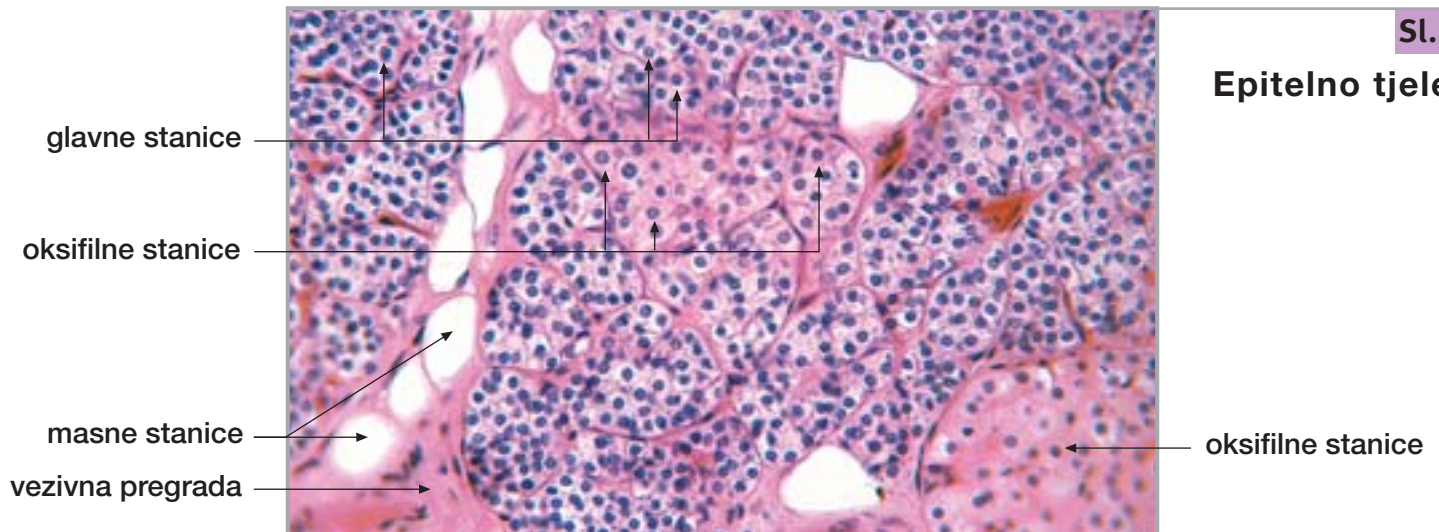


31. ENDOKRINE ŽLIJEZDE

nastavak

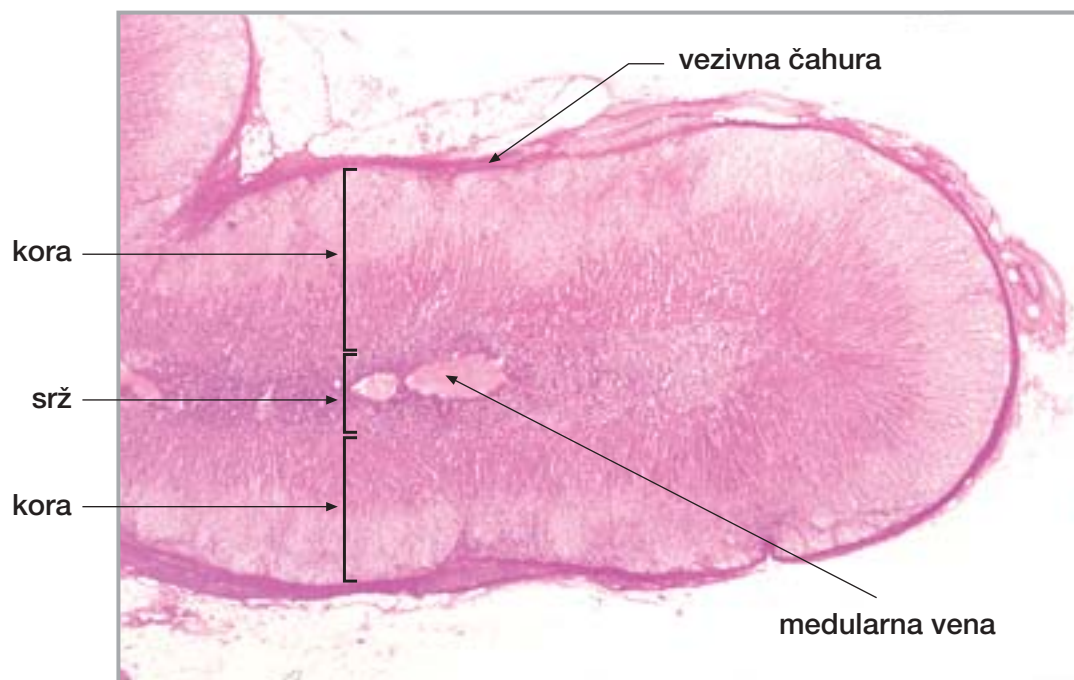
Sl. 291.

Epitelno tjelešce



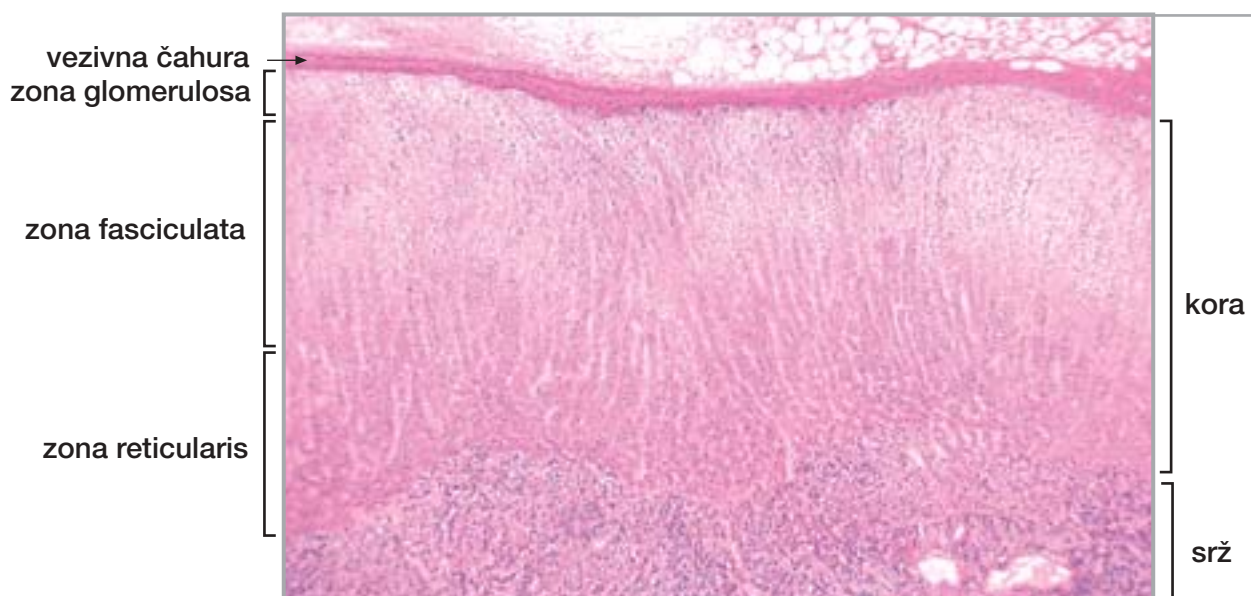
Sl. 292.

Nadbubrežna žlijezda



Sl. 293.

Nadbubrežna žlijezda

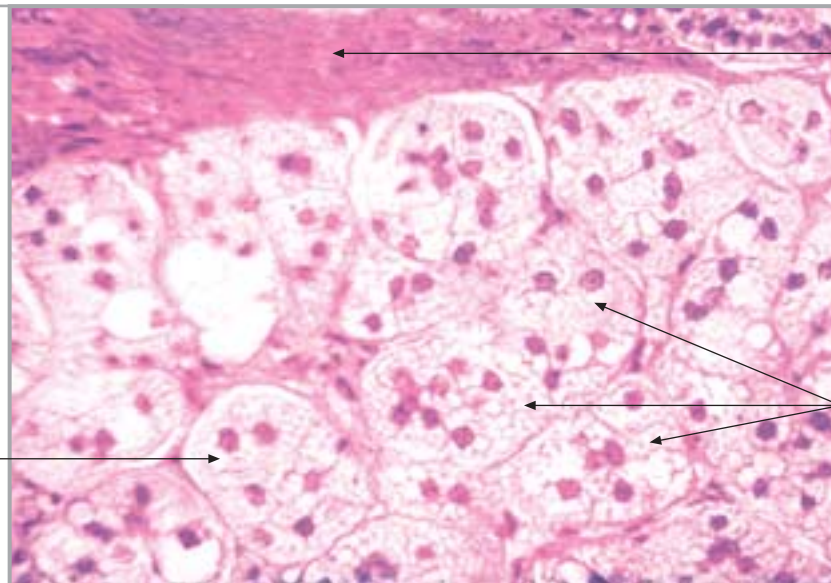


31. ENDOKRINE ŽLIJEZDE

nastavak

Sl. 294.

**Nadbubrežna
žlijezda
(kora, zona
glomerulosa)**



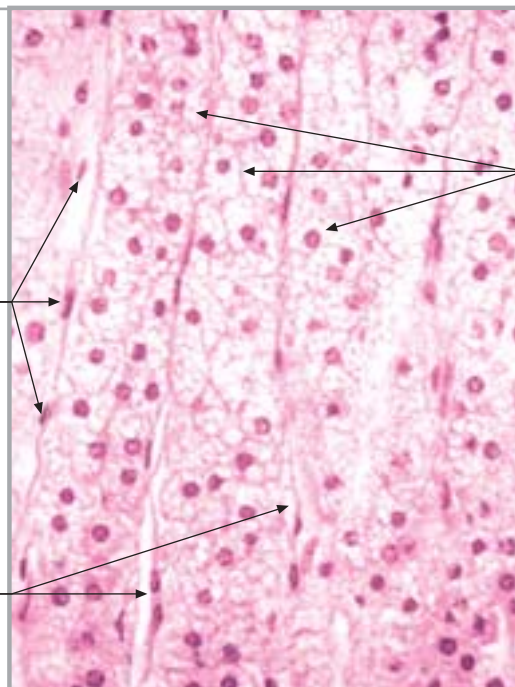
vezivna čahura

okrugle nakupine
epitelnih stanica
("glomeruli")

vakuolizirana
citoplazma (lipidi)

Sl. 295.

**Nadbubrežna žlijezda
(kora, zona fasciculata)**



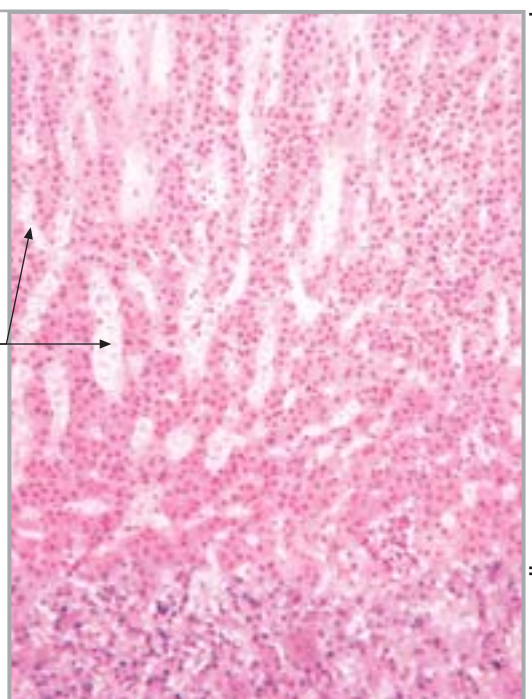
tračci ("fascikuli") epitelnih stanica

endotelne stanice

krvne kapilare

Sl. 296.

**Nadbubrežna žlijezda
(kora, zona reticularis)**



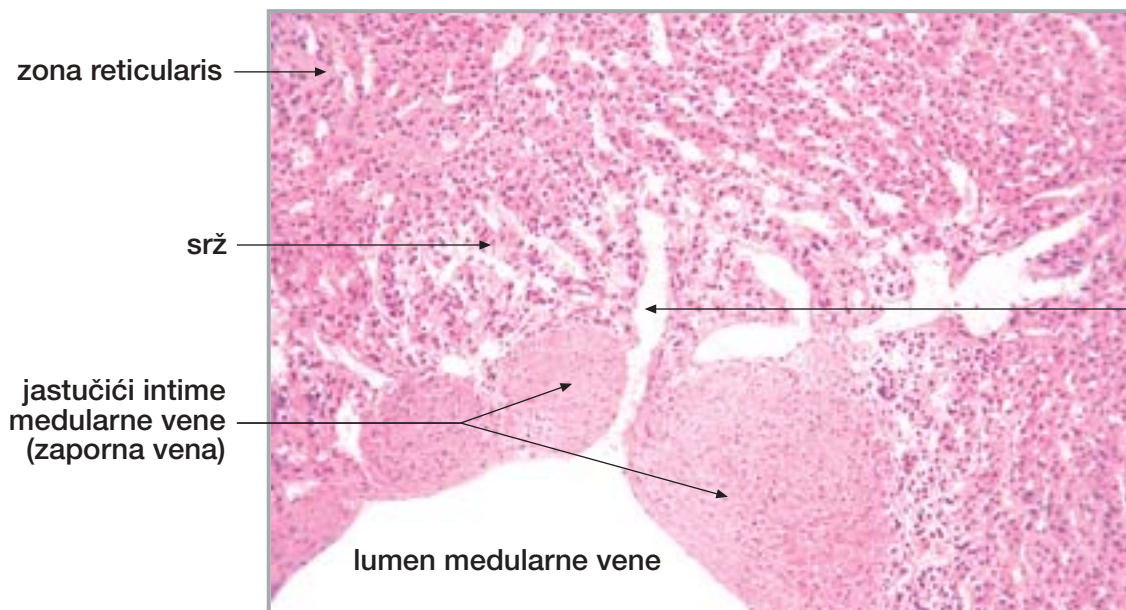
zona reticularis

krvne kapilare

srž

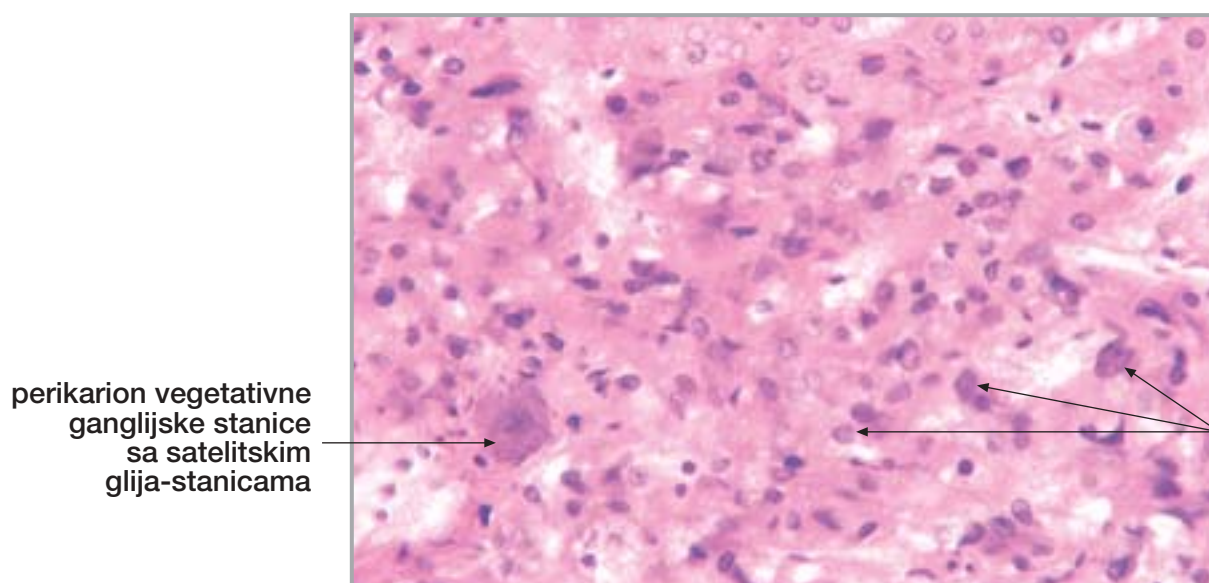
31. ENDOKRINE ŽLIJEZDE

nastavak



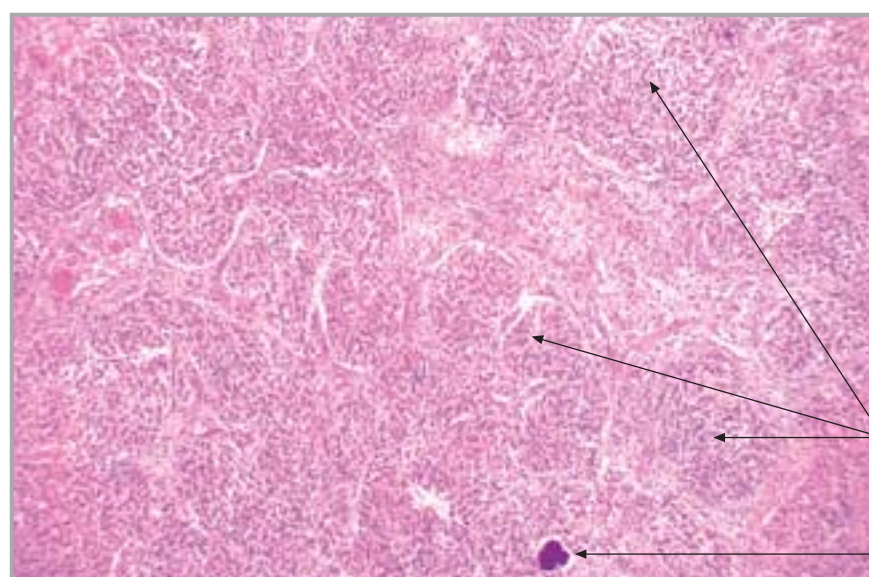
Sl. 297.

Nadbubrežna žlijezda (srž)



Sl. 298.

Nadbubrežna žlijezda (srž)



Sl. 299.

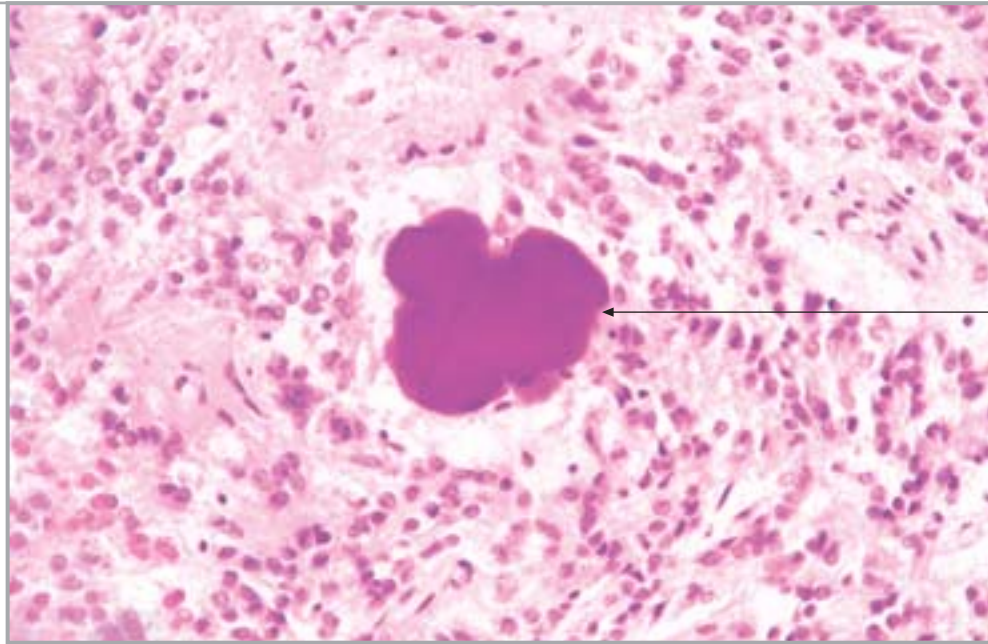
Epifiza

31. ENDOKRINE ŽLIJEZDE

nastavak

Sl. 300.

Epifiza

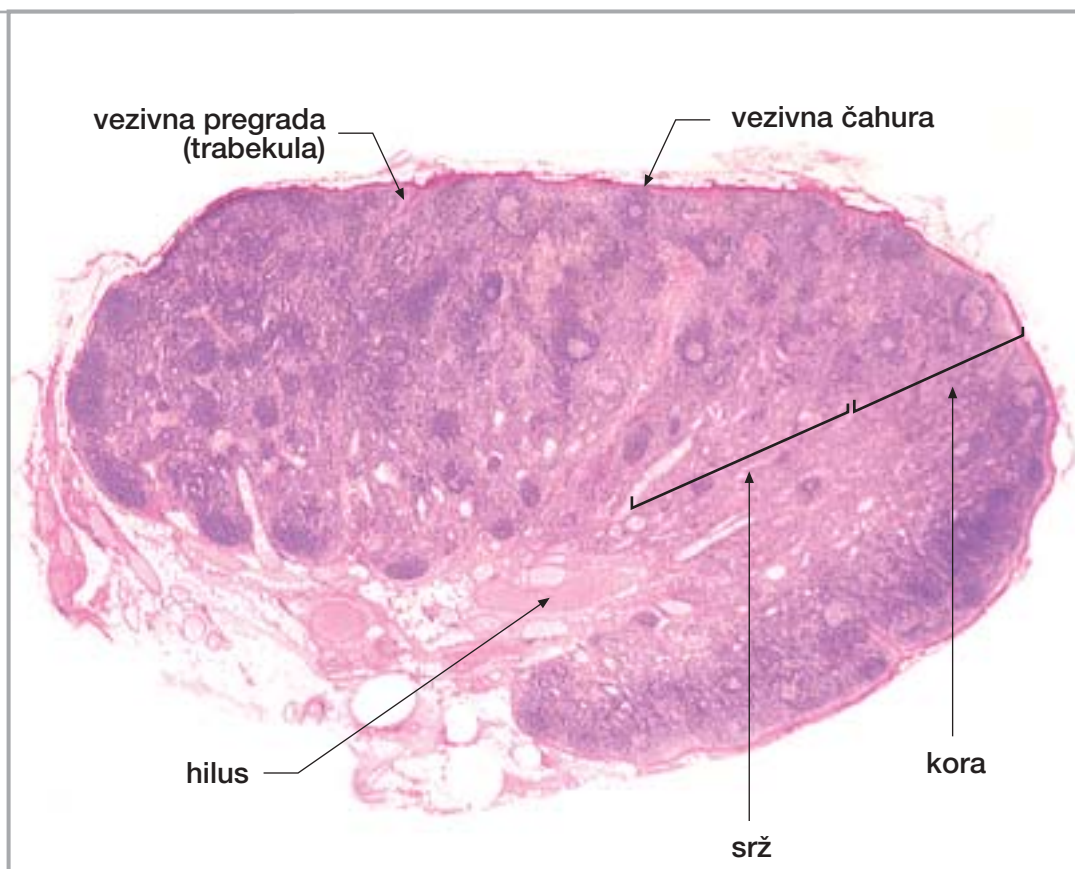


acervulus

32. LIMFNI ČVOR, SLEZENA I TIMUS

Sl. 301.

Limfni čvor



vezivna pregrada
(trabekula)

vezivna čahura

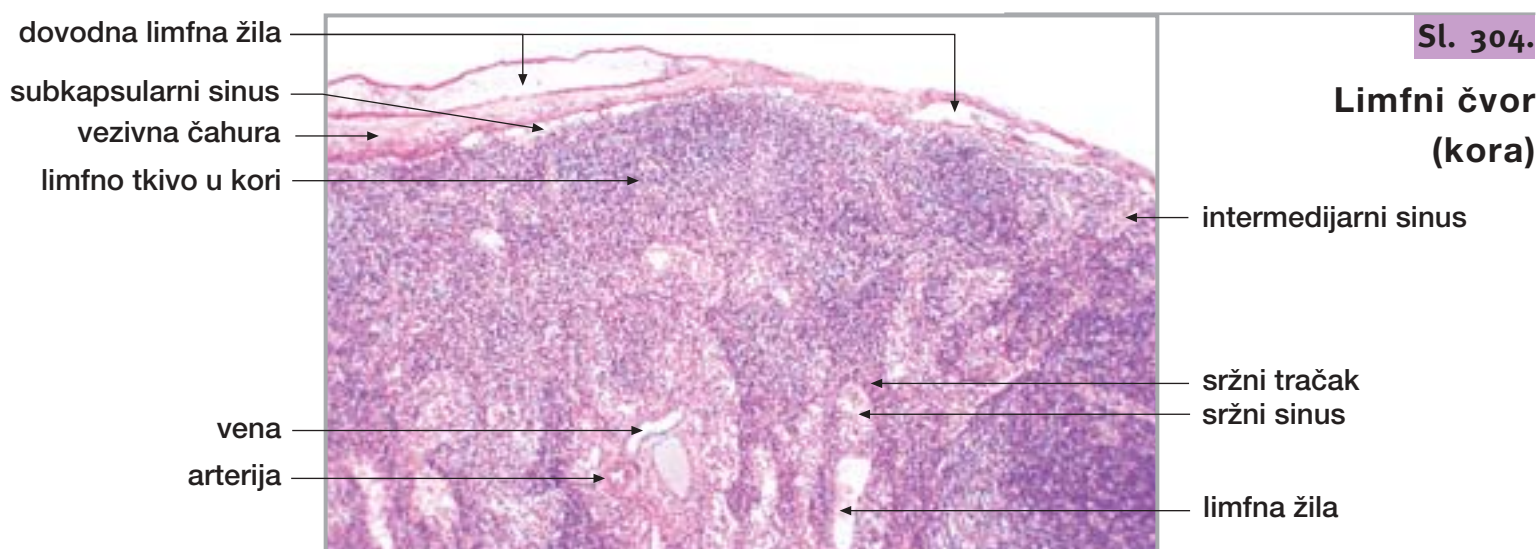
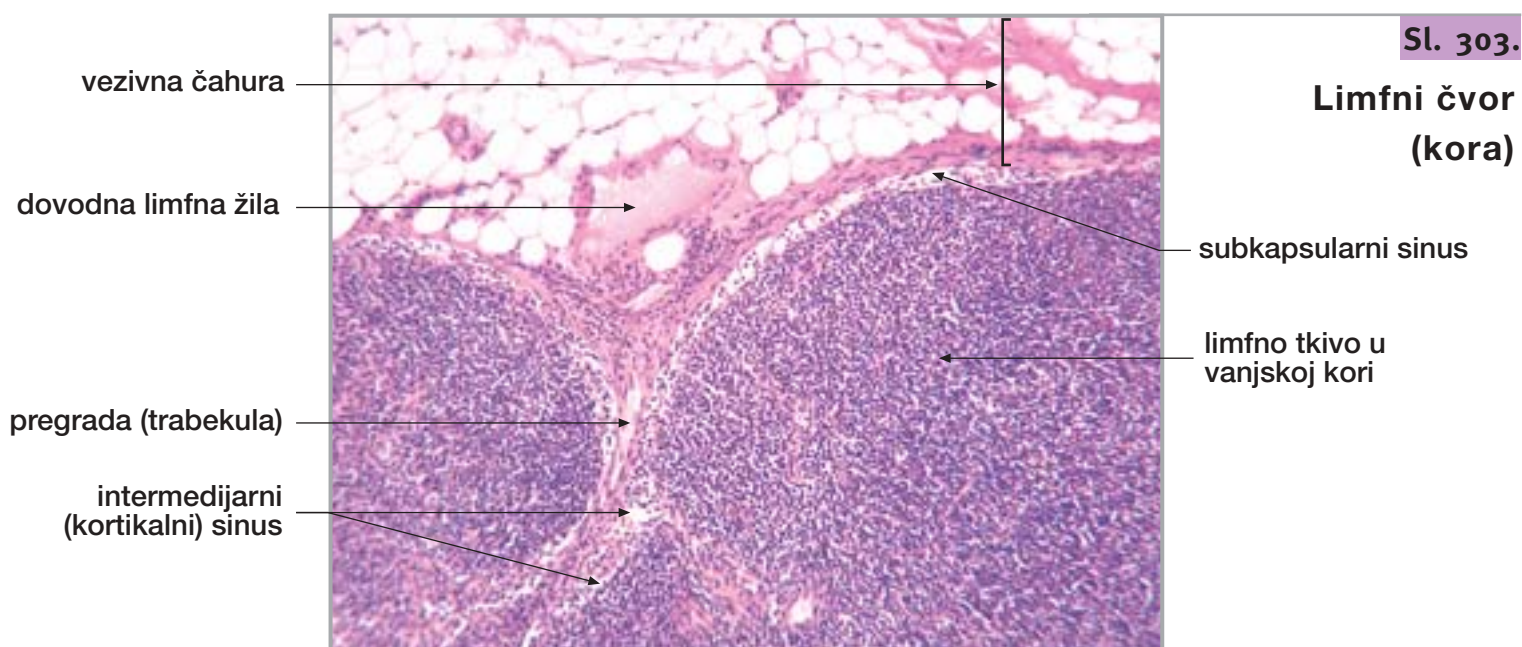
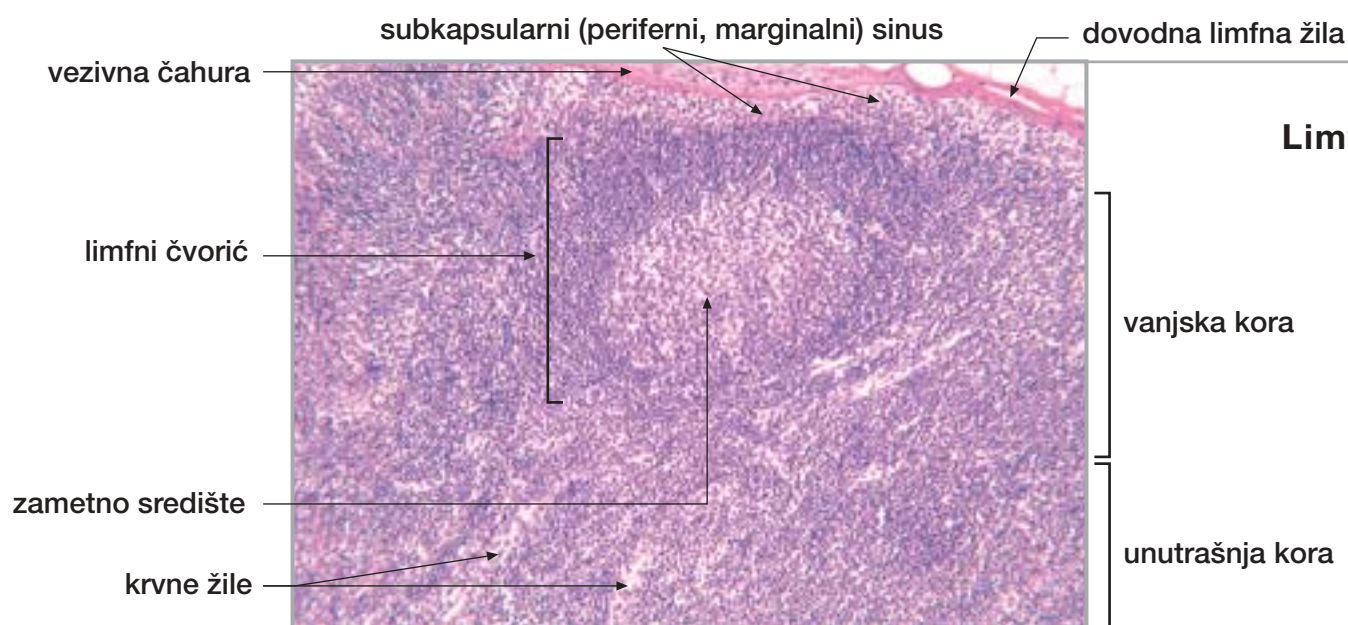
hilus

srž

kora

32. LIMFNI ČVOR, SLEZENA I TIMUS

nastavak

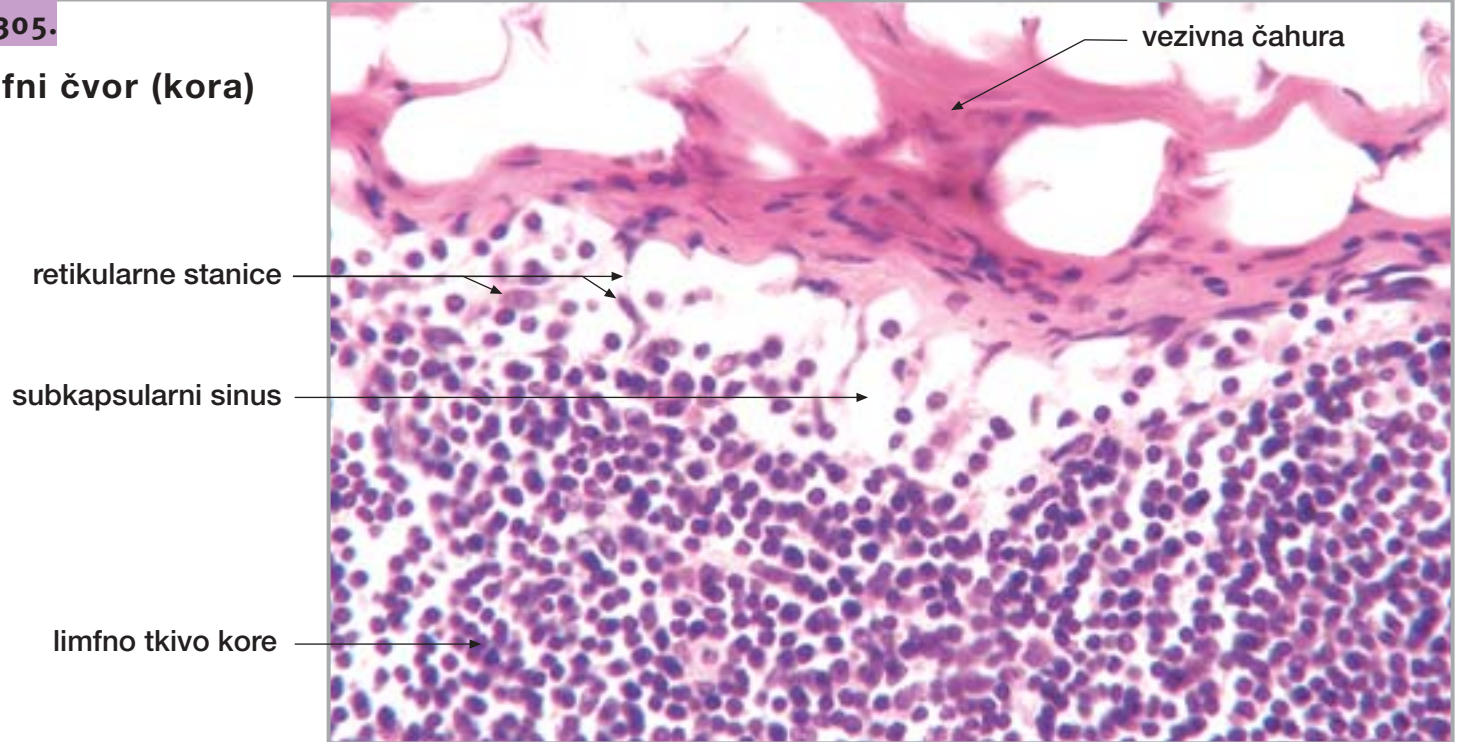


32. LIMFNI ČVOR, SLEZENA I TIMUS

nastavak

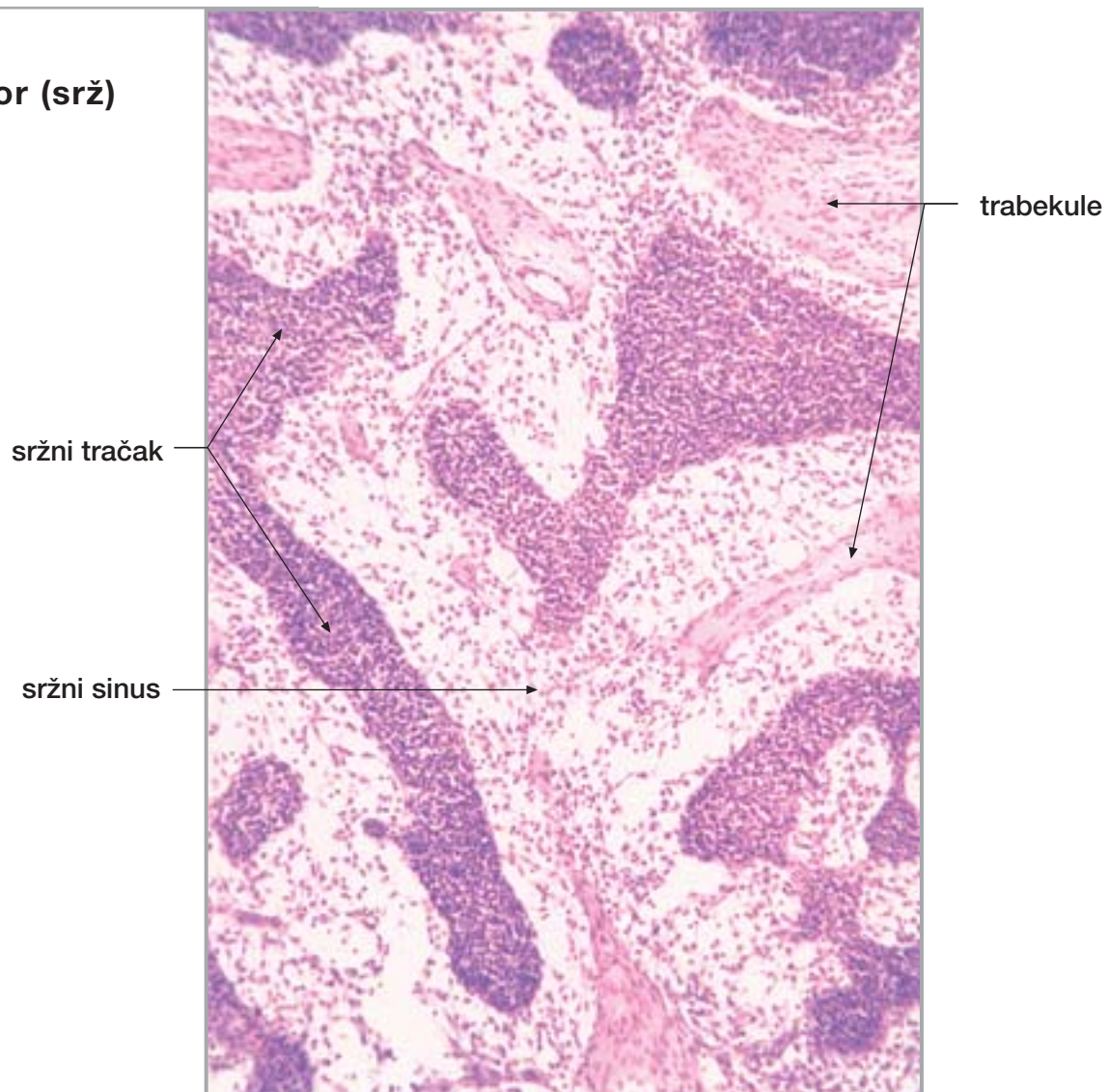
Sl. 305.

Limfni čvor (kora)



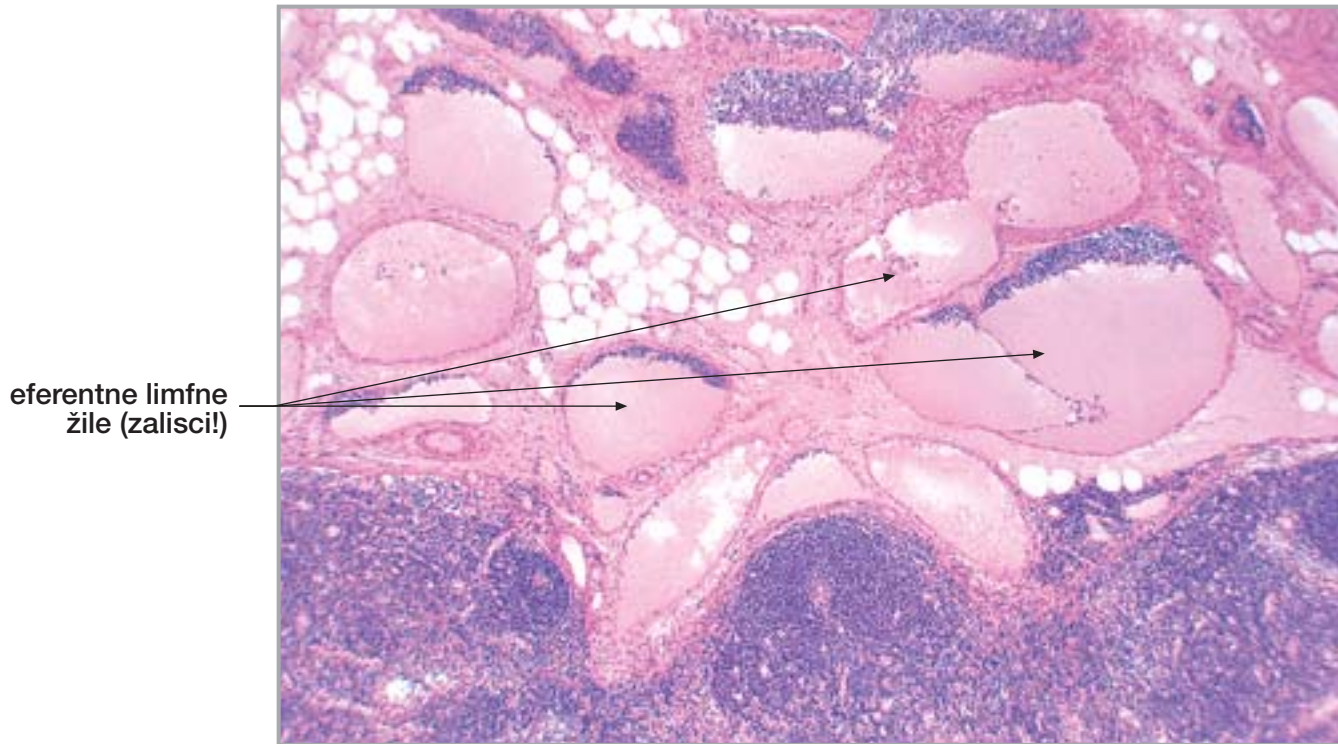
Sl. 306.

Limfni čvor (srž)



32. LIMFNI ČVOR, SLEZENA I TIMUS

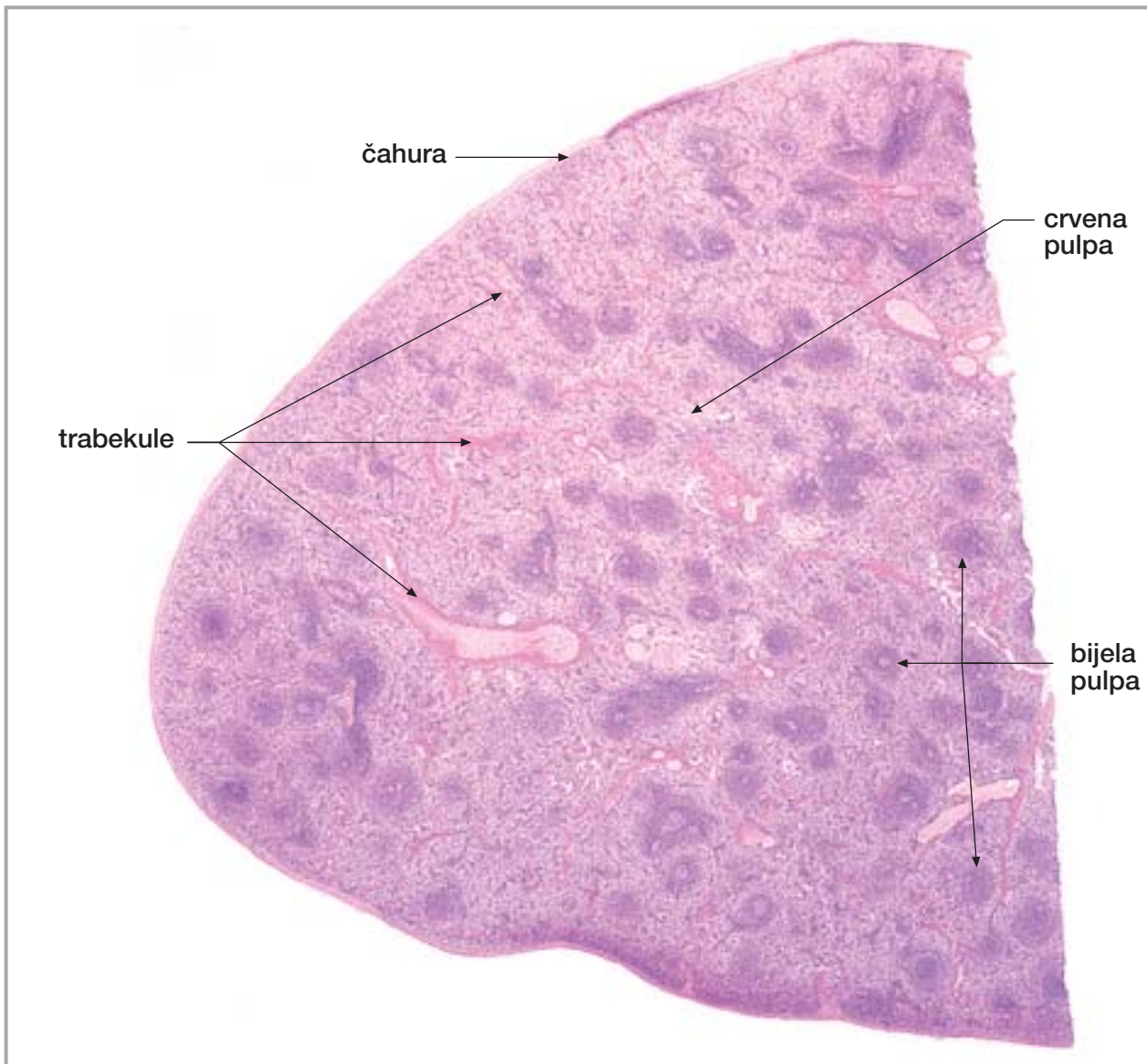
nastavak



eferentne limfne žile (zalisci!)

Sl. 307.

Limfni čvor
(hilus)



Sl. 308.

Slezena

čahura

crvena pulpa

trabekule

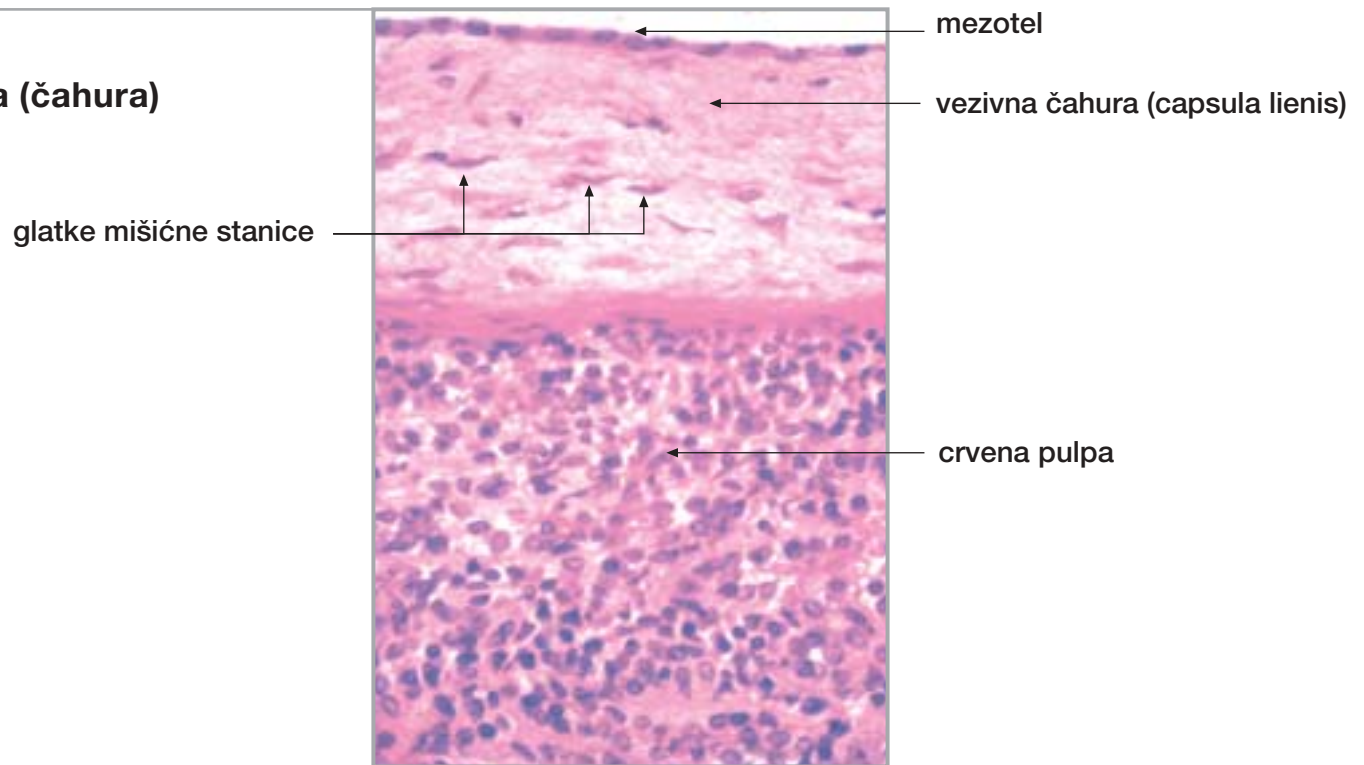
bijela pulpa

32. LIMFNI ČVOR, SLEZENA I TIMUS

nastavak

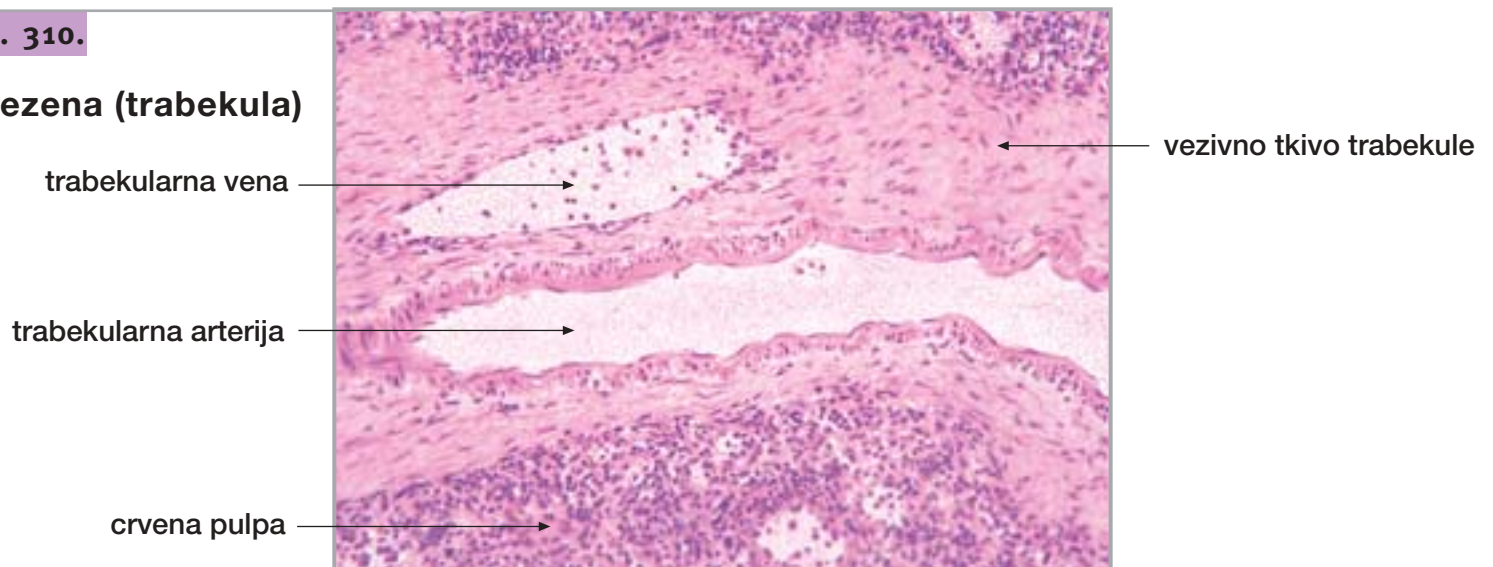
Sl. 309.

Slezena (čahura)



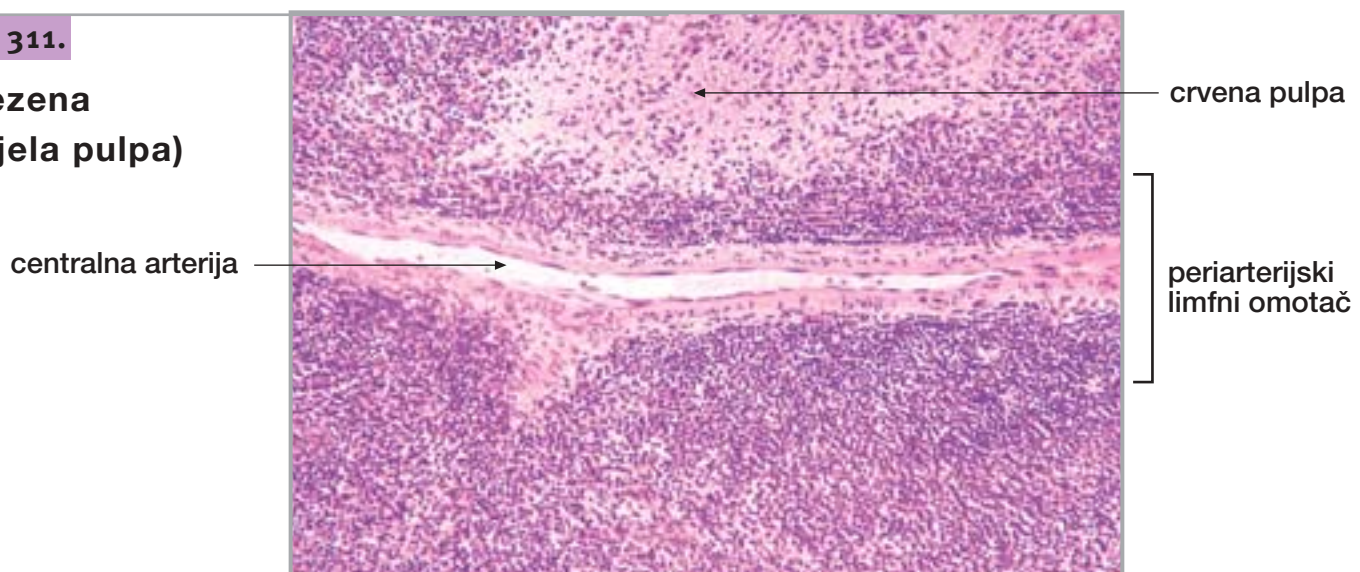
Sl. 310.

Slezena (trabekula)



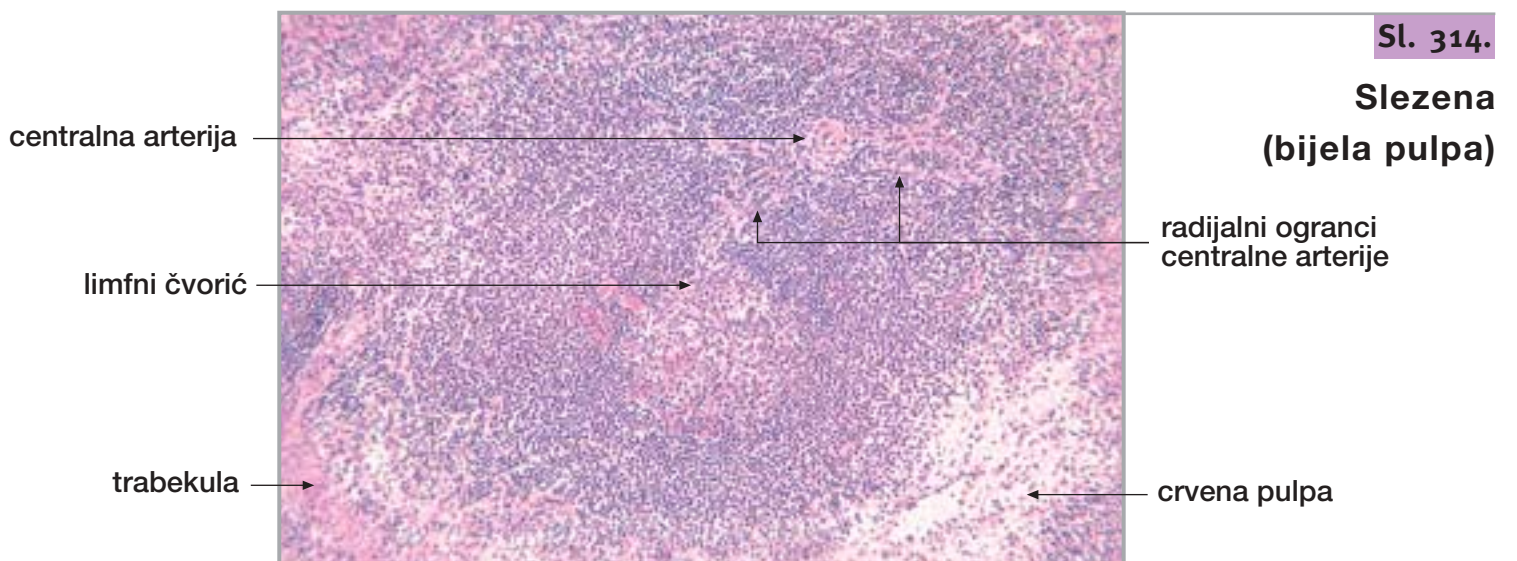
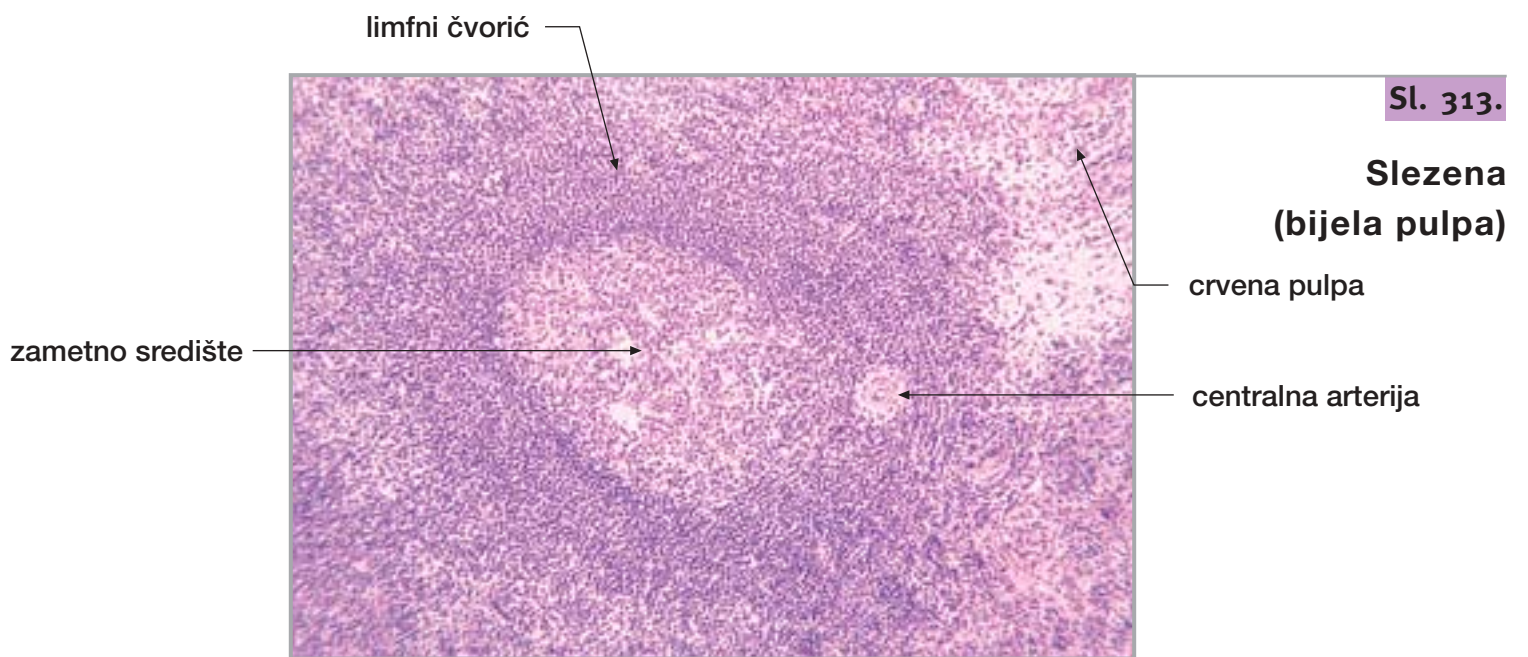
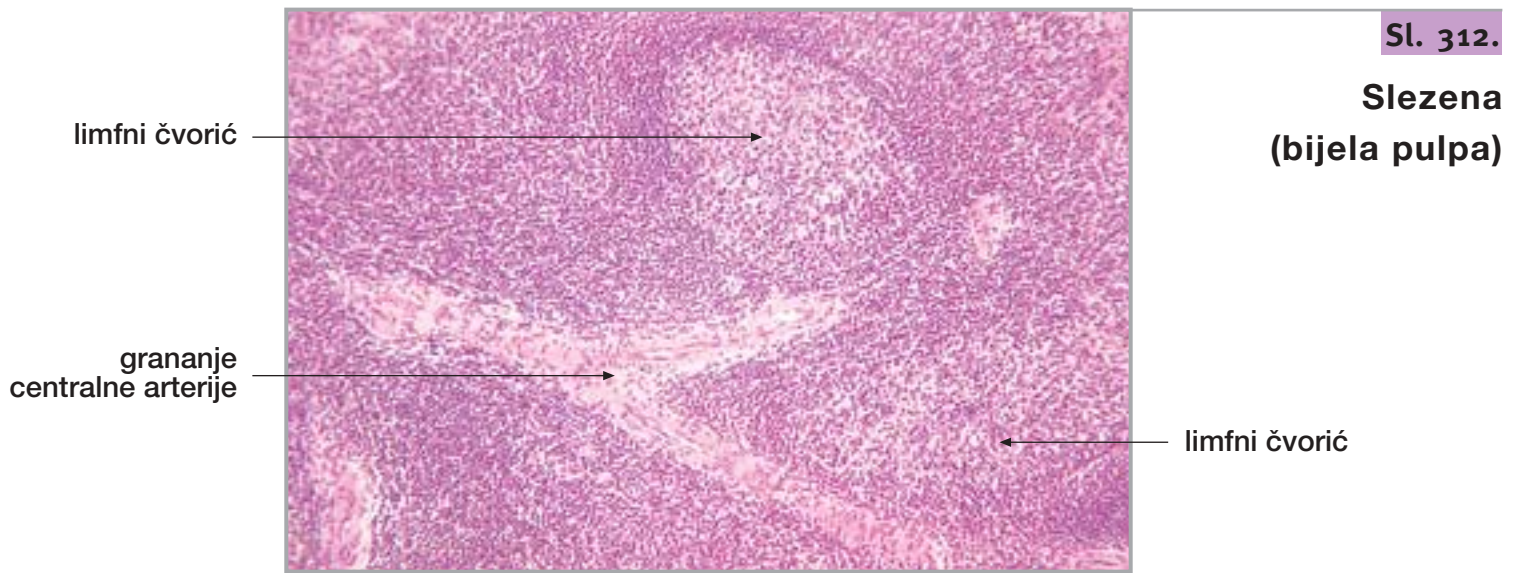
Sl. 311.

Slezena
(bijela pulpa)



32. LIMFNI ČVOR, SLEZENA I TIMUS

nastavak

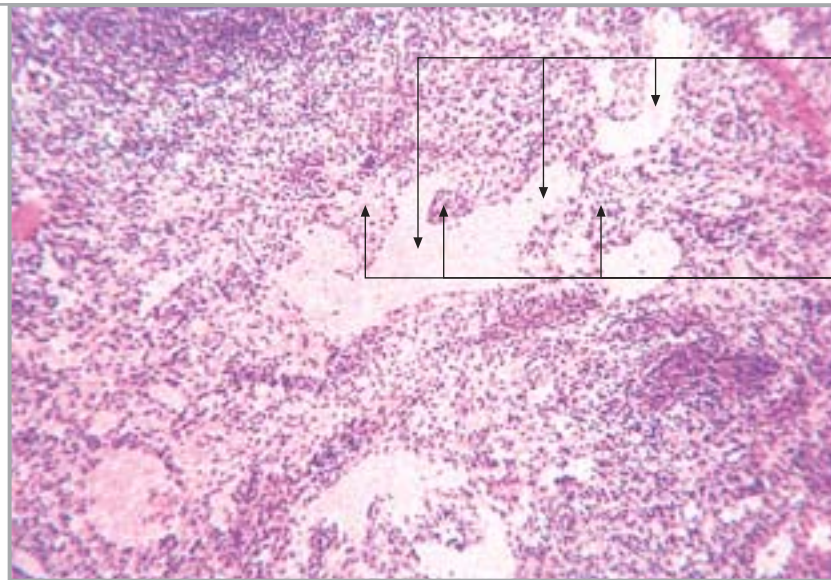


32. LIMFNI ČVOR, SLEZENA I TIMUS

nastavak

Sl. 315.

Slezena
(crvena pulpa)

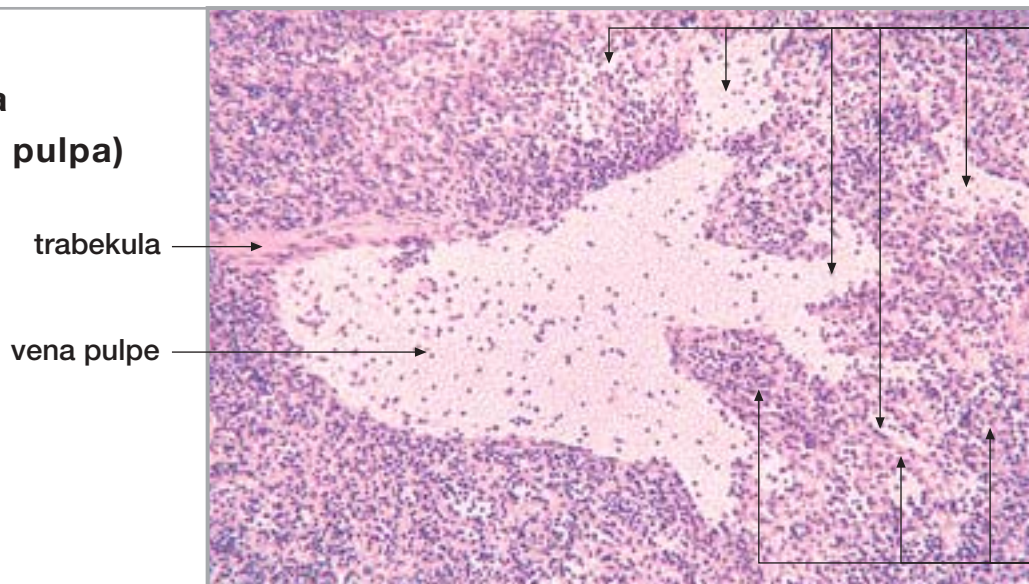


venski sinus

Billrothov tračak

Sl. 316.

Slezena
(crvena pulpa)



venski sinus

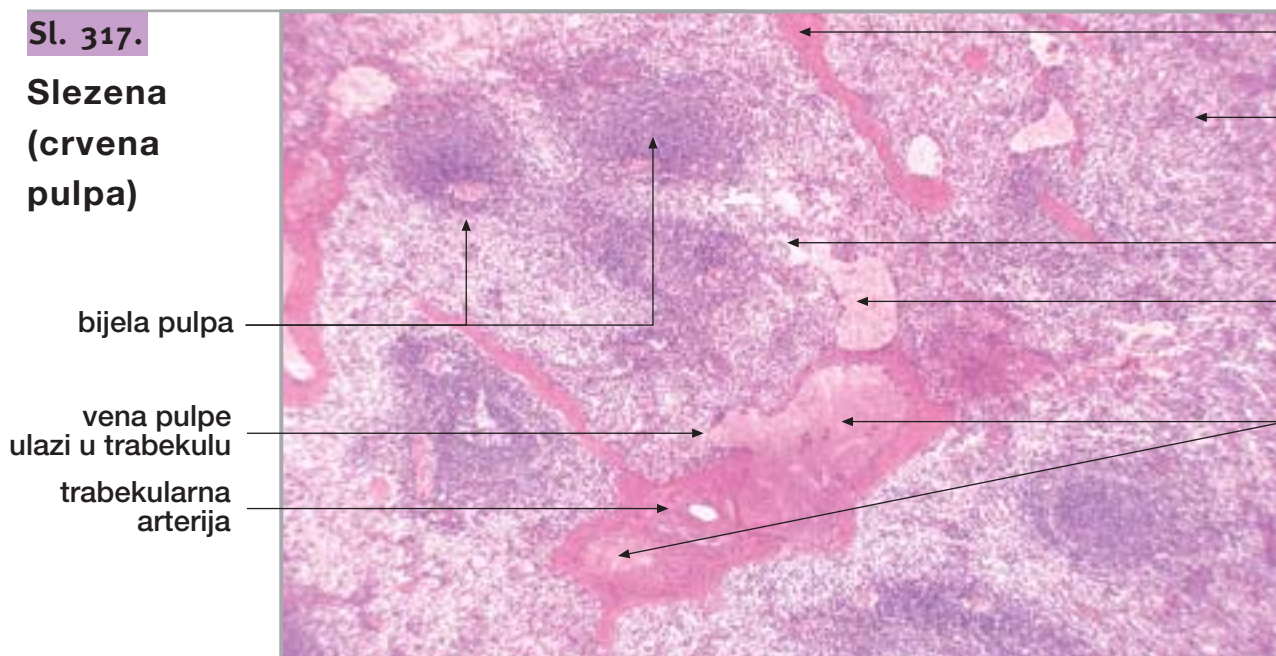
trabekula

vena pulpe

Billrothov tračak

Sl. 317.

Slezena
(crvena pulpa)



trabekula

crvena pulpa

venski sinus

vena pulpe

trabekularna vena

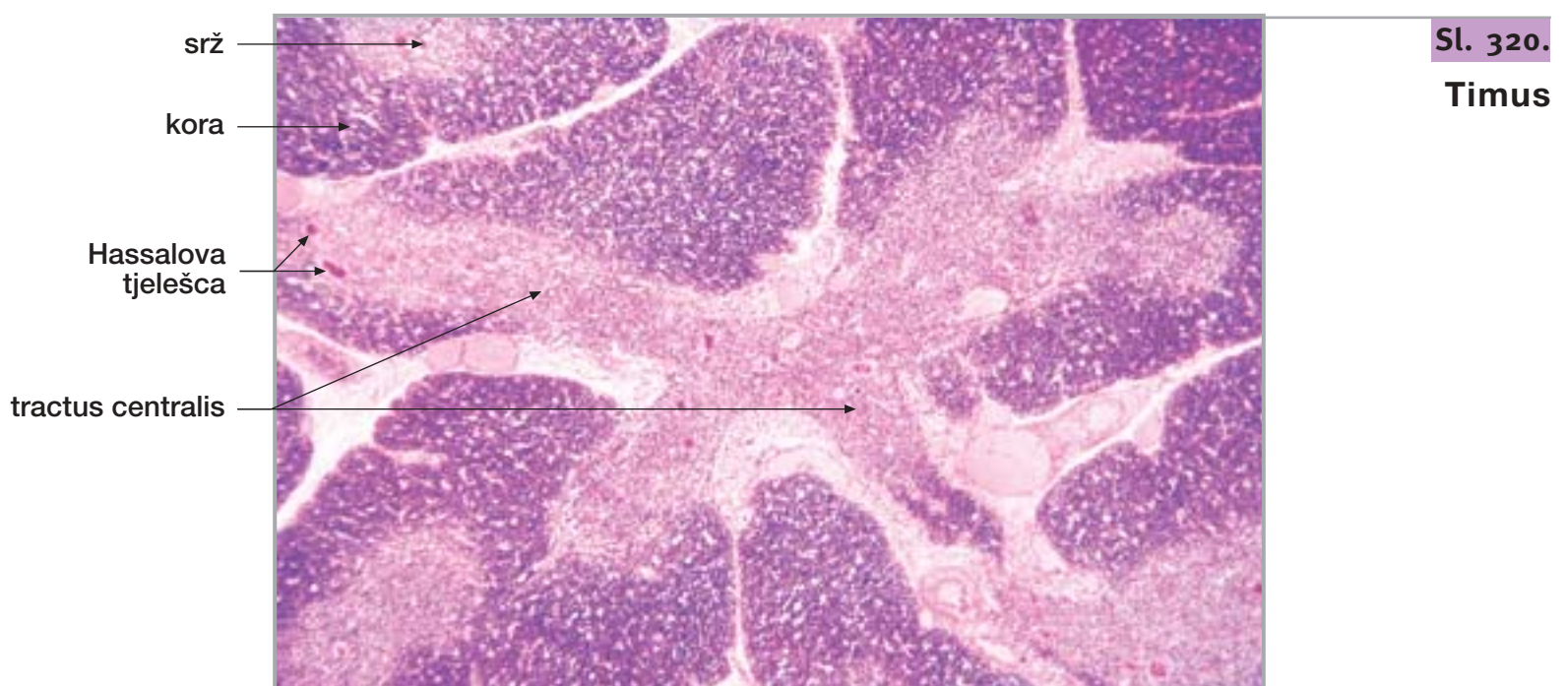
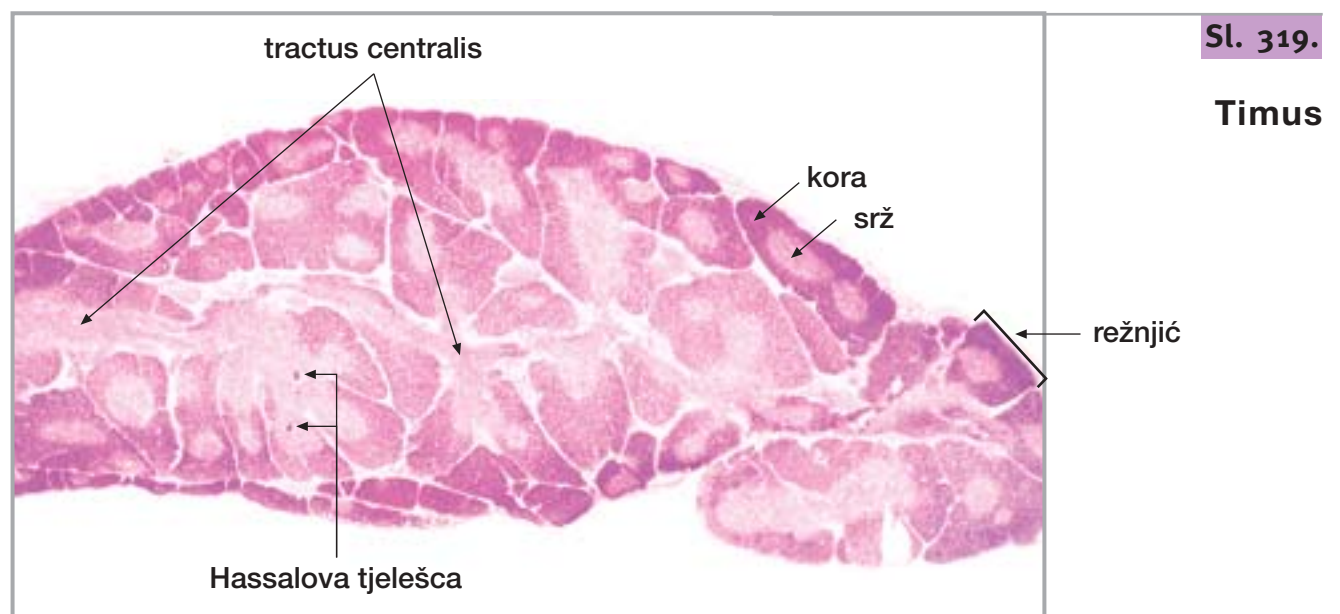
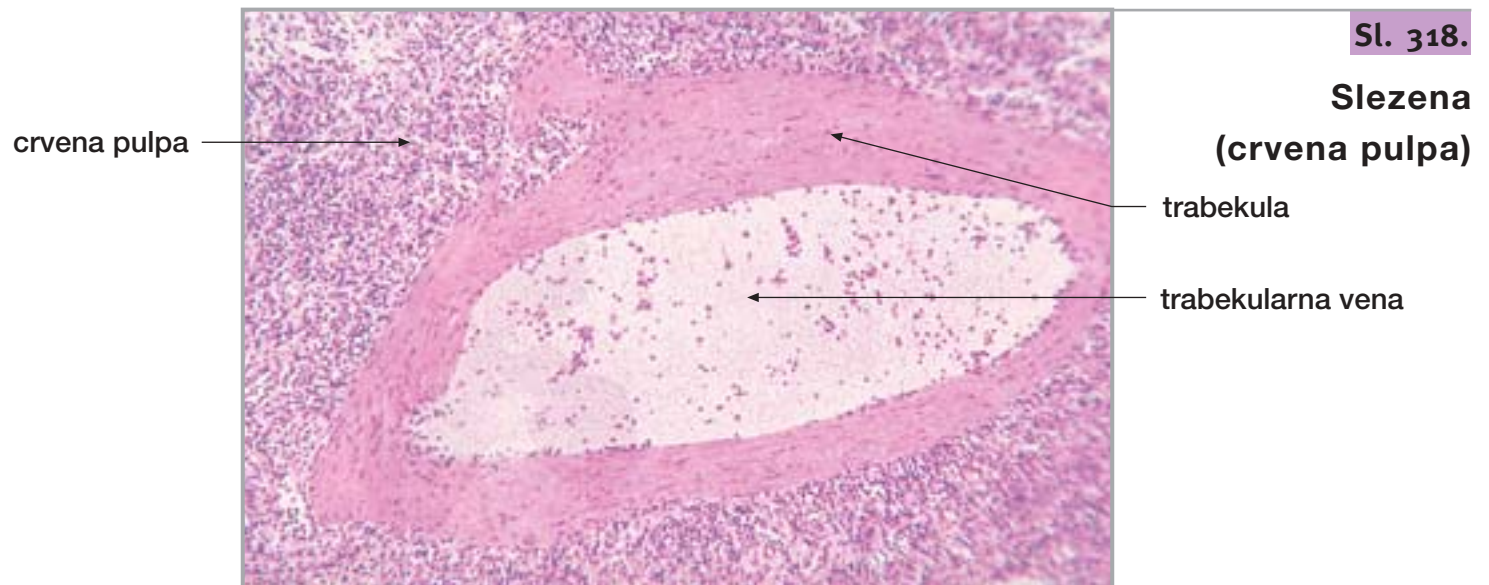
bijela pulpa

vena pulpe
ulazi u trabekulu

trabekularna
arterija

32. LIMFNI ČVOR, SLEZENA I TIMUS

nastavak

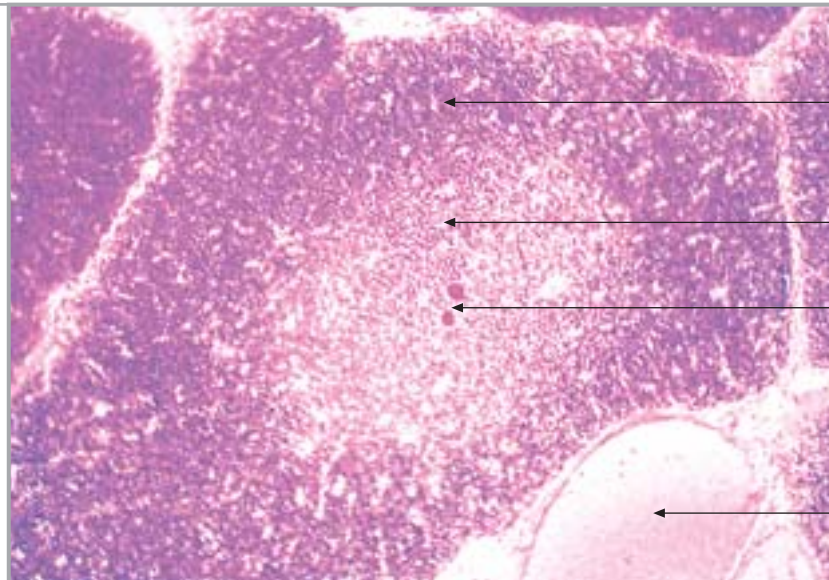


32. LIMFNI ČVOR, SLEZENA I TIMUS

nastavak

Sl. 321.

Timus (režnjić)



kora

srž

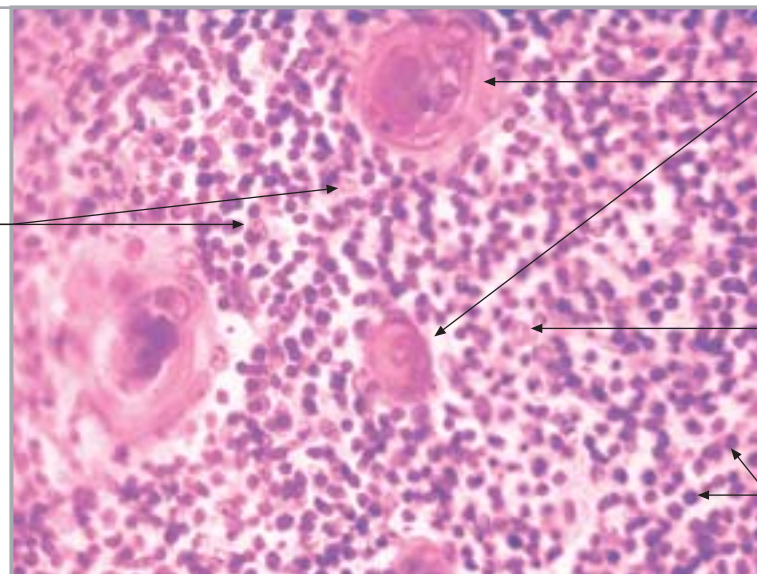
Hassalova tjelešca

vena

Sl. 322.

Timus (srž)

epitelna retikularna stanica



Hassalovo tjelešce

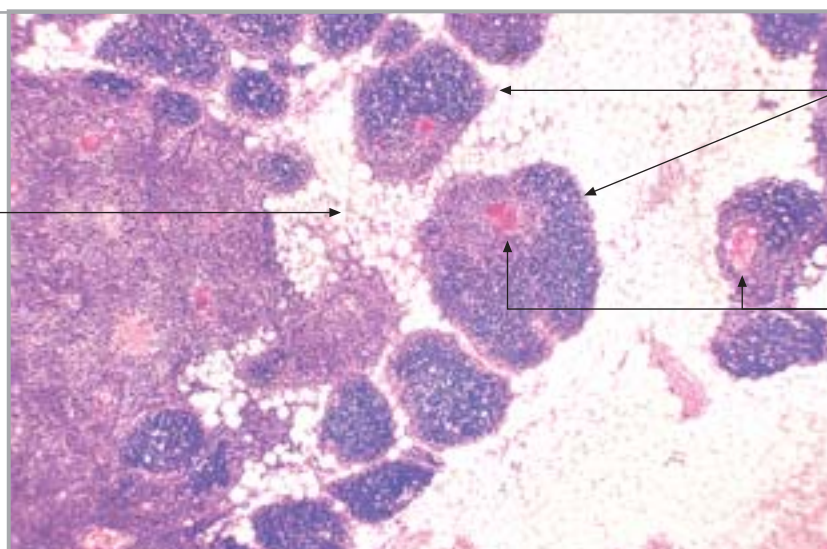
epitelna retikularna stanica

T-limfociti

Sl. 323.

Timus (involucija)

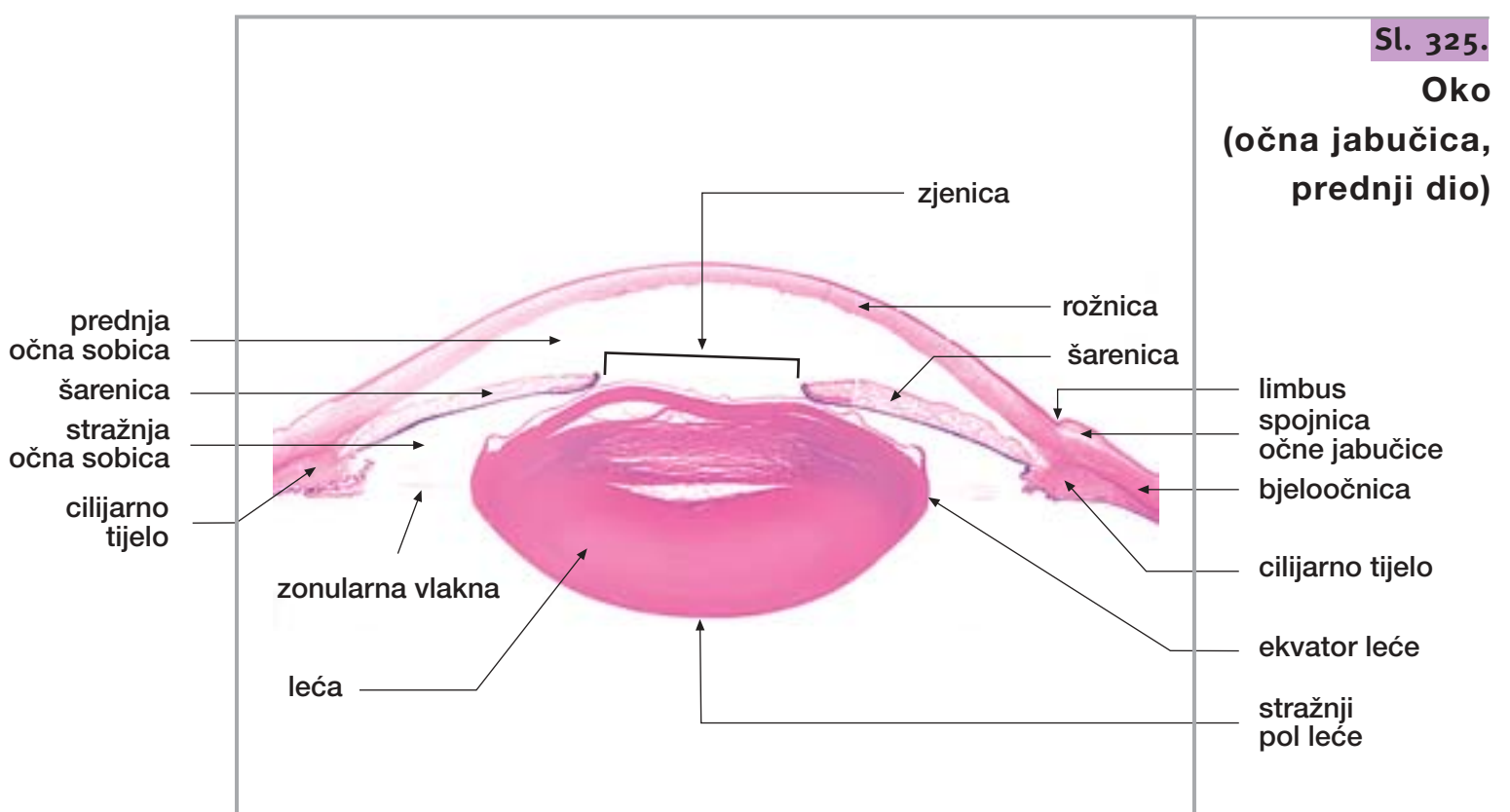
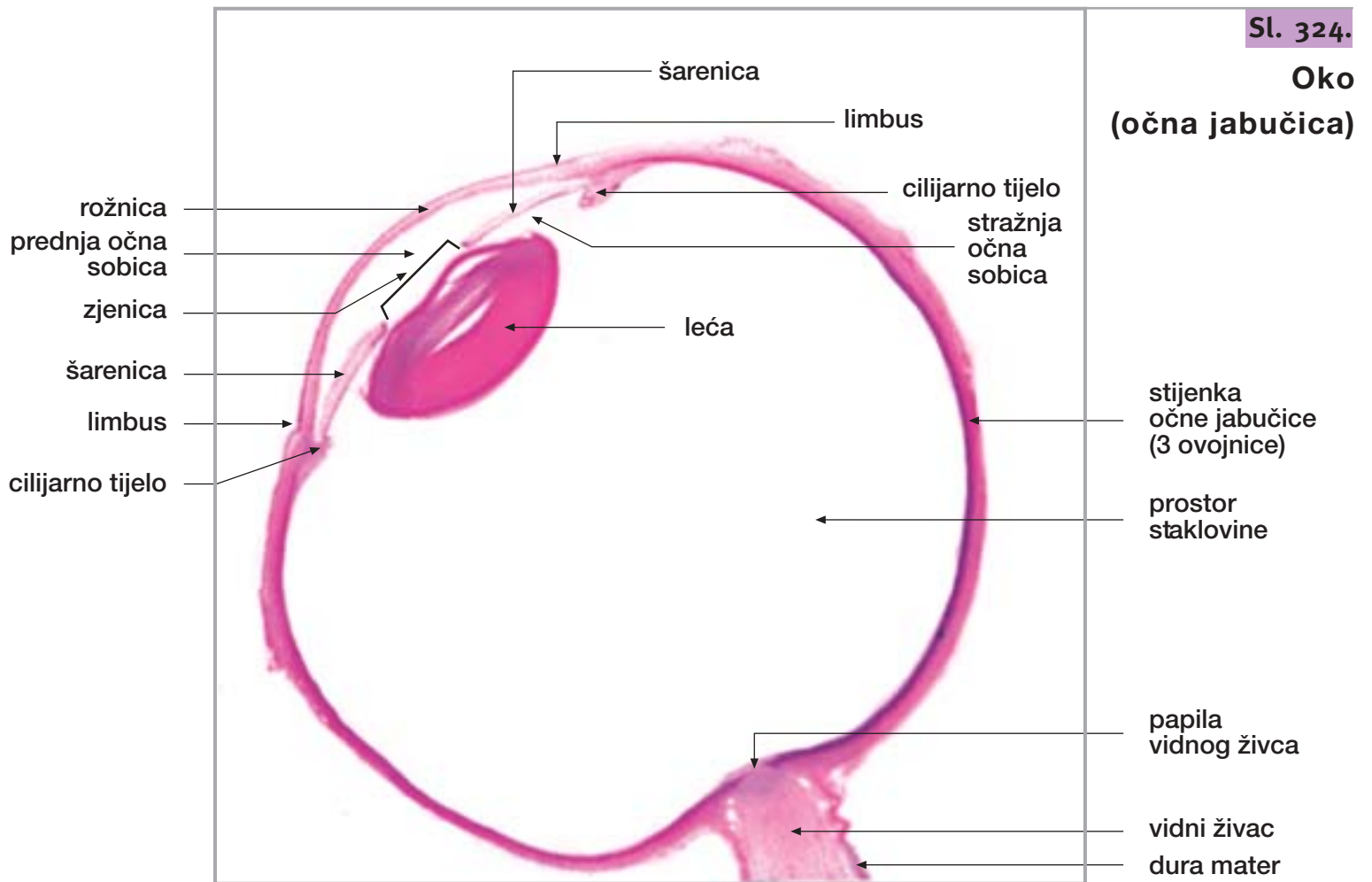
masno tkivo



režnjići

Hassalovo tjelešce

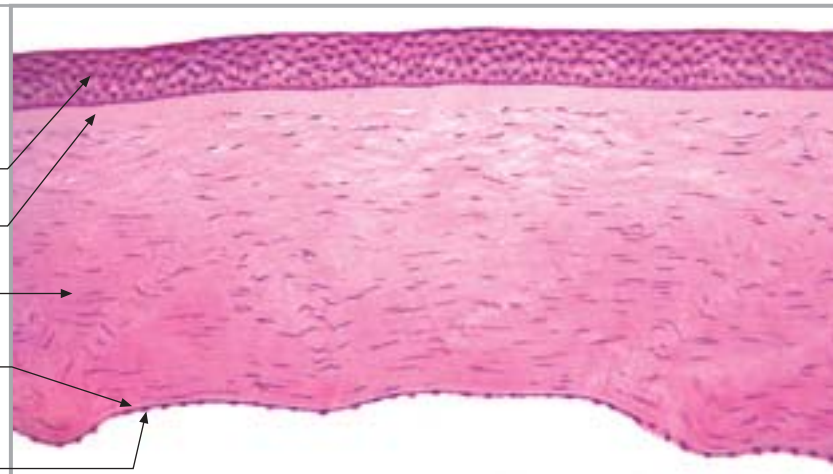
33. OKO



Sl. 326.

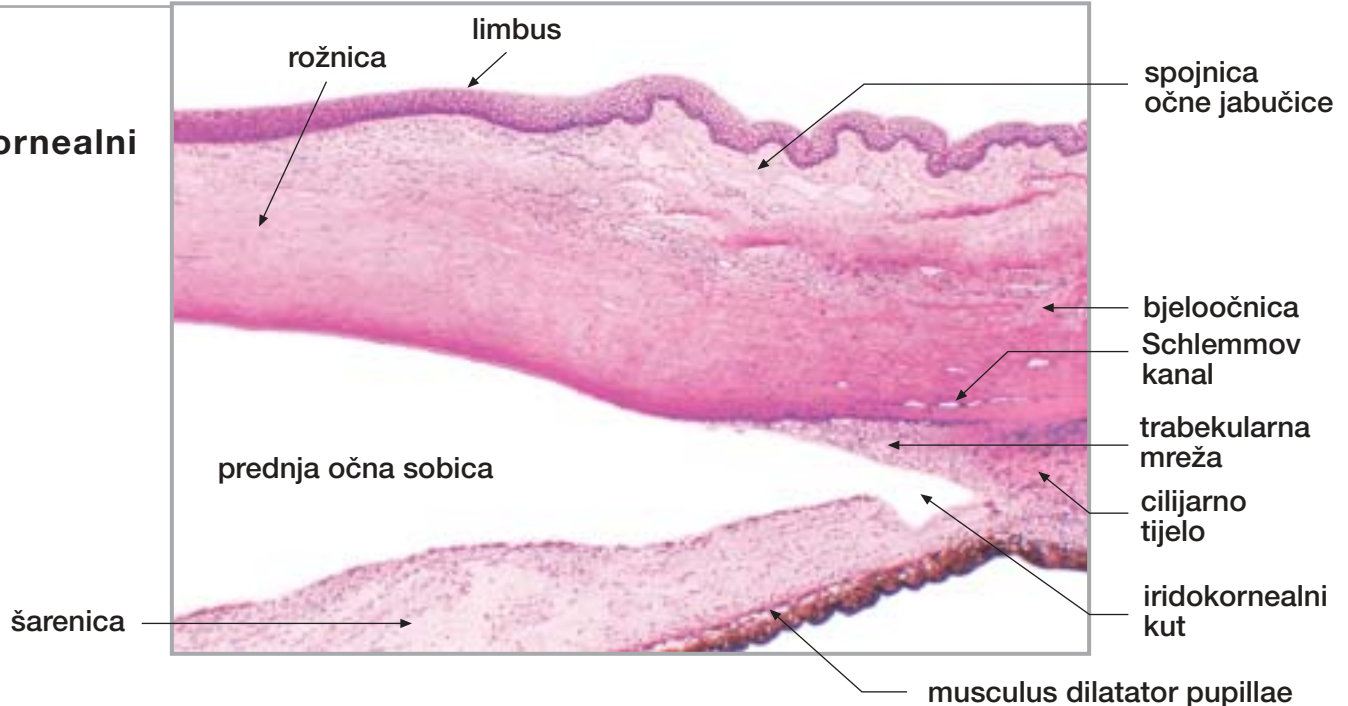
Oko (rožnica)

epitel
Bowmanova membrana
stroma
Descemetova membrana
endotel



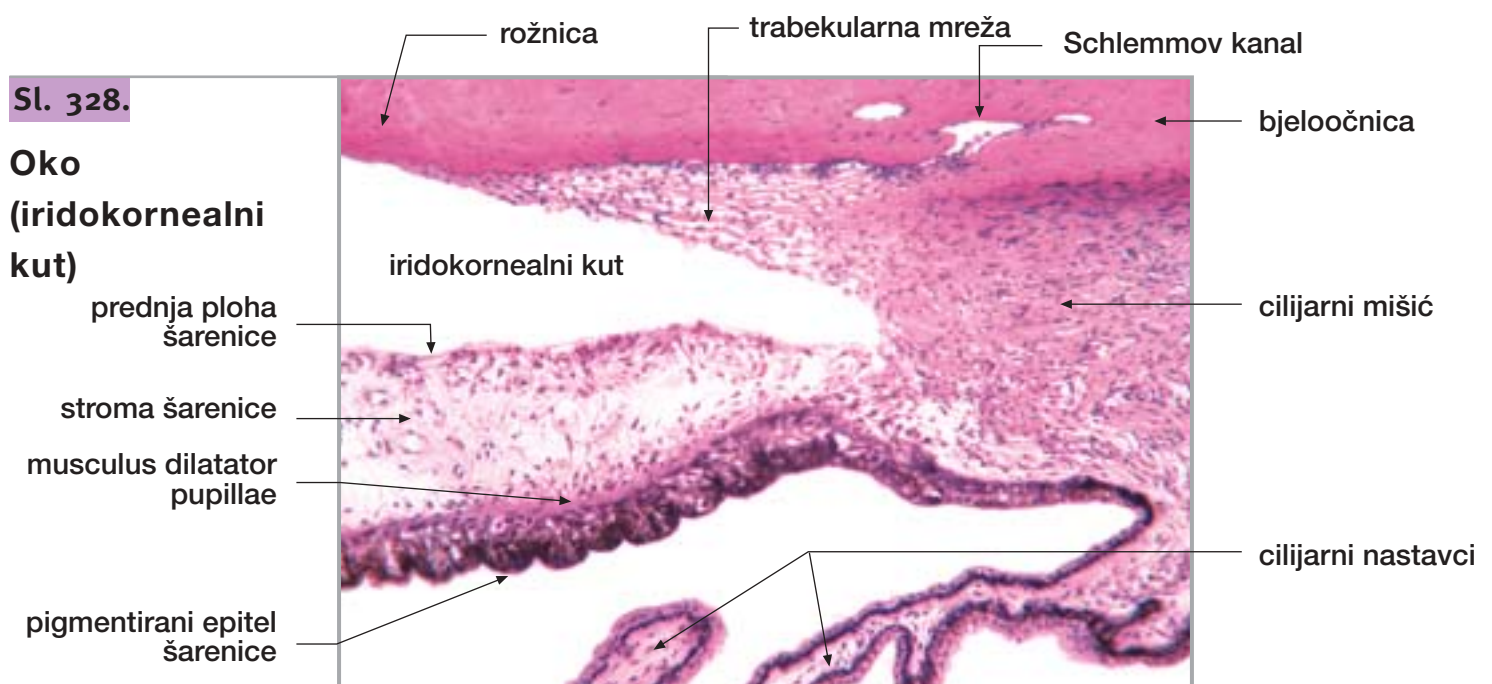
Sl. 327.

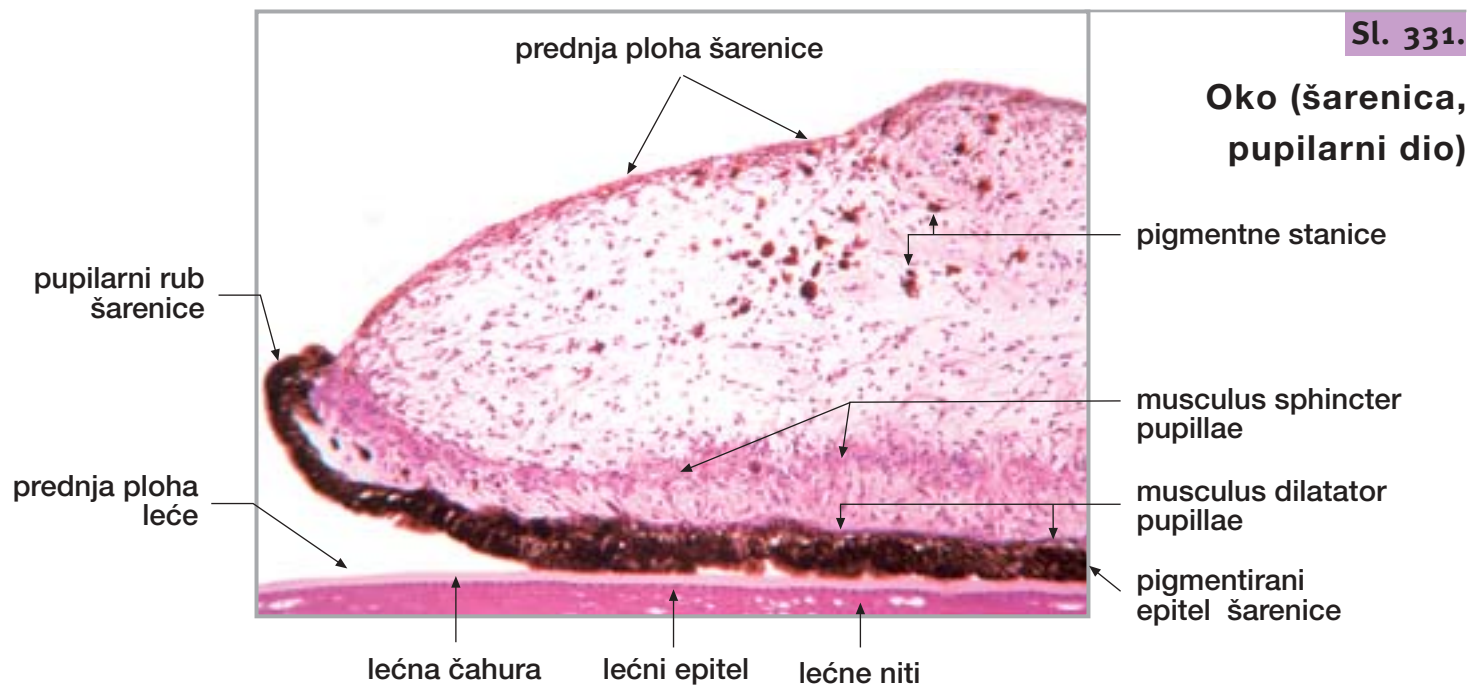
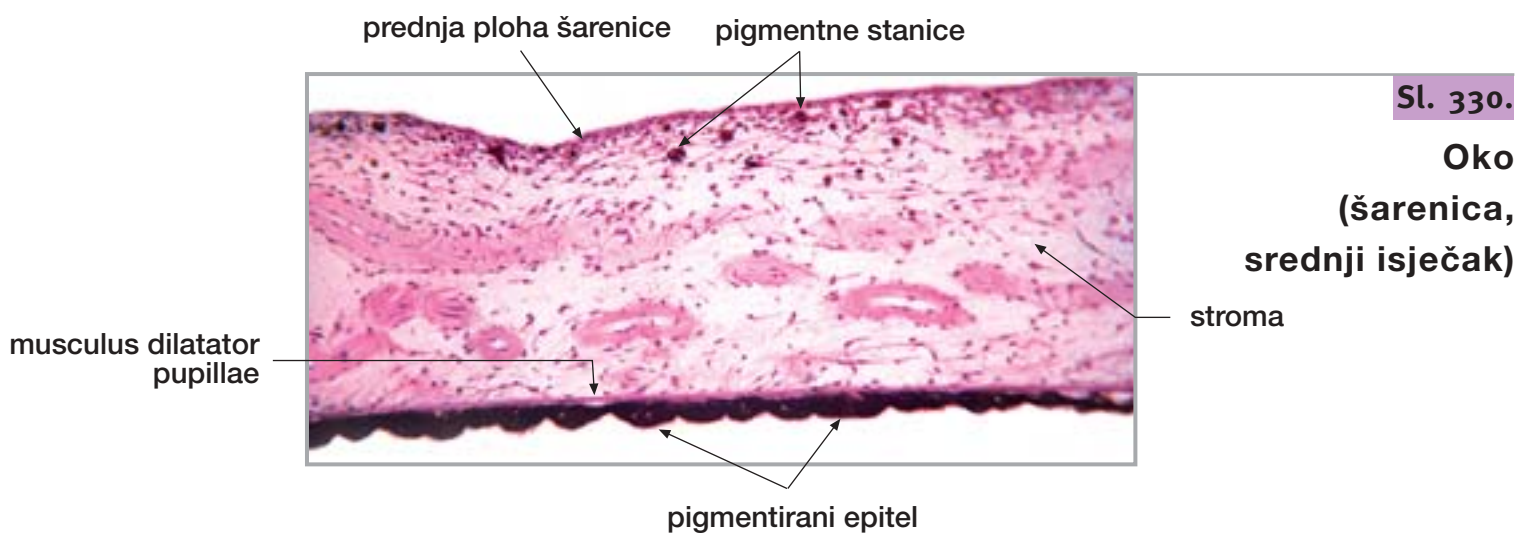
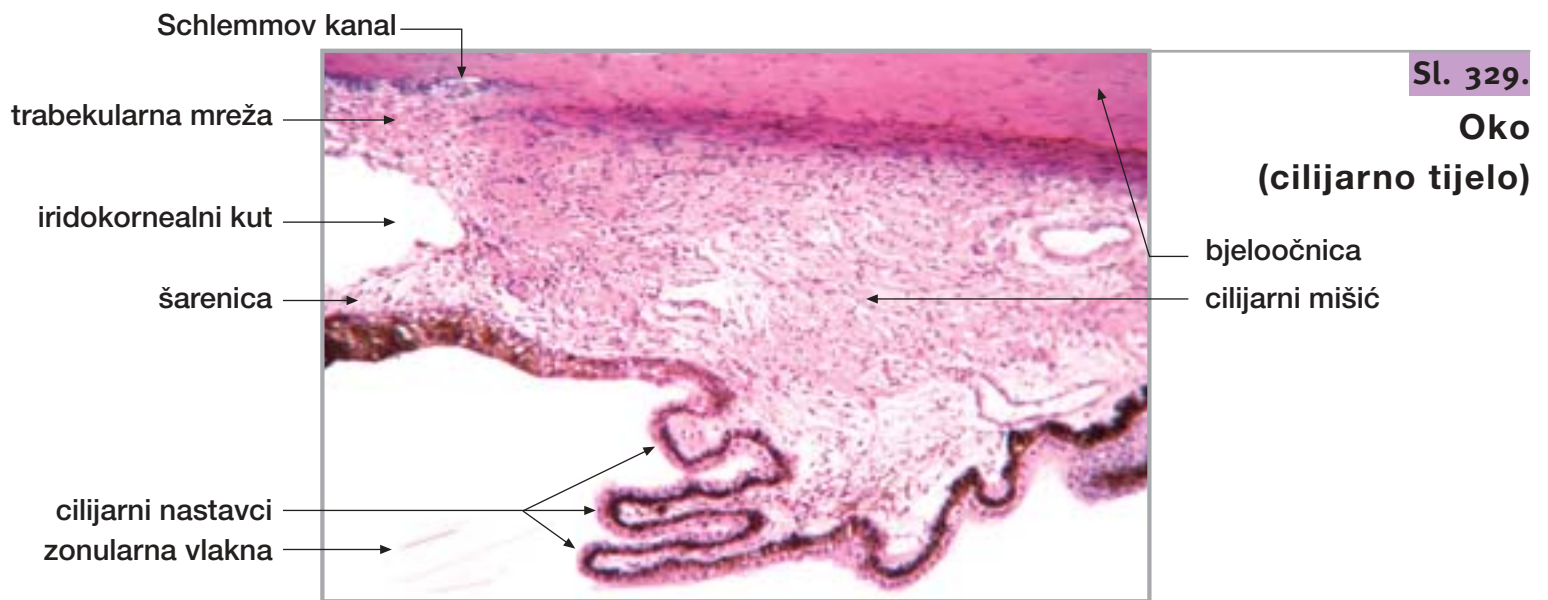
Oko (iridokornealni kut)



Sl. 328.

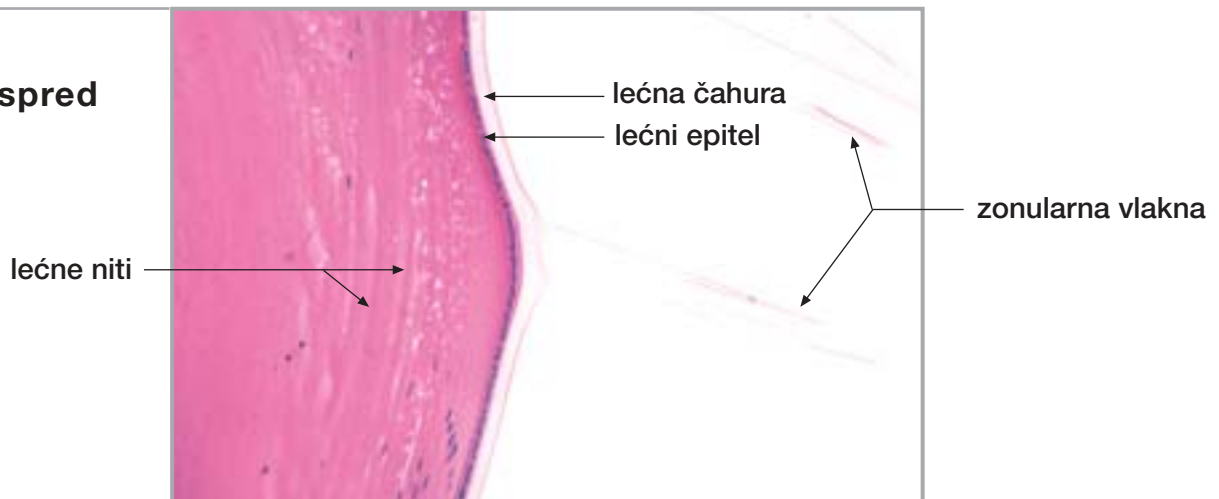
Oko (iridokornealni kut)





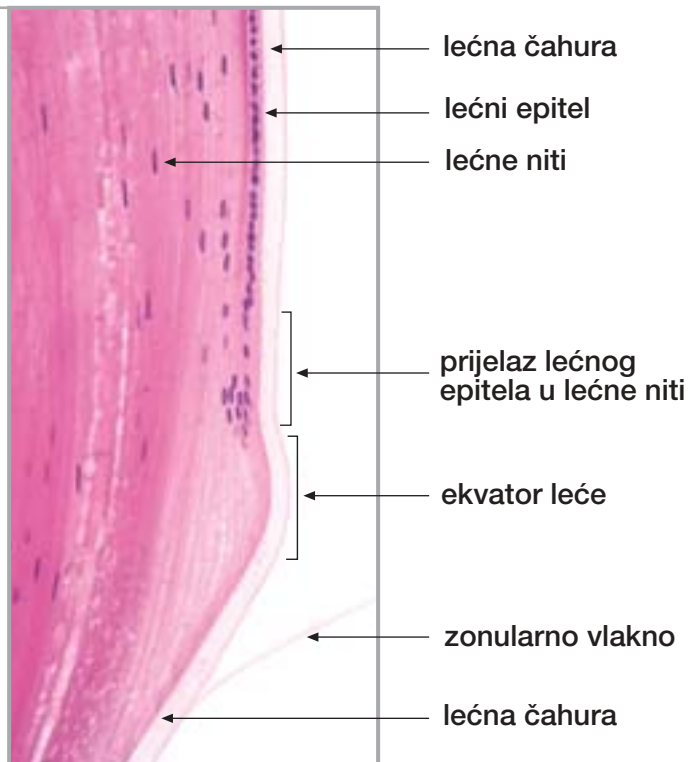
Sl. 332.

Oko (leća, ispred ekvatora)



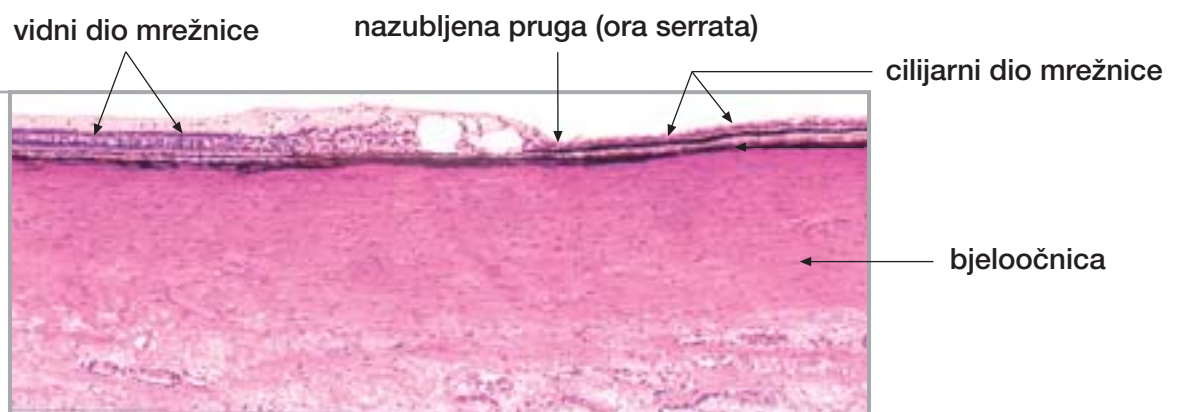Sl. 333.

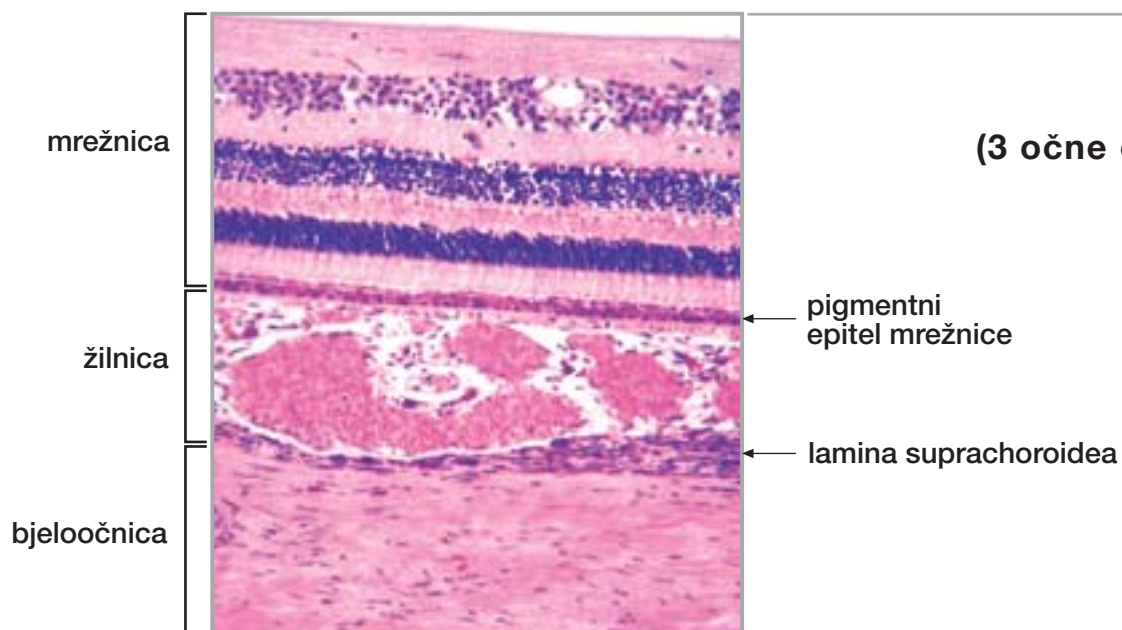
Oko (leća, ekvator)



Sl. 334.

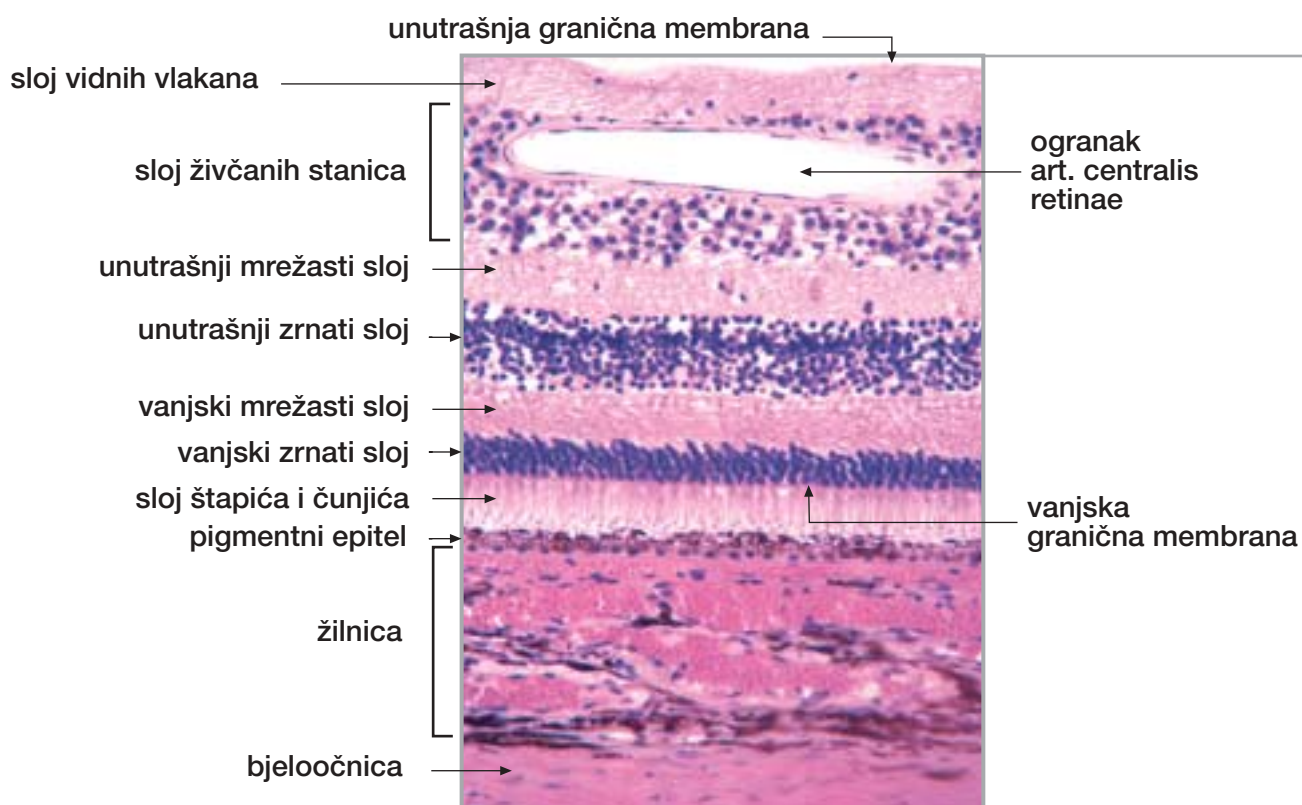
Oko (mrežnica, nazubljena pruga)





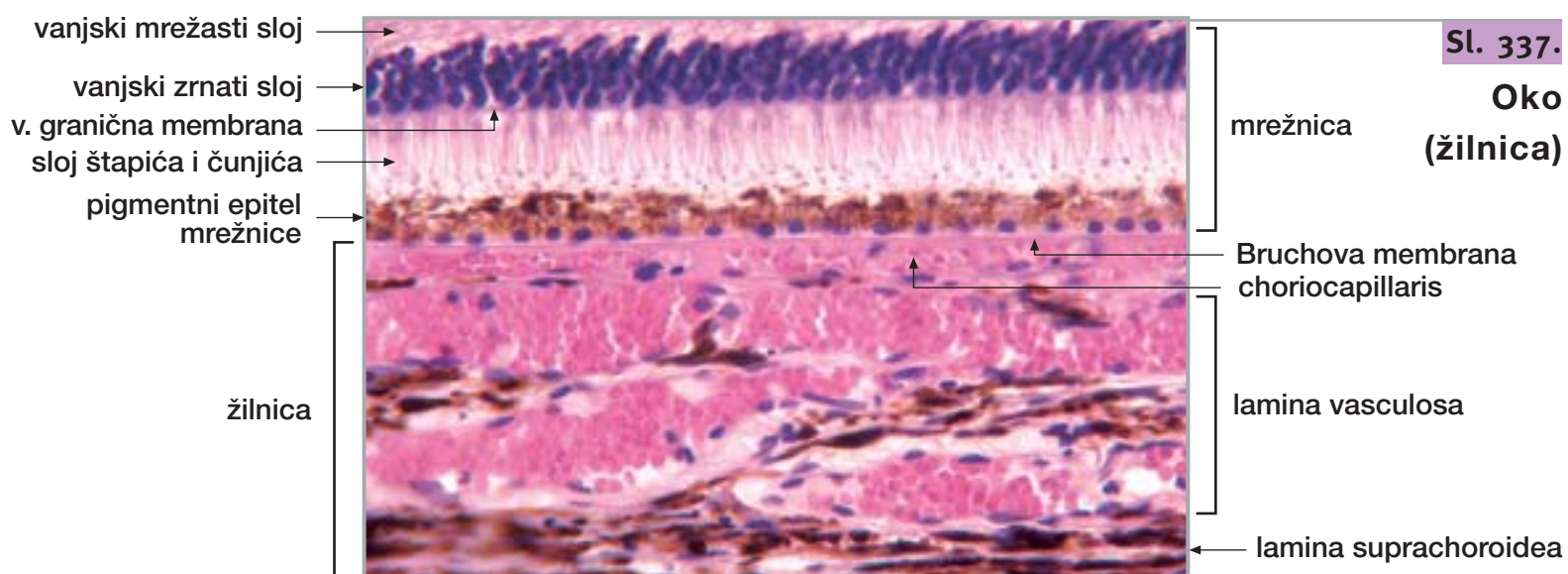
Sl. 335.

Okno
(3 očne ovojnice)



Sl. 336.

Okno
(mrežnica)

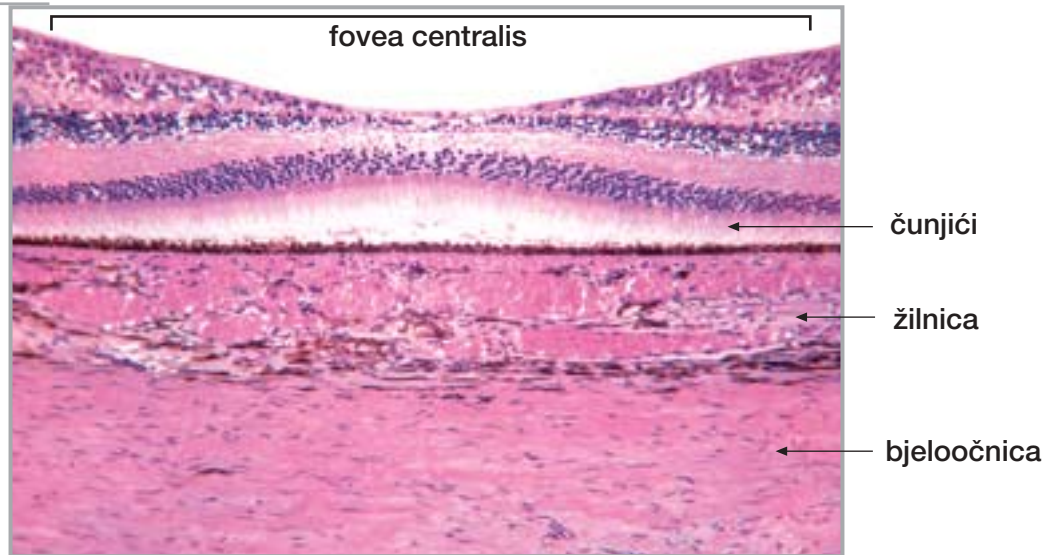


Sl. 337.

Okno
(žilnica)

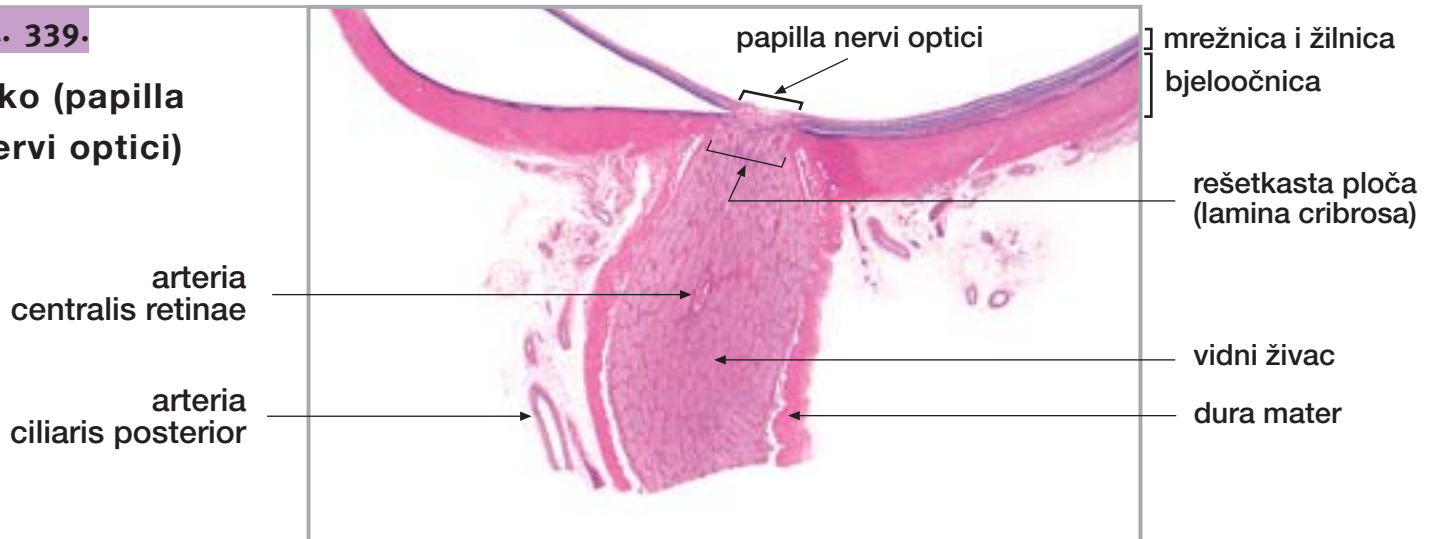
Sl. 338.

Oko
(fovea centralis)



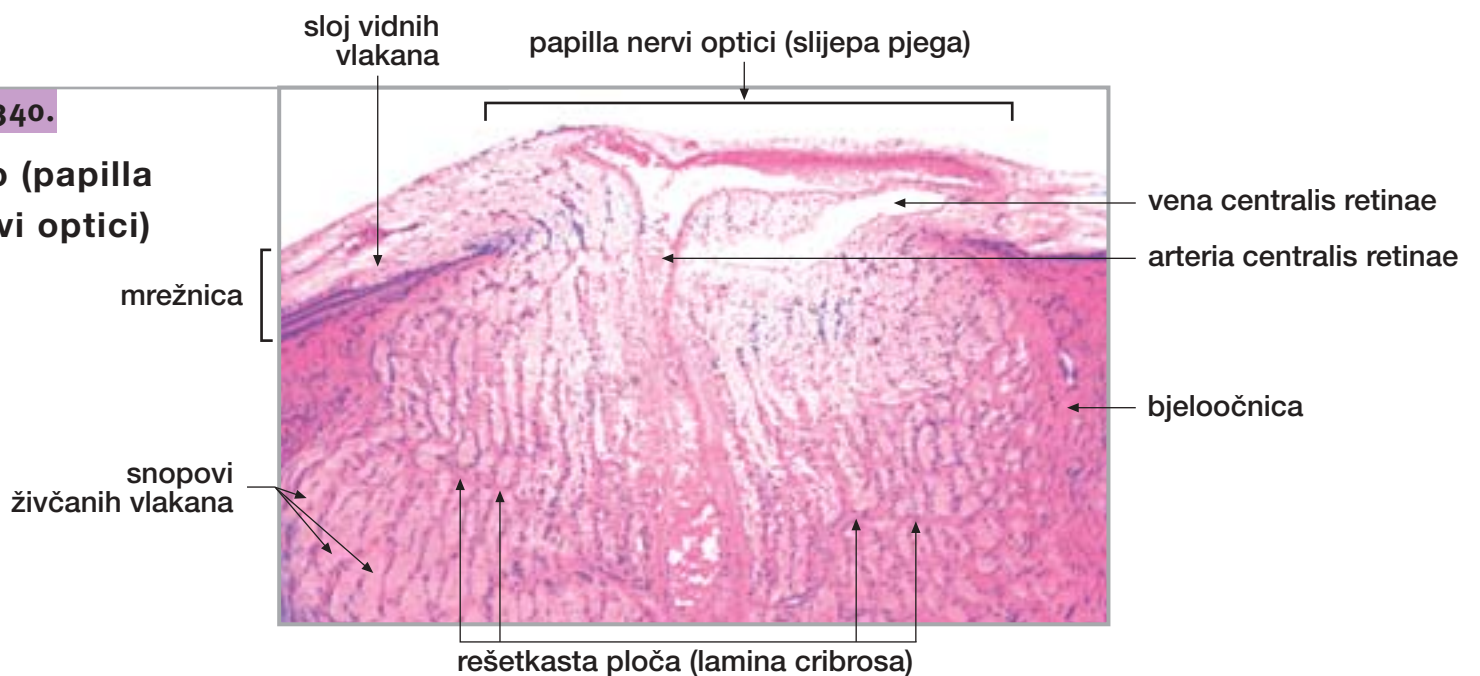
Sl. 339.

Oko (papilla
nervi optici)



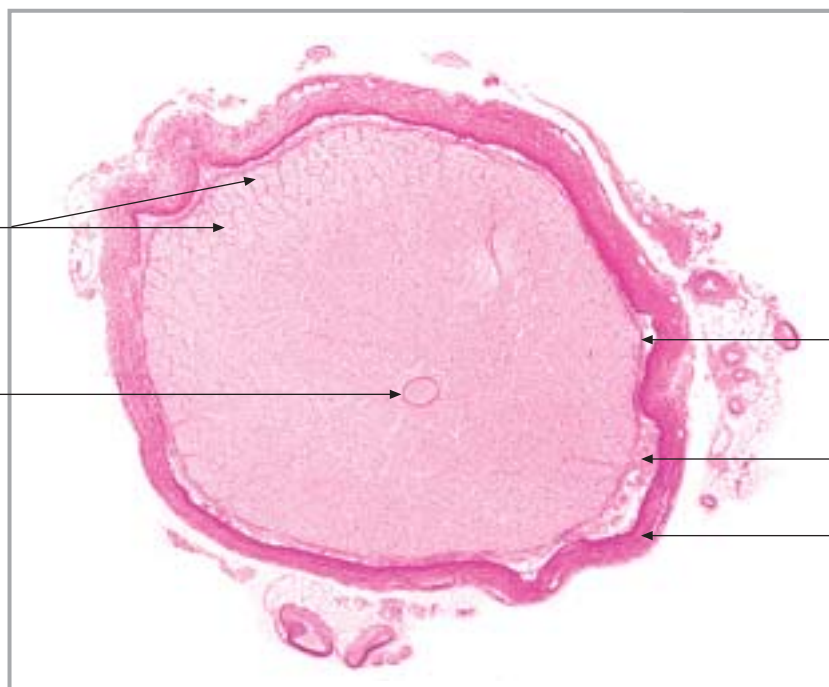
Sl. 340.

Oko (papilla
nervi optici)



snopovi
živčanih vlakana

arteria
centralis retinae



pia mater

arachnoidea

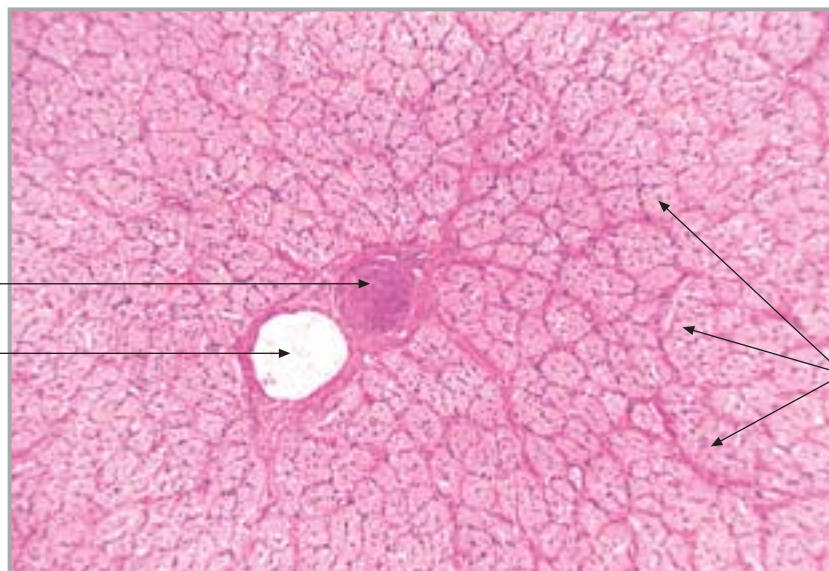
dura mater

Sl. 341.

Okno
(vidni živac)

arteria
centralis retinae

vena
centralis retinae



snopovi
živčanih vlakana

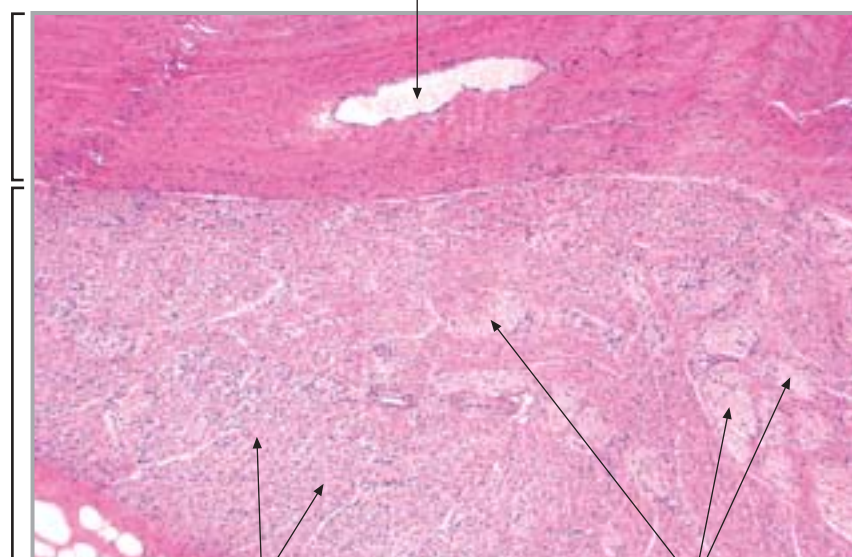
Sl. 342.

Okno
(vidni živac)

vena vorticiosa

bjeloočnica

vanjski očni mišić



mišićna vlakna

snopovi živčanih vlakana

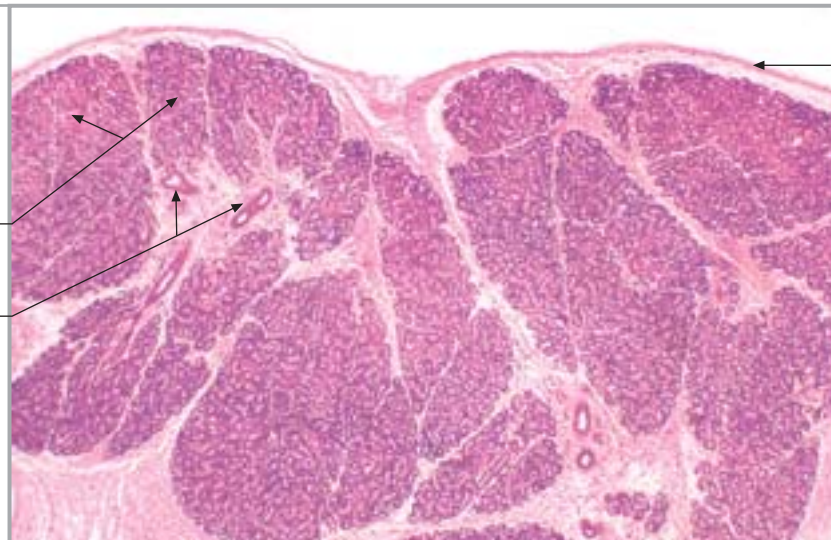
Sl. 343.

Okno
(vanjski očni mišić)

Sl. 344.

Oko (suzna žlijezda)

žljezdani režnjici
odvodni kanali

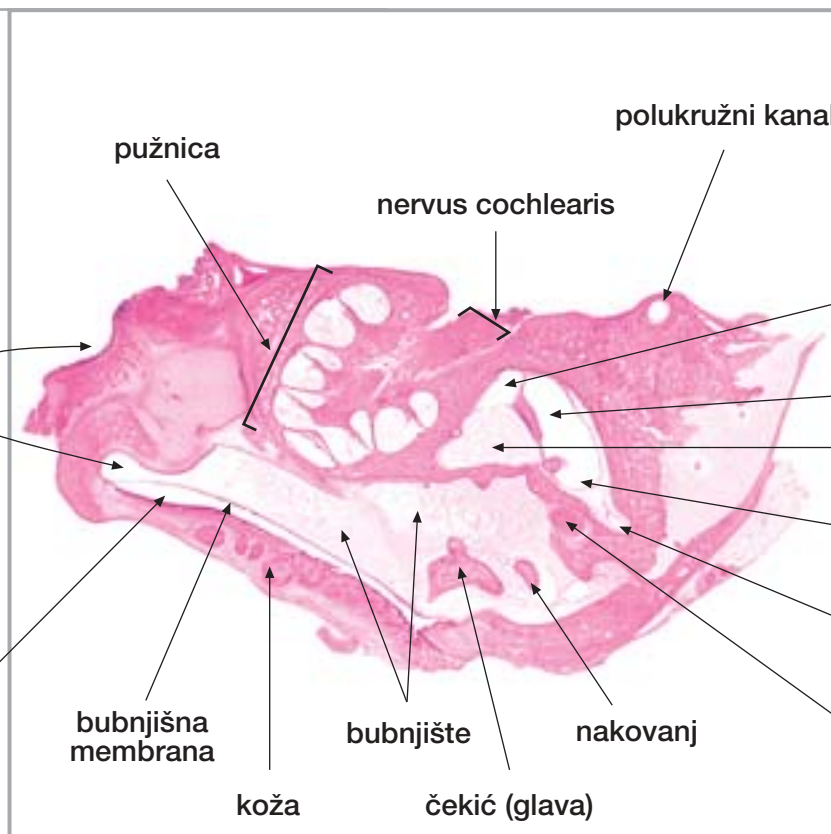


vezivna čahura

Sl. 345.

Uho (presjek uha mlade mačke)

slušna truba
vanjski slušni hodnik (zvukovod)



polukružni kanal

pužnica

nervus cochlearis

sakulus

utrikulus

perilimfatički prostor predvorja

ampula polukružnog kanala

polukružni kanal

nervus facialis

bubnjišna membrana

koža

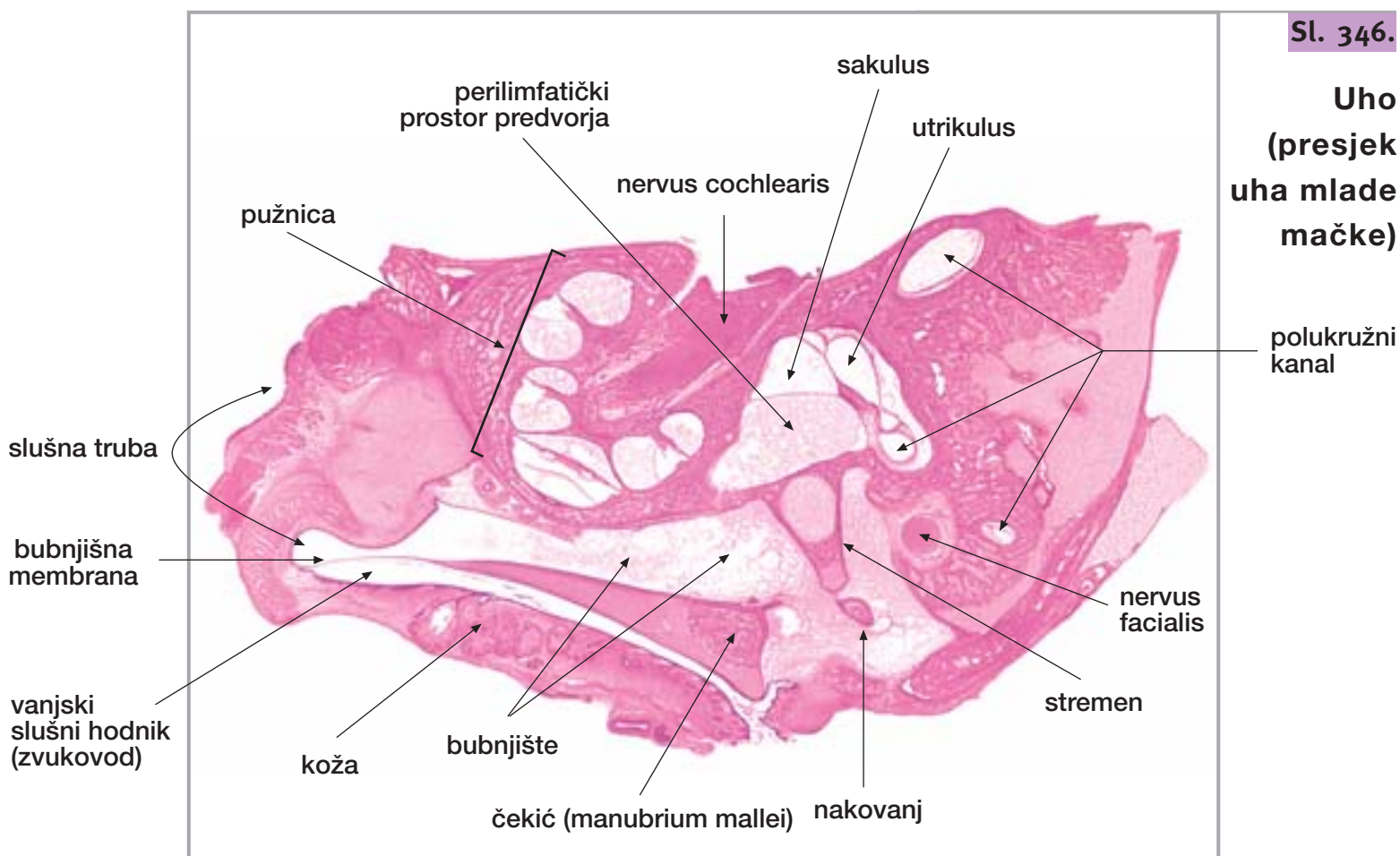
bubnjište

nakovanj

čekić (glava)

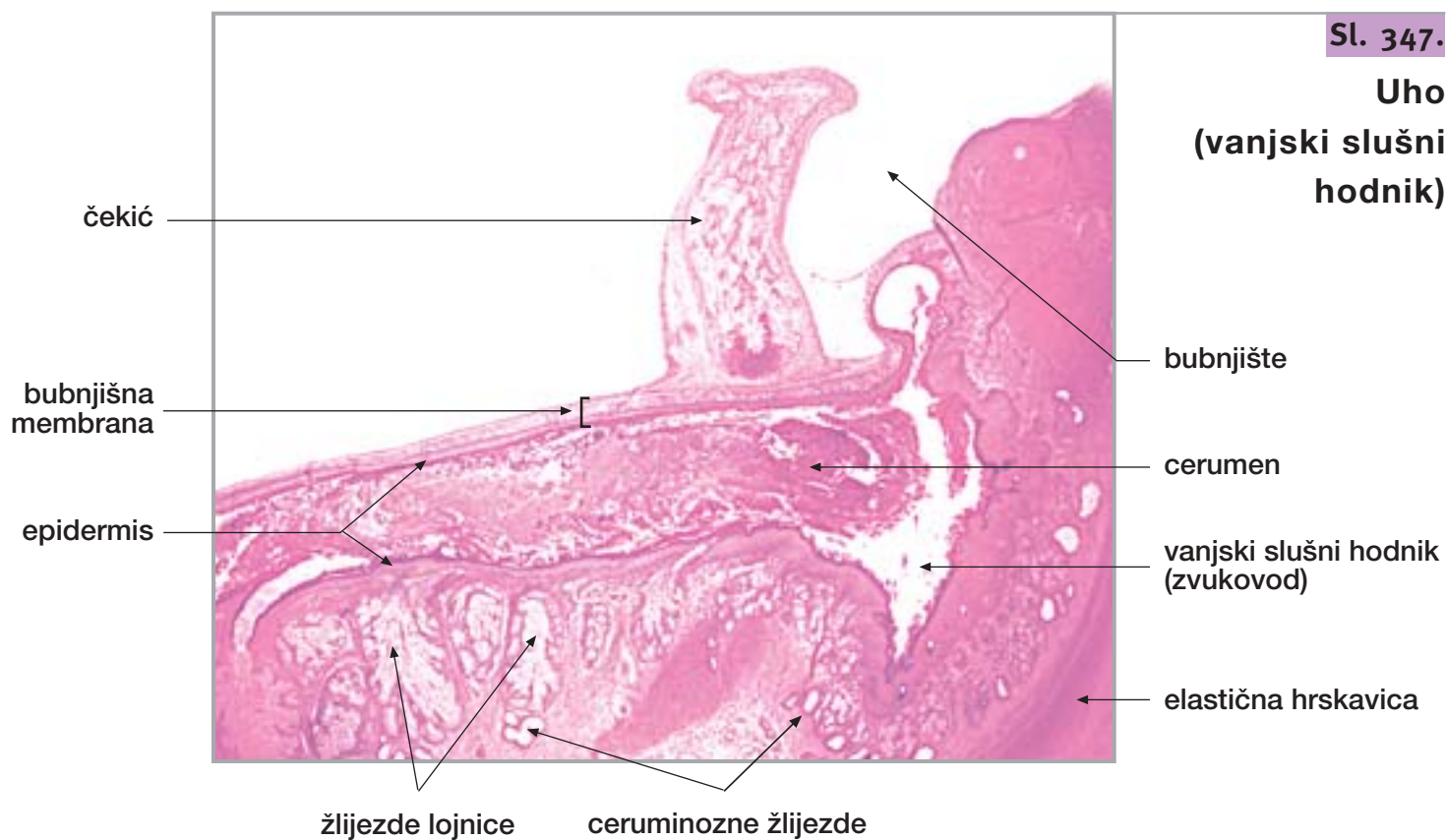
Sl. 346.

Uho (presjek uha mlade mačke)



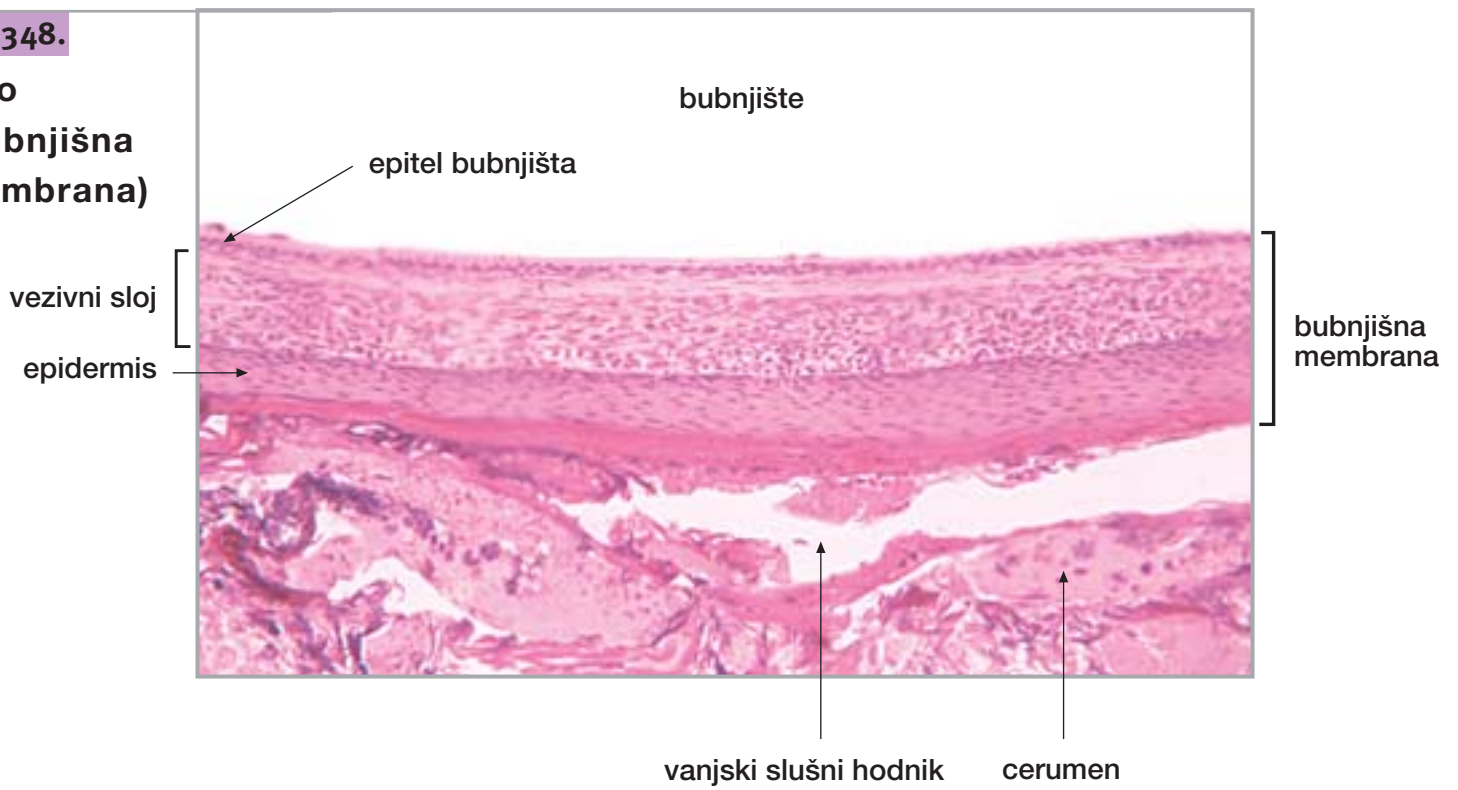
Sl. 347.

Uho (vanjski slušni hodnik)



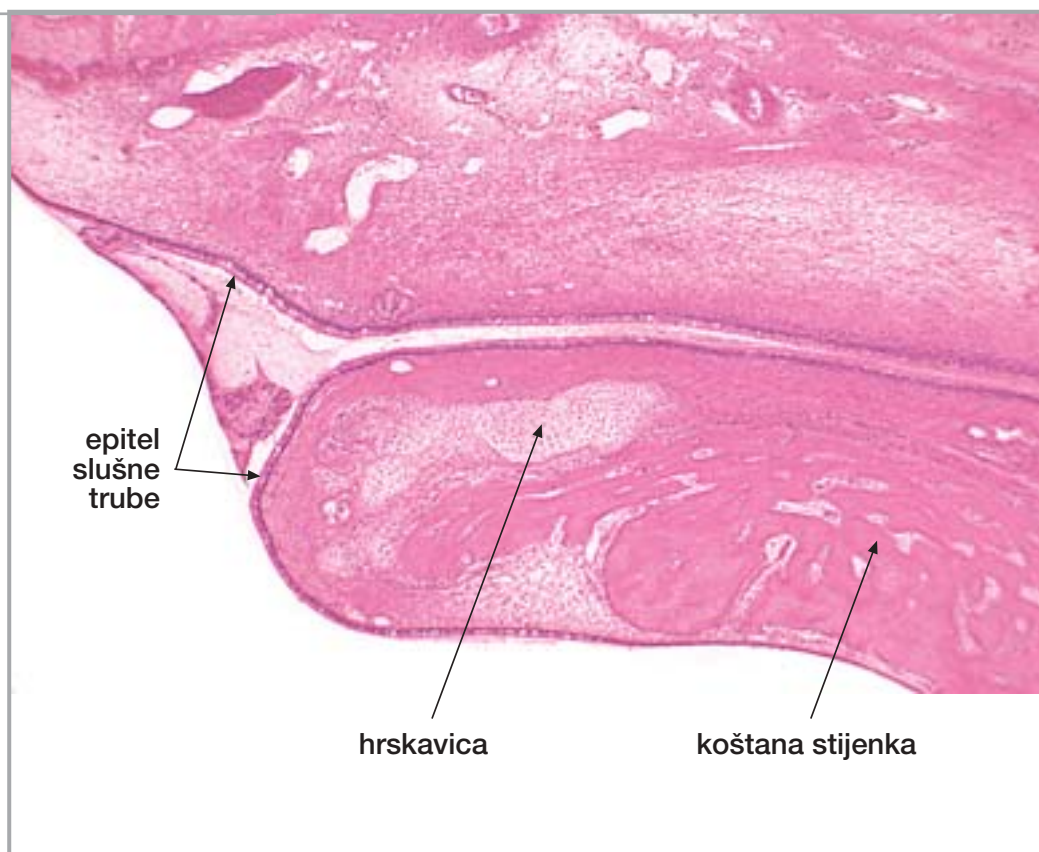
Sl. 348.

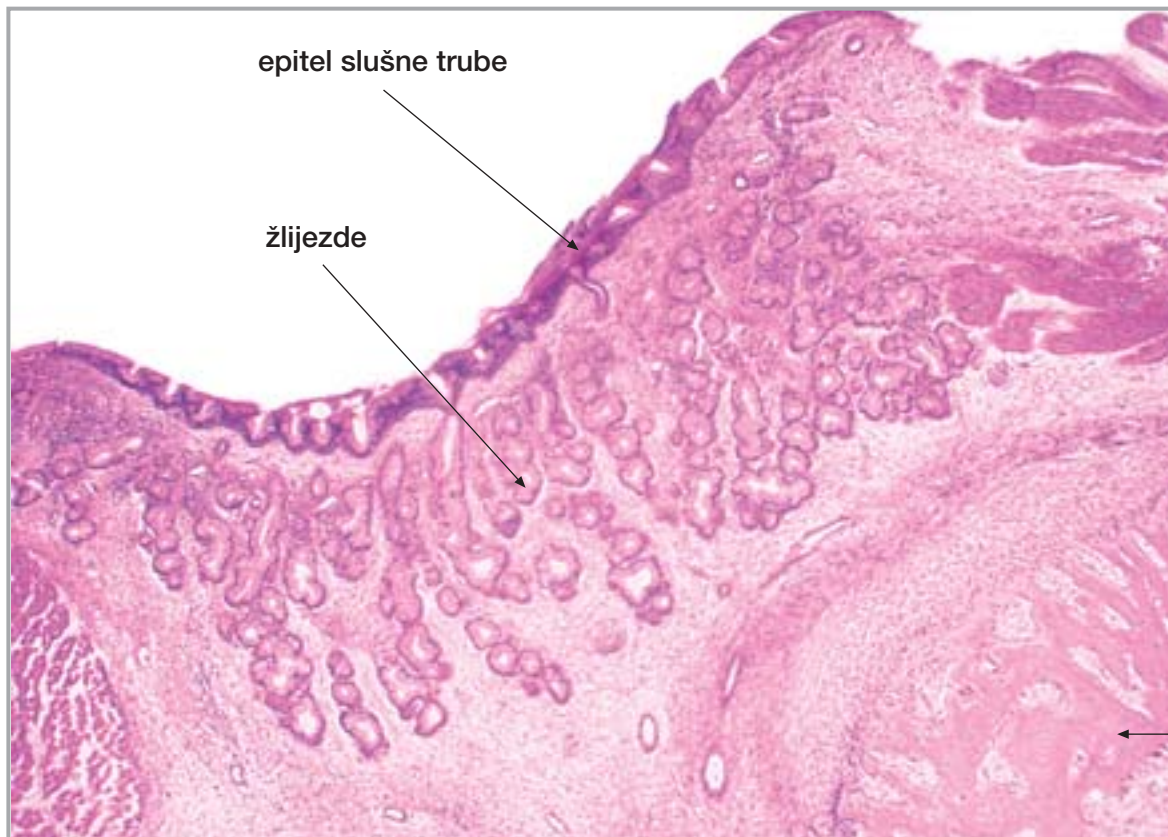
**Uho
(bubnjišna
membrana)**



Sl. 349.

**Uho
(slušna truba)**





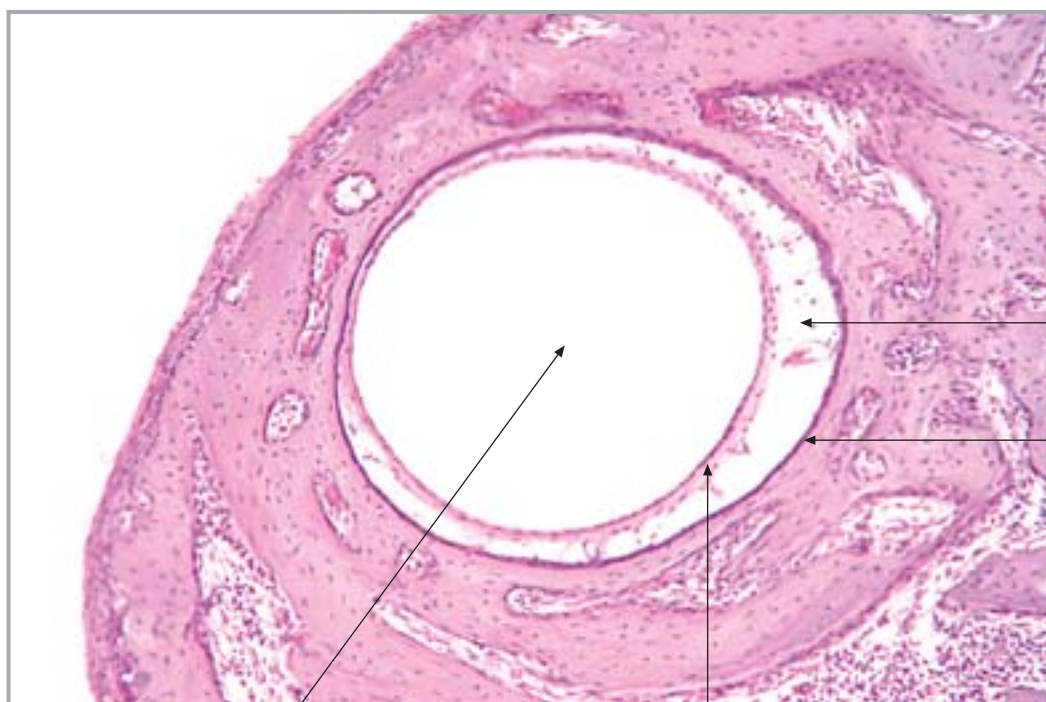
epitel slušne trube

žlijezde

Sl. 350.

Uho
(slušna truba)

koštana stijenka



Sl. 351.

Uho
(polukružni kanal)

perilimfatički prostor

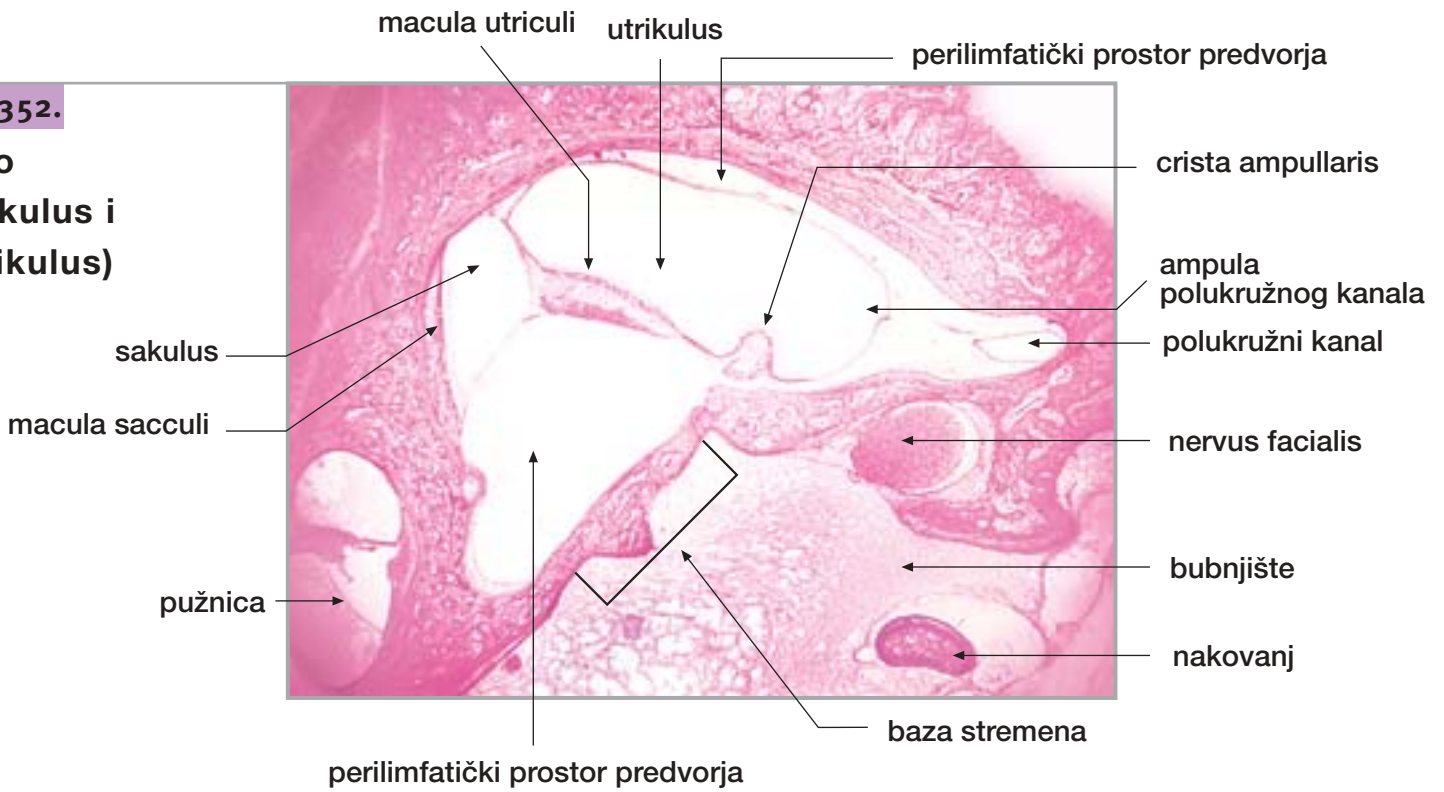
koštana stijenka

endolimfatički prostor

membranska stijenka

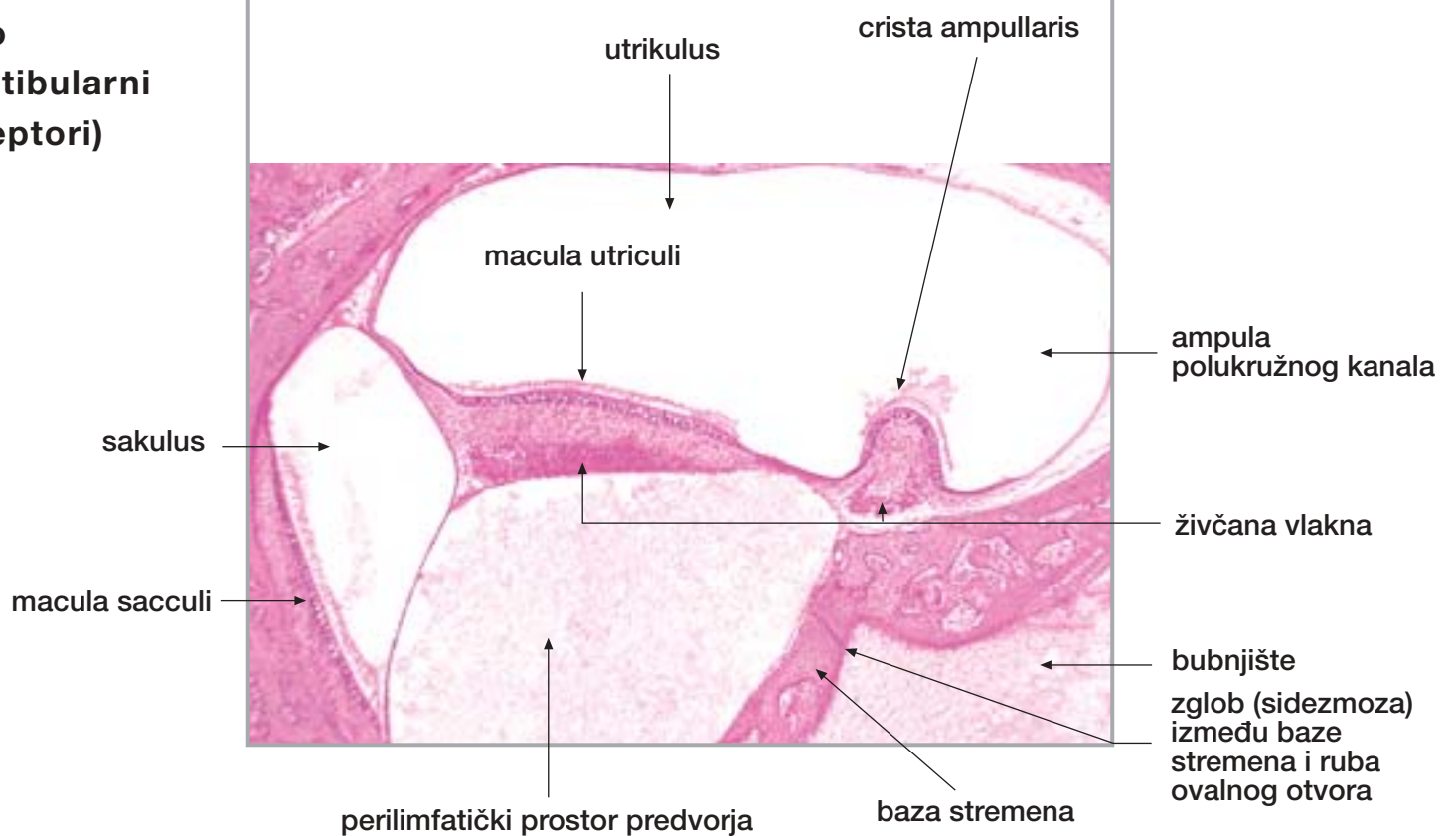
Sl. 352.

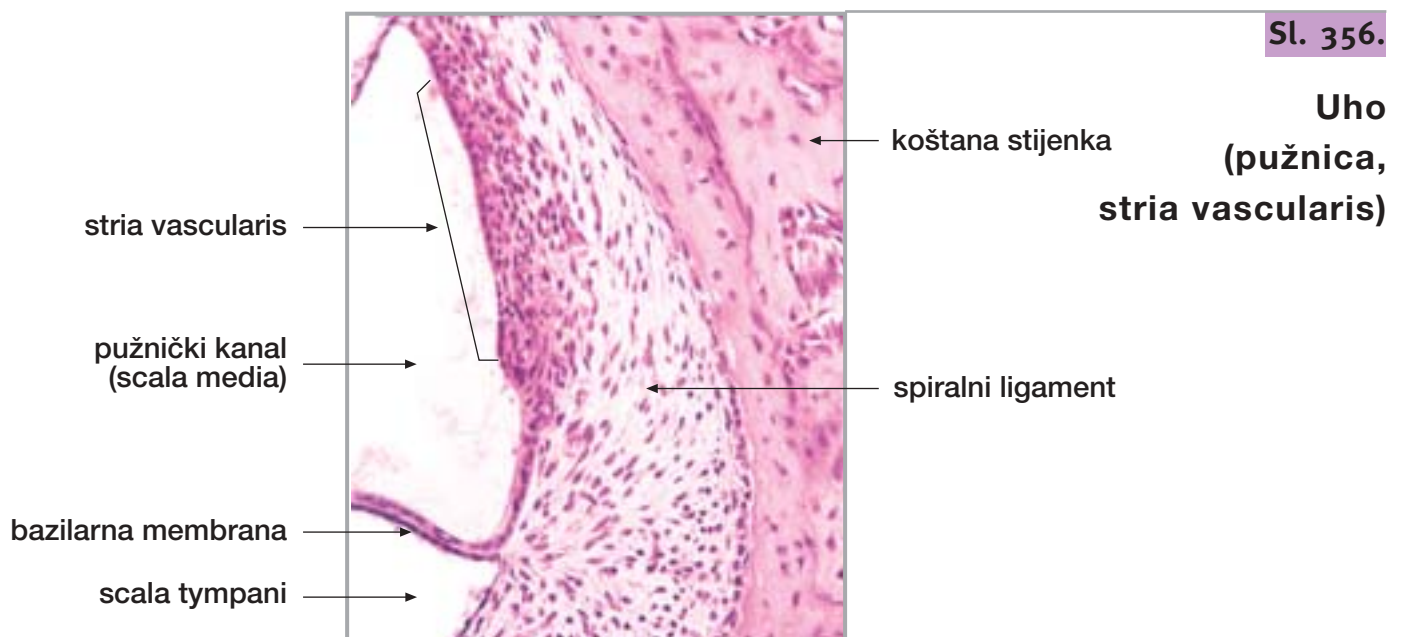
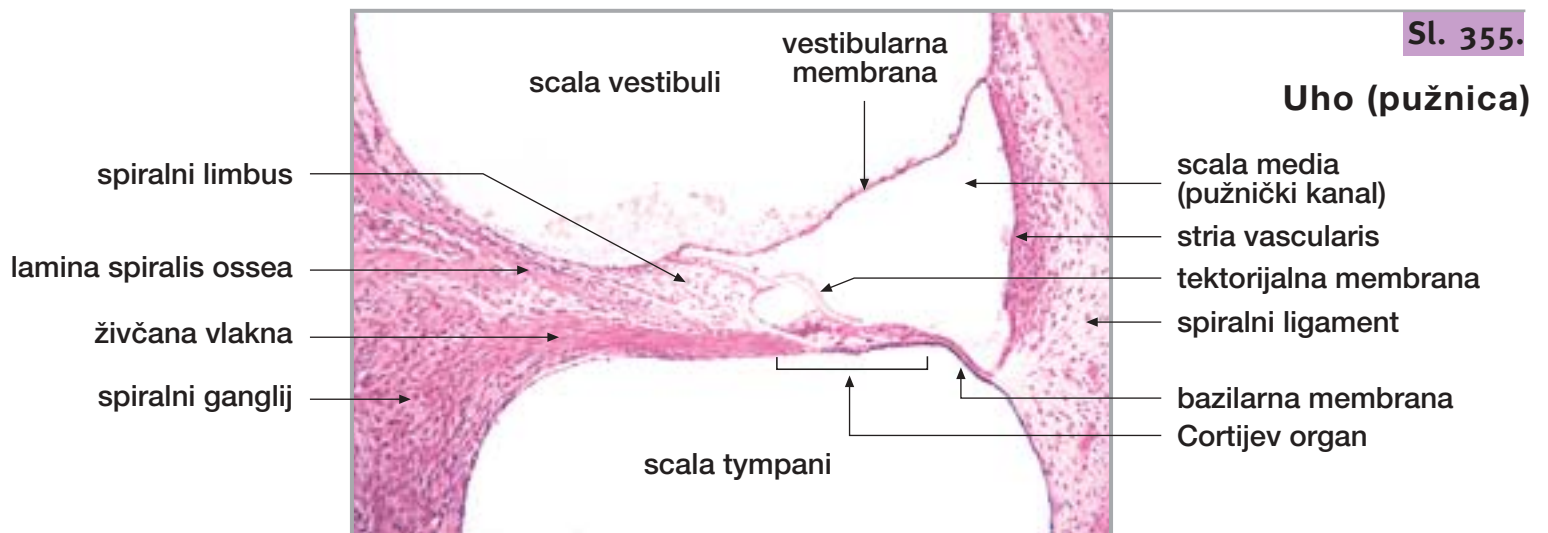
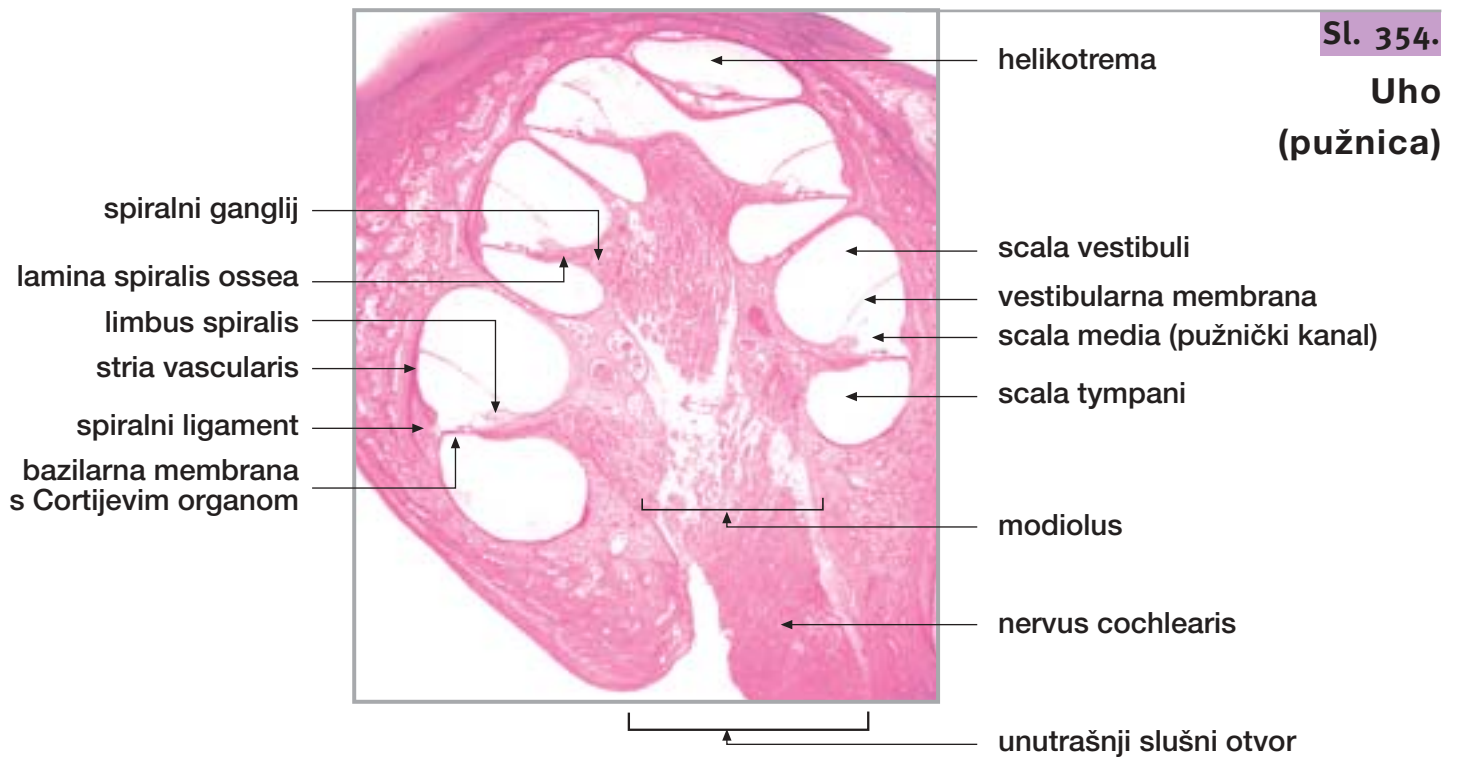
Uho
(sakulus i
utrikulus)



Sl. 353.

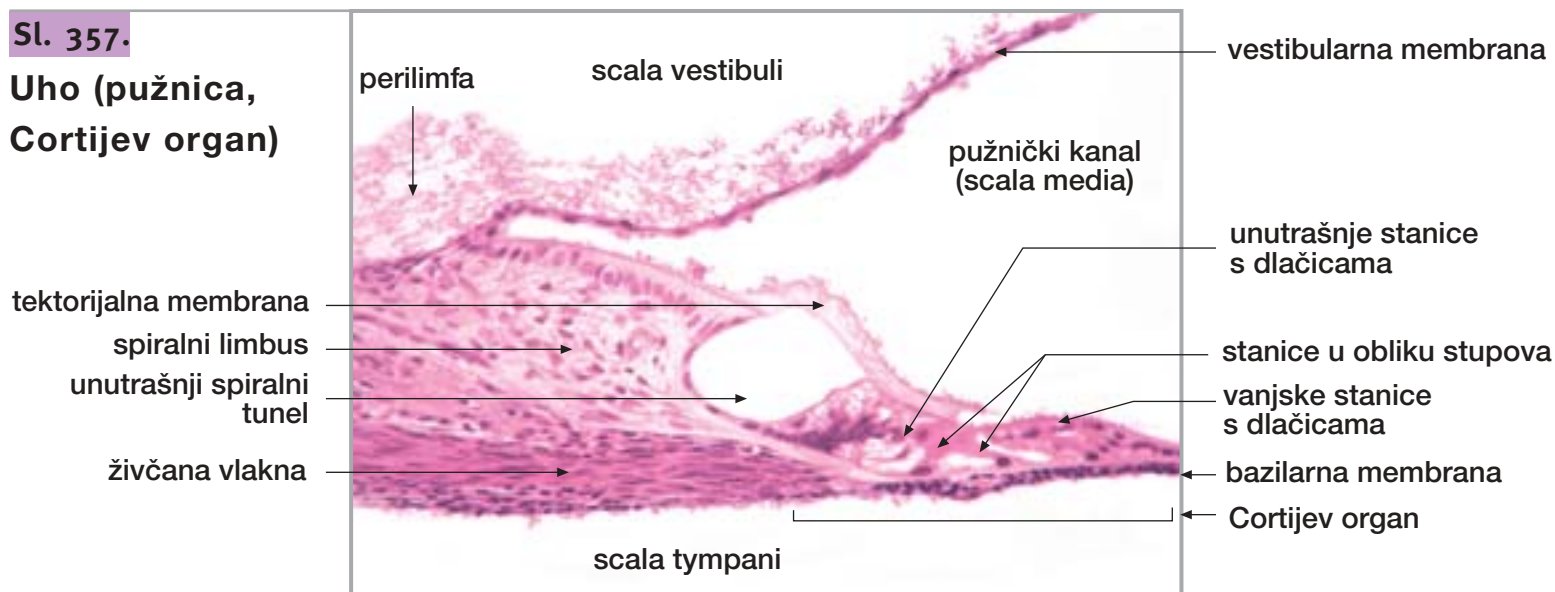
Uho
(vestibularni
receptori)





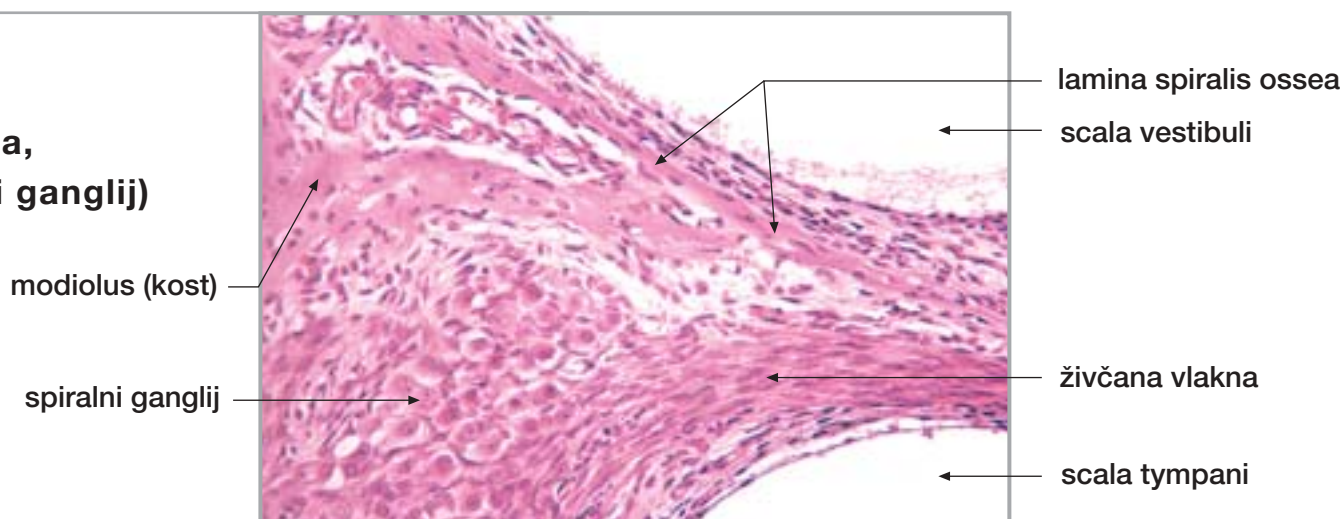
Sl. 357.

Uho (pužnica, Cortijev organ)



Sl. 358.

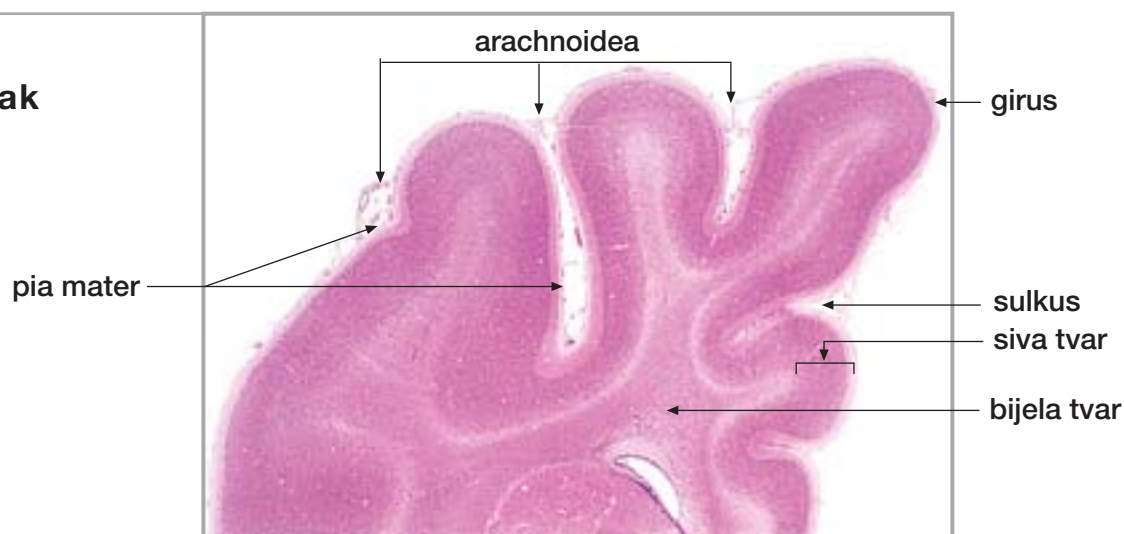
Uho (pužnica, spiralni ganglij)



35. VELIKI I MALI MOZAK, KRALJEŽNIČNA MOŽDINA

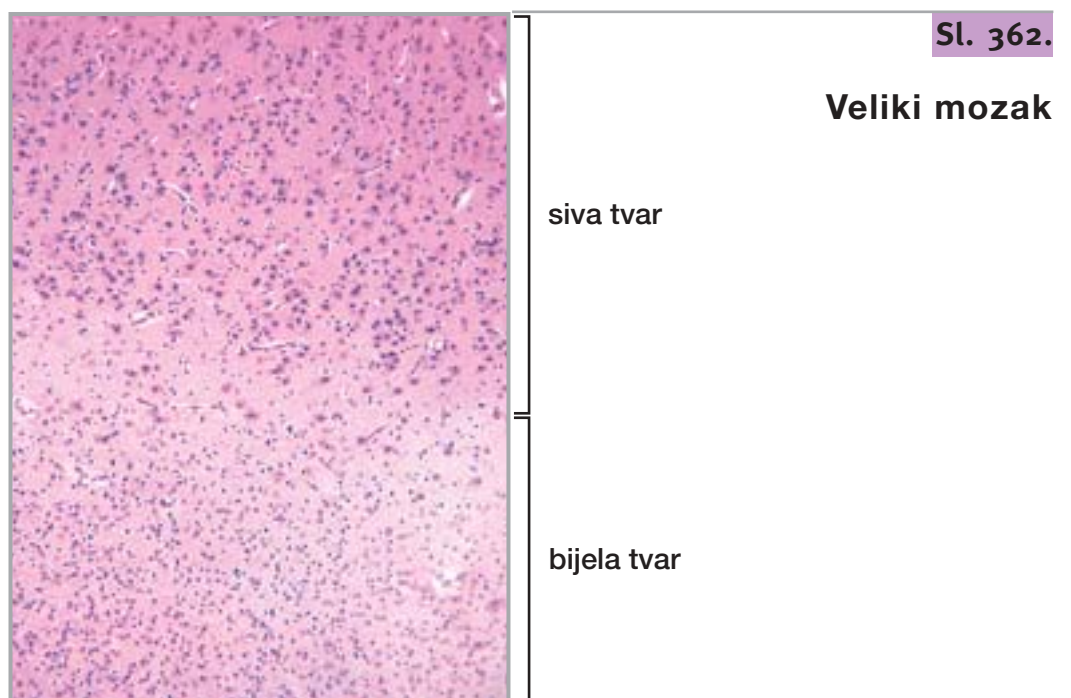
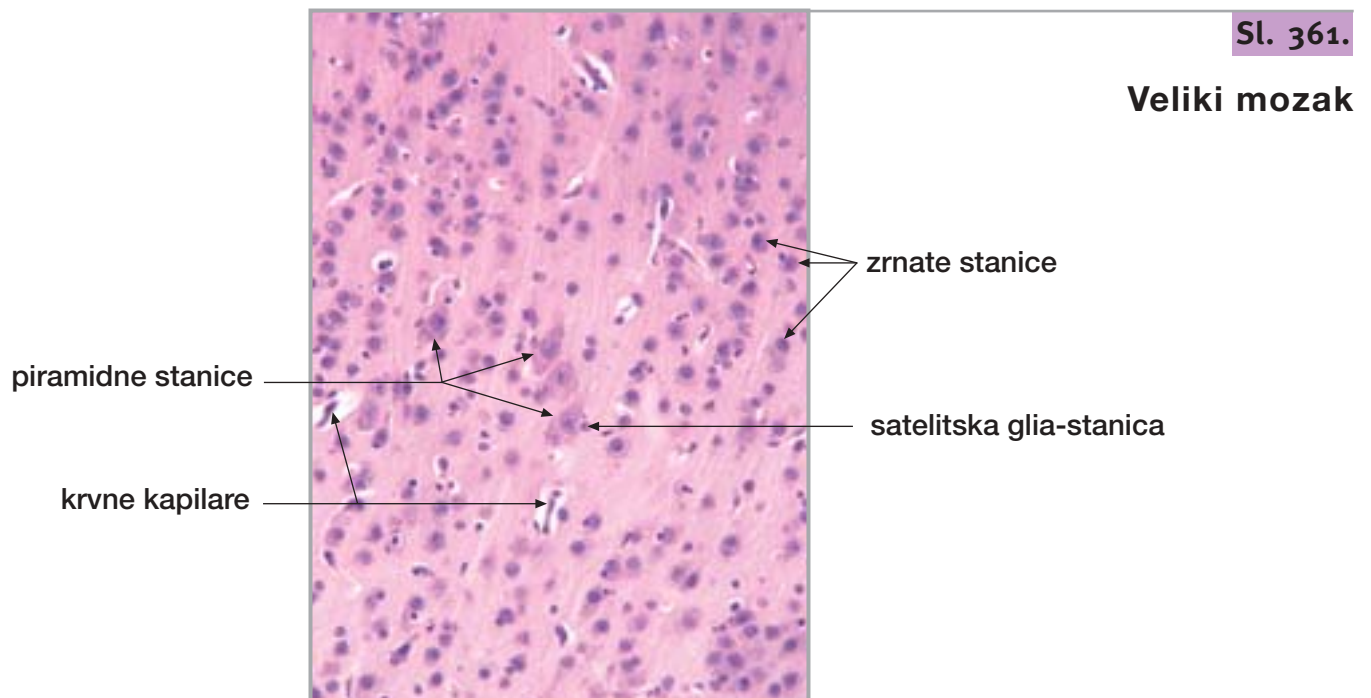
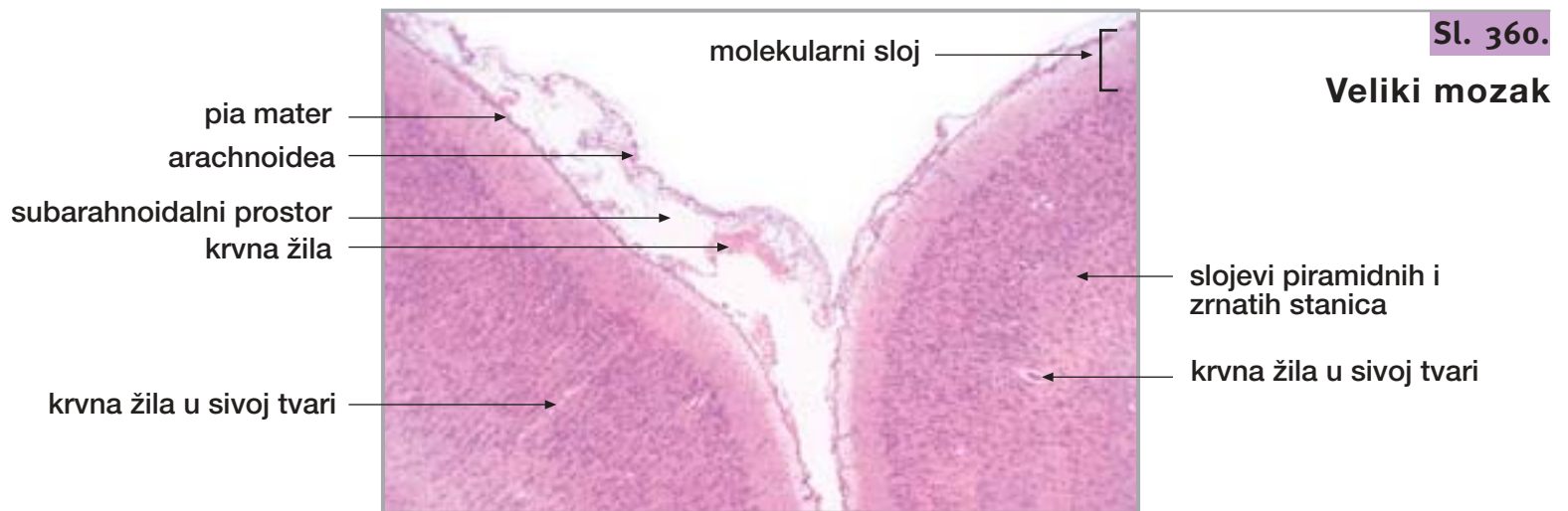
Sl. 359.

Veliki mozak



35. VELIKI I MALI MOZAK, KRALJEŽNIČNA MOŽDINA

NASTAVAK

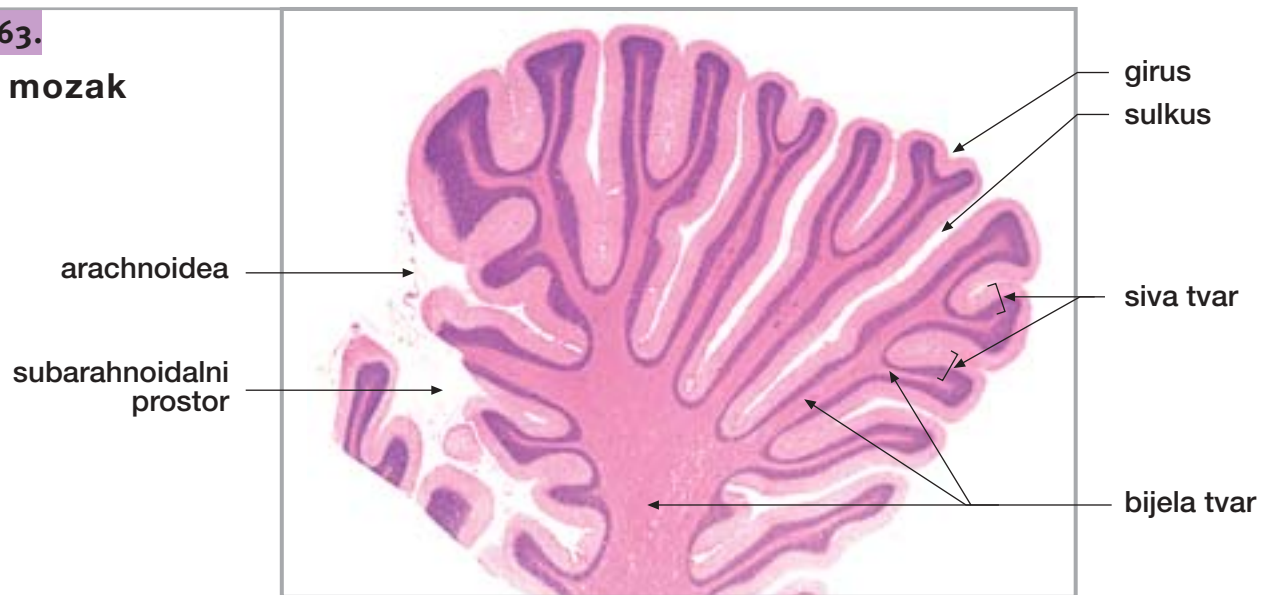


35. VELIKI I MALI MOZAK, KRALJEŽNIČNA MOŽDINA

NASTAVAK

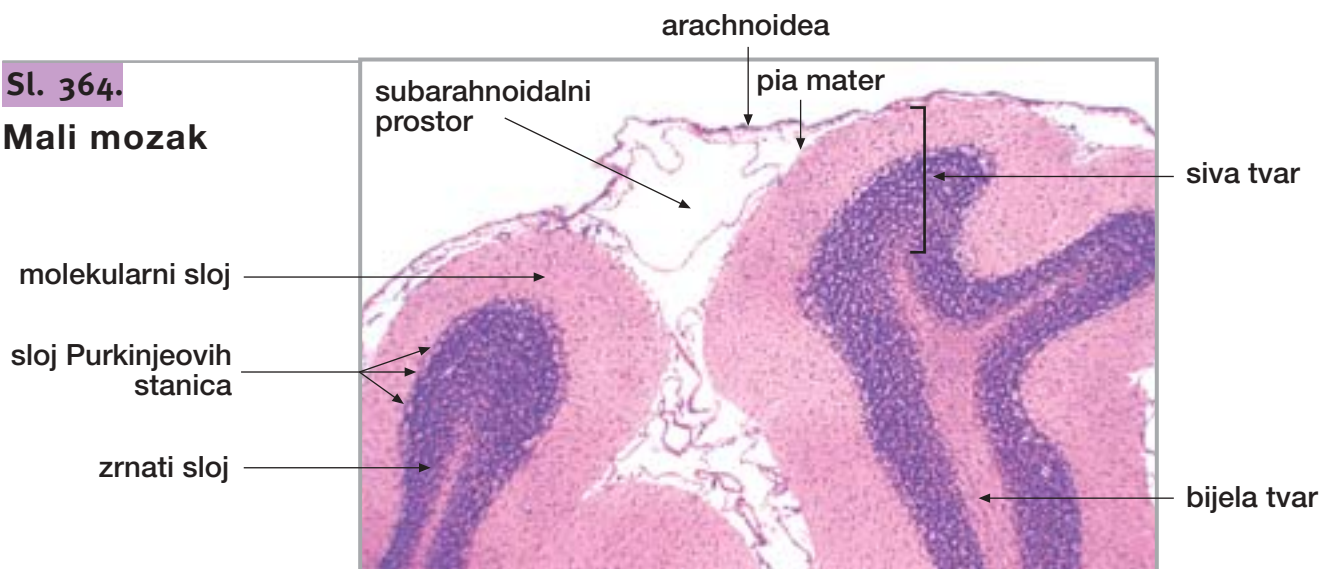
Sl. 363.

Mali mozak



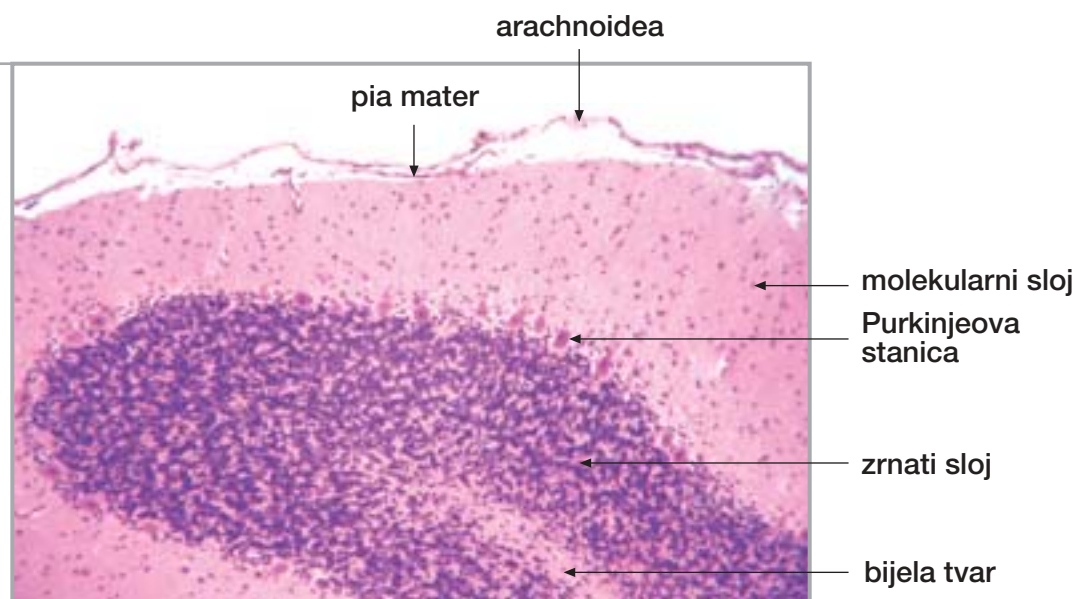
Sl. 364.

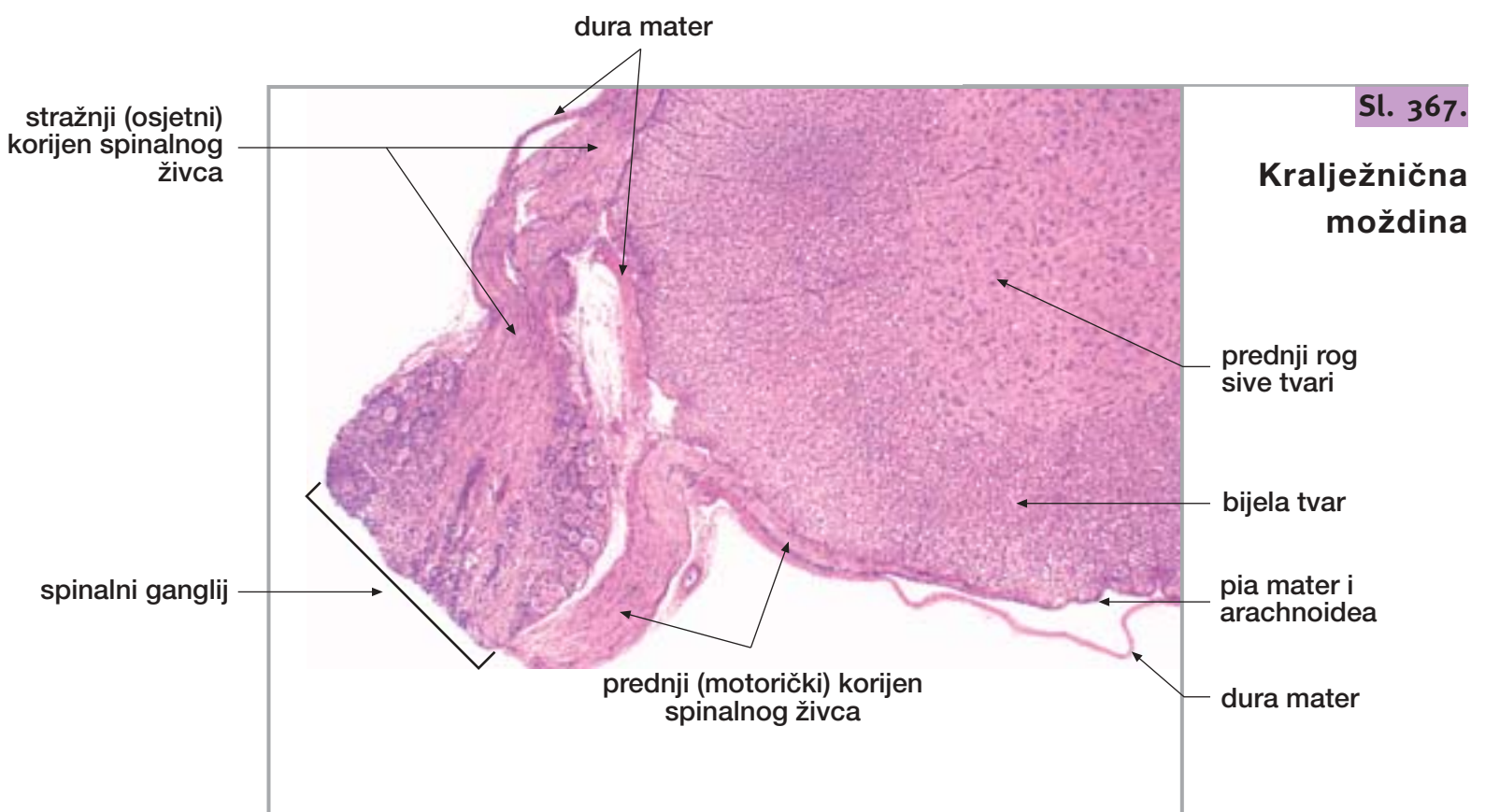
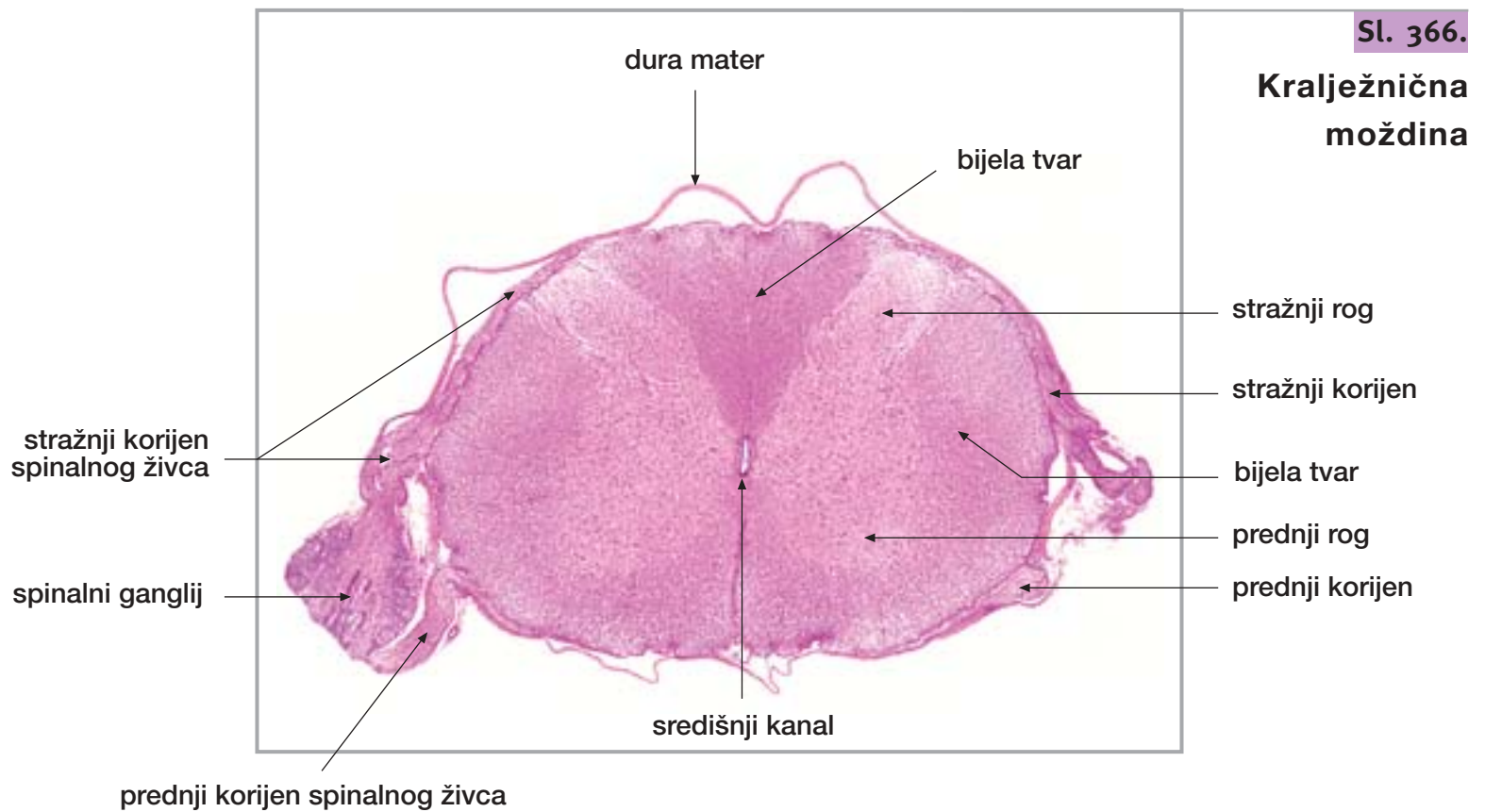
Mali mozak



Sl. 365.

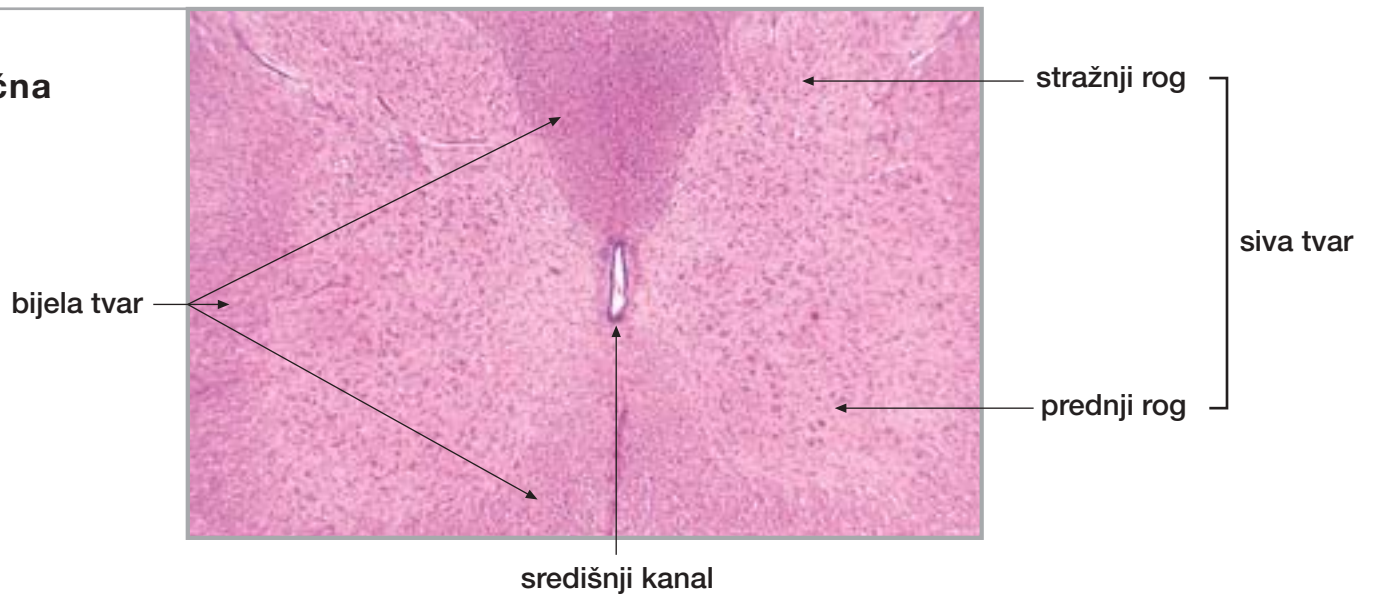
Mali mozak





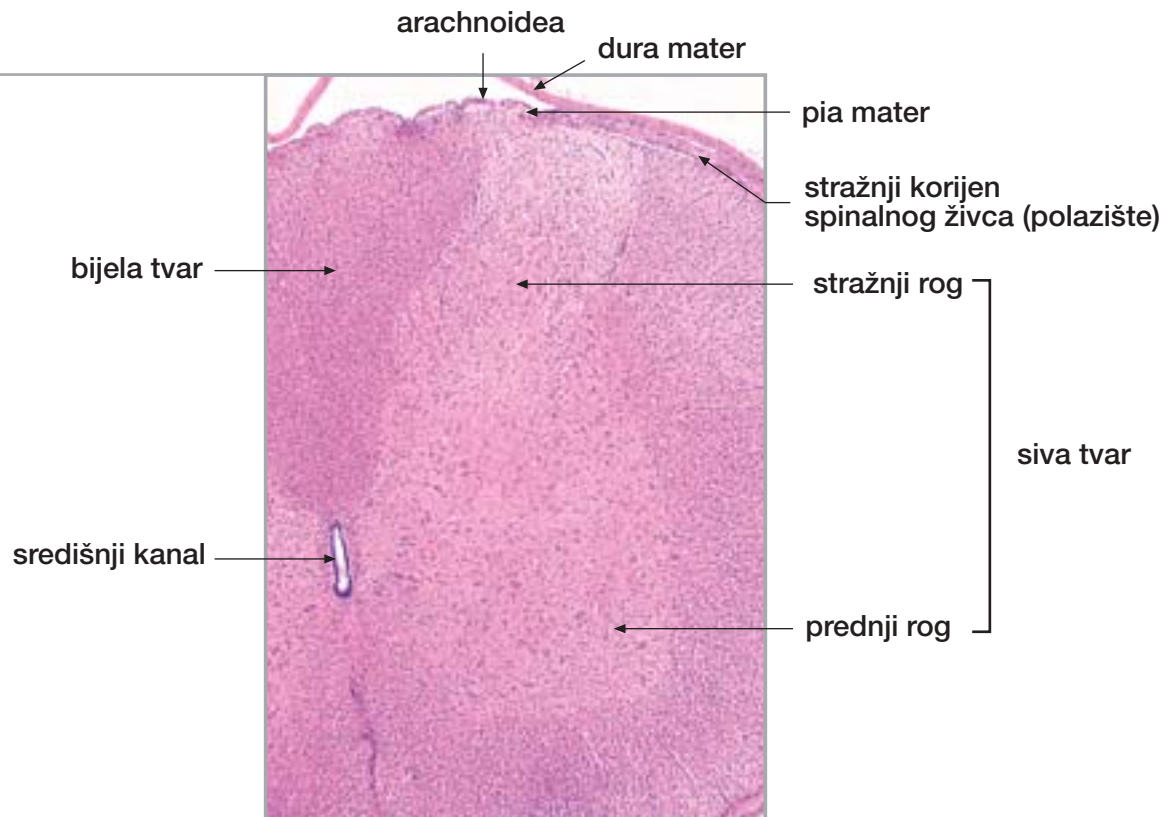
Sl. 368.

Kralježnična moždina



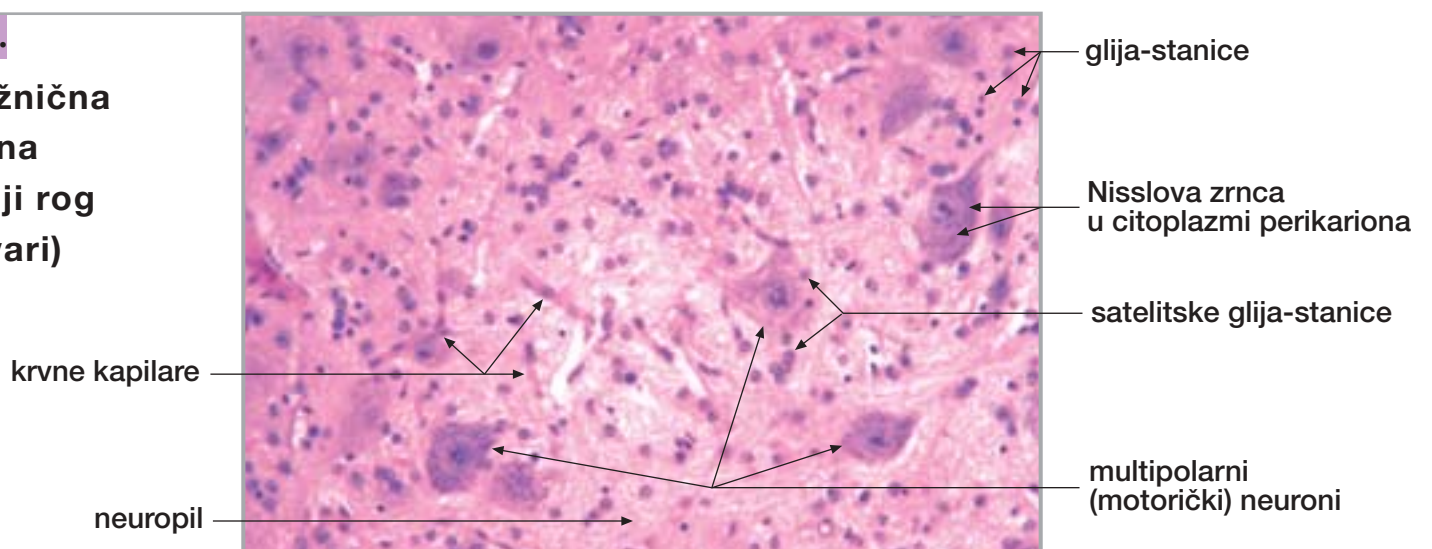
Sl. 369.

Kralježnična moždina



Sl. 370.

Kralježnična moždina (prednji rog sive tvari)



Izdavač: Kaligraf d.o.o., Zagreb, Rim 75
01 / 234 77 22, kaligraf@zg.tel.hr

Za izdavača: Miho Karolyi

Autori: Prof. dr. sc. Želimir Bradamante
Prof. dr. sc. Anton Švajger

Priprema za tisak: Kaligraf, Zagreb

Tisak: Kerschoffset, Zagreb

Naklada: 500

ISBN 953-6975-02-5

CIP - Katalogizacija u publikaciji
Nacionalna i sveučilišna knjižnica - Zagreb

UDK 611-018

BRADAMANTE, Želimir

Slike histoloških preparata : vježbe
iz histologije / Želimir Bradamante, Anton
Švajger. - Zagreb : Kaligraf , 2001-2002.

ISBN 953-6975-00-9

Dio 2. - 2002.

ISBN 953-6975-02-5

1. Švajger, Anton
I. Histologija - Priručnik

420408076

