

# Update on surgical treatment for sleep apnoea<sup>1</sup>

Joachim T. Maurer

Department of Otorhinolaryngology, Sleep Disorders Centre, University Medicine Mannheim, Medical Faculty Mannheim of the Ruprecht-Karls University Heidelberg, Germany

## Summary

Many patients with obstructive sleep apnoea (OSA), as well as the medical community, are seeking alternative therapies to continuous positive airway pressure (CPAP). Where there are problems with CPAP adherence, surgical procedures are an option without the need for adequate compliance. A wide variety of surgical procedures is available, all of which address the differing anatomy and types of patients requiring specific evaluation of the available data.

The author performed a literature search up to October 2008, the studies being evaluated according to EBM criteria. The data for some of the methods was limited. Minimally invasive surgery is helpful due to its positive efficacy vs morbidity

ratio. While UPPP is still the standard procedure in mild to moderate OSA, its success is difficult to predict and often falls off with the passage of years. Additional upper airway investigations have not yet succeeded in overcoming this disadvantage. Combined surgery of the multi-level is reserved for secondary treatment after CPAP failure. Only tonsillectomy and maxillomandibular advancement are successful enough to be considered a first-line treatment in certain patients.

*Key words: OSA; surgery; therapy*

## Introduction

Continuous positive airway pressure (CPAP) is the treatment of choice for patients with obstructive sleep apnoea syndrome (OSA) [1]. On the other hand, the last Cochrane review did not recommend surgery at all for OSA, except in studies [2]. However, adherence to CPAP is only between 17 and 54% [3], thus leaving a large group of patients without adequate treatment. Many patients therefore seek alternative treatments, such as oral appliances and surgery. Oral appliances also require sufficient compliance in order to be effective. As a result, many patients prefer surgical therapy.

Over the last 27 years various procedures for upper airway surgery have been developed involving the nose, palate, tongue, larynx, facial skeleton

and the neck, all trying to improve upper airway patency by either actively opening the airway, removing anatomical obstructions, stiffening the pharyngeal wall, increasing its muscle tone, a combination thereof or bypassing the collapsible segment. In addition, upper airway surgery can be divided into minimally and classical invasive surgery.

To improve the surgical outcome, clinical-endoscopic examination of the upper airway has been supplemented by more sophisticated techniques such as videoendoscopy during sedation and pharyngeal pressure measurements.

This publication presents current data on surgical therapies for sleep apnoea and discusses their impact on treatment flow.

<sup>1</sup> This publication was presented in part at the Annual Meeting of the Swiss Society for Sleep Research, Sleep Medicine and Chronobiology, Solothurn, February 2008.

## Nasal surgery

Nasal ventilation has only minimal impact on the severity of sleep disordered breathing in adults [4]. Accordingly, improvement of nasal breathing by any means whatever has failed to show a significant impact on adult OSA. This is also true of

nasal surgery [5]. Changes in severity of OSA do not exceed normal night-to-night variability; success rates do not exceed 10%.

However, nasal surgery is very often performed in OSA patients to improve adherence to

and compliance with nasal CPAP. Data on 71 patients now with CPAP titration before and after nasal surgery indicate that the requisite pressure can be reduced by approximately 2 mbar [6]. Bier-

mann showed that in long-term follow-up patients with nasal surgery used CPAP for two hours longer per night than those without nasal surgery [7].

### Minimally invasive surgery

There is no official definition of this term. We consider an operation to be minimally invasive if it fulfills certain criteria (table 1). The different types of radiofrequency surgery, Pillar® palatal implants and injection snoreplasty may be subsumed under this group. The latter has not been evaluated for OSA and therefore will not be described further.

#### Radiofrequency

The use of high frequency electric current in surgery is called radiofrequency (RF) surgery. Today monopolar as well as bipolar systems are in use. RF can be applied either interstitially, thus coagulating tissue, or superficially for vaporisation or cutting purposes. Interstitial coagulation is the technique commonly used in OSA patients at present. Coagulation produces necrosis and subsequent scarring, leading to tissue stiffening [8] and, in some tissue types (lymphatic tissue, turbinates), to volume reduction [9, 10] e.g. of 50–75% in the case of tonsil treatment. Energy delivery is controlled by measurement of temperature, impedance, or application time at a certain energy input, to avoid overdosing and tissue carbonisation. This leads to reproducible lesion sizes for specific power settings. The number of lesions per session and the number of treatment sessions per-

formed varies according to the technical system used, the site of surgery and the surgeon's experience.

In OSA, RF has so far been applied to the soft palate, the tongue base and the tonsils. Treatments were isolated or combined.

Interstitial treatment of the soft palate in simple snorers has proven superior to placebo in a controlled trial [11]. An even higher success rate seems to be possible when performing radiofrequency uvulopalatoplasty (RF-UPP) [12]. Data for OSA are scarce and conflicting, with success rates ranging from 17 to 66% [13, 14]. Verse presented a meta-analysis of three publications showing a mean AHI reduction from 20.2 to 12.8. The original data points towards a loss of efficacy in patients with an AHI above 30 [6]. Better results can be achieved if interstitial coagulation is combined with resection of excessive mucosa of the posterior pillar – the above-mentioned RF-UPP [15]. Due to the excision of mucosa, RF-UPP is more painful than purely interstitial treatment. In the long term RF-UPP seems to be superior to laser-assisted uvulopalatoplasty (LAUP) but to need more treatment sessions. It should be mentioned that no negative impact of interstitial RF treatment of the palate on speech or voice was demonstrable either subjectively or objectively [16, 17].

Radiofrequency is the only minimally invasive treatment of the tongue base available today. It has been used in mild to moderate OSA and is able to reduce AHI by approximately 33% on average (table 2). In polysomnographic outcome it is less effective than CPAP but superior to placebo [25]. Surprisingly, subjective outcome did not differ significantly. Results achieved initially remain stable over a two-year period [21].

Combined radiofrequency of soft palate and tongue base does not have higher morbidity but a slightly better outcome than tongue base treatment alone [6, 26]. As a result, combined treatment is preferred in most OSA cases.

In a recent meta-analysis of 13 case series and 3 controlled trials, Farrar et al. pooled combined as well as isolated soft palate and tongue base procedures. Short-term data (follow-up less than one year) showed a significant 31% decrease in AHI as well as daytime sleepiness (ESS). Long-term data (follow-up at least two years) from two studies involving 45 patients show an AHI reduction of 45% [27].

The impact of radiofrequency treatment of the palatine tonsils on OSA in adults has not been assessed except as part of multi-level surgery [28].

**Table 1**  
Criteria for minimally invasive surgery.

<b>perioperative</b>
procedure under local anaesthesia
low perioperative morbidity
<b>postoperative</b>
outpatient procedure
low complication rate
low postoperative morbidity

**Table 2**  
Efficacy of radiofrequency treatment of the tongue base in OSA.

Author	N	Follow-up	AHI pre	AHI post	ESS pre	ESS post	EBM
Powell et al. 1999 [18]	15	4.0	47.0	20.7	10.4	4.1	3b
Woodson et al. 2001 [19]	56	1.5	40.5	32.8	11.1	7.4	2b
Stuck et al. 2002 [20]	18	1.0	32.1	24.9	7.9	4.9	3b
Li et al. 2002 [21]	16	28.0	39.5	28.7	10.4	4.5	3b
Riley et al. 2003 [22]	19	3.0	35.1	15.1	12.4	7.3	3b
den Herder et al. 2006 [23]	10	12.0	12.9	10.6	5.1	4.4	3b
All	134	5.9	37.2	25.7			B

Follow-up in months; AHI = apnoea-hypopnoea index; ESS = Epworth sleepiness scale; pre = preoperative; post = postoperative; EBM = grading according to Oxford criteria [24].

**Table 3**

Efficacy of Pillar<sup>®</sup> palatal implants in patients with OSA. Follow-up in months; AHI = apnoea-hypopnoea index; ESS = Epworth sleepiness scale; EBM = grading according to Oxford criteria [24].

Author	N	Follow-up	AHI pre	AHI post	Success [%]	ESS pre	ESS post	EBM
Friedman et al. 2006 [30]	29	7.5	12.7	11.5	24.1	no data	no data	4
Walker et al. 2006 [31]	53	3.0	25.0	22.0	20.8	11.0	6.9	3b
Nordgard et al. 2006 [32]	25	3.0	16.2	12.1	36	9.7	5.5	3b
Nordgard et al. 2007 [33]	26	12.0	16.5	12.5	50	8.3	5.4	3b
Goessler et al. 2007 [34]	16	3.0	16.5	11.2	37.5	7.2	4.6	3b
Friedman et al. 2008 [35]	29	3.0	23.8	15.9	41.9	12.7	10.2	1b
Steward et al. 2008 [36]	47	3.0	16.8	13.9	26	10.6	8.7	1b
All	225	4.6	19.0	15.2	31.3			B

### Soft palate implants

Palatal implants (Pillar<sup>®</sup>) are cylinders of woven polyester yarns 18 mm in length and 2 mm in diameter. They are inserted into the soft palate at the junction with the hard palate and their aim is permanent stiffening of the soft palate. After initial case series showing efficacy in simple snorers [29], there are now case series and two randomised placebo-controlled trials in OSA pa-

tients (table 3). The overall efficacy is limited in these groups of patients with mild OSA. However, Pillar<sup>®</sup> implants were superior to placebo [35, 36]. Short-term results appear to remain stable over a one-year period [33, 37]. Furthermore, Friedman found objective success (by PSG) in 21.7% of patients receiving Pillar<sup>®</sup> as adjuvant therapy after uvulopalatopharyngoplasty (UPPP) had failed [38].

## Invasive surgery

### Pharyngeal procedures

Muscle-preserving UPPP is still the standard procedure at the level of the soft palate. Long-term data with a follow-up of 3–10 years are available showing a success rate of 49.5% [4]. The uvulopalatal flap yields similar success rates [4]. There is some evidence that tonsillectomy doubles the success rate of UPPP even though the success criteria are different (table 4). Li et al. showed that a favourable anatomy with large tonsils and a small tongue predicted outcome better than severity of OSA [44]. In addition, Verse stressed that success rates decrease significantly above a BMI of 30 [6]. Tonsillectomy itself plays an important role in OSA if the tonsils are nearly kissing during inspection with the mouth open and the tongue relaxed. Even though these patients are rare, they should not be missed because almost 80% can be cured [4]. In children with OSA there are data indicating that tonsillectomy is as effective as tonsillectomy and has significantly lower morbidity [45]. There are no current data concerning this procedure in adults.

LAUP cannot be recommended for OSA patients, since randomised controlled trials showed only a minimal decrease in AHI [46–48]. In con-

trast, pain after LAUP is severe and long-lasting [49], and is therefore not an alternative to minimally invasive techniques.

### Tongue base procedures

Data concerning tongue base resections via a transoral and transcervical approach are limited. During the 1990s they were aggressive, requiring perioperative tracheotomy in almost every case [4]. Since 2000 they have been superseded by radiofrequency. Nowadays less aggressive resections leaving the muscle tissue intact are being investigated by Coblation<sup>®</sup>. Morbidity can be significantly reduced and tracheotomy has never been necessary in our own small series of nine patients. Volume removal seems relevant. Data on outcome are still lacking.

The tongue suspension technique (Repose<sup>®</sup>) pulls the tongue base anteriorly using a non-resorbable thread fixed to the genioglossus tubercle. The procedure is performed under general anaesthesia. Success rates are around 33% [4]. Because it is difficult to obtain the correct tension on the suture, this procedure has been abandoned by most surgeons. Tongue advancement systems have therefore been developed where the necessary

**Table 4**

Impact of tonsillectomy on UPPP outcome (short-term results). AI = apnoea index; ODI = oxygen desaturation index; AHI = apnoea-hypopnoea index; TE = tonsillectomy

Author	n	Definition of success	without	with TE
Stevenson et al. 1990 [39]	84	AI reduction >50%	21/48	24/36
Schwartz et al. 1992 [40]	13	AI <10 in nonREM-Sleep	2/7	4/6
McGuirt et al. 1995 [41]	79	AI <5 and red. >50%	2/27	27/52
Boot et al. 2000 [42]	38	ODI reduction >50%	2/14	11/24
Hessel et al. 2004 [43]	55	AHI <20 and red. >0%	7/18	25/37
<b>Sum (Mean %)</b>	<b>269</b>		<b>34/114 (30%)</b>	<b>91/155 (59%)</b>

amount of advancement can be titrated under sedation later. They are under investigation and the results are awaited.

Hyoid suspension is a technique whereby the hyoid bone is fixed in front of the thyroid cartilage via a cervical approach. It is rarely carried out separately but chiefly used in multi-level surgery. Data on solitary procedures exist in 60 patients, showing a significant reduction in AHI and a success rate comparable to UPPP, bearing in mind that anatomically different patients were selected [6].

### Supraglottic procedures

Patients with supraglottic collapse are detectable by videoendoscopy under sedation only. The patterns found are comparable to laryngomalacia in children and surgical treatment is performed accordingly [50]. Improvement in 85% of the patients is described in only one case series in adults [51].

### Multi-level surgery

In most cases of moderate to severe OSA the entire upper airway is obstructed. Based on that concept multi-level surgery addresses the palate as well as the hypopharynx, combining procedures at both levels during one single operation if nasal ventilation is rejected or abandoned in spite of intensive care for the patient. UPPP or uvu-

lopalatal flap including tonsillectomy are the palatal procedures employed, whereas the hypopharyngeal obstruction is variably dealt with by performing genioglossus advancement, hyoid suspension, radiofrequency of the tongue base and/or tongue base resections. A meta-analysis of 1360 patients in 34 publications revealed a reduction in the mean AHI from 43.4 to 19.3, a success rate of 51.5% [6]. Typically these patients have no anatomical malformation. Patients should be aware that multi-level surgery is painful and may cause dysphagia lasting for four weeks [52].

### Maxillofacial surgery

Maxillomandibular advancement of approximately 1 cm after osteotomy of the upper and lower jaw constitutes a surgical option with a very high success rate for patients with retrognathia and OSA. Patients can be cured over a follow-up of four years with a 90% chance of success [53].

### Tracheostomy

Bypassing the pharyngeal obstruction by tracheostomy eliminates every obstructive respiratory event during sleep. Success rates are around 96% and remain stable over a period of at least three years [6]. Due to its invasive character it is reserved for severe and otherwise untreatable OSA and is rarely necessary.

---

## Extended upper airway evaluation

Videoendoscopy under sedation and pharyngeal multi-channel pressure measurements were developed during the 1990s to improve the analysis of upper airway obstruction. They are standardised and technically mature. Videoendoscopy under sedation mimics the true mechanism and

site of obstruction, with pressure catheters collecting data concerning the level of obstruction throughout the entire night. However, data documenting an improvement in surgical outcome is conflicting [54].

---

## Discussion

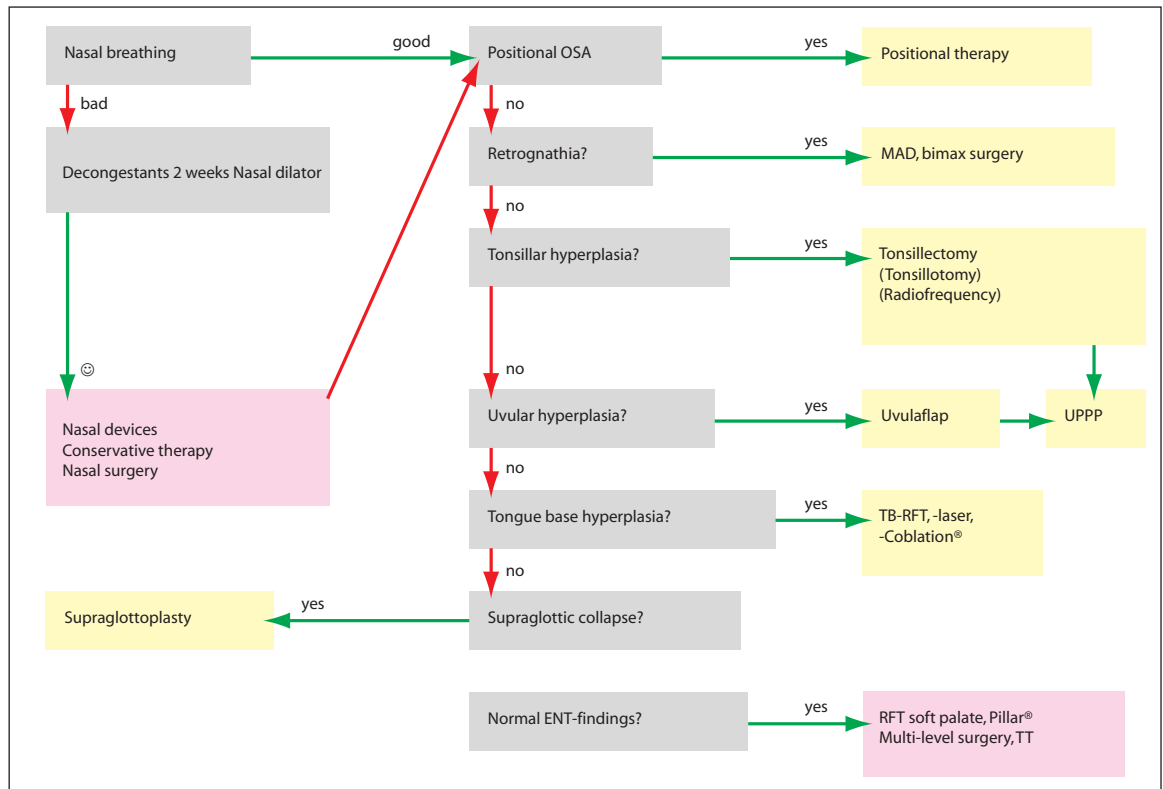
In the surgical community major efforts are in progress to improve the outcome of surgery. Several modifications of surgical interventions and techniques have been presented in recent years, addressing different anatomical sites and acting in completely different ways on upper airway patency. Patients' collapse mechanism may vary according to age, anatomy, body position, age, and body weight. As a result, different surgical procedures cannot be put together and evaluated as can the same treatment. In summary: different findings require different surgical treatment. These specific aspects were largely taken into account by Main and coworkers when evaluating each intervention on its own in their systematic review of surgical and non-surgical therapy for non-apnoeic snoring [55].

In contrast to CPAP, oral devices or drugs, placebo treatments are only possible in some minimally invasive surgical techniques. Comparisons with control groups always suffer from patient and bed partner bias due to peri- and postoperative morbidity. However, the highest possible evidence should be obtained in clinical studies regarding surgery for OSA. When assessing the efficacy of surgery for OSA each operation must be judged on its own merits and studies with the highest evidence available must be chosen for review. The Cochrane review [2] disregards all these factors and, therefore, suffers from a severe selection bias.

There is an increasing body of evidence to show that effective treatment of OSA by CPAP favourably influences cardiovascular risk factors

**Figure 1**

Flow diagram for therapy in OSA patients if CPAP is not accepted. MAD: mandibular advancement device; Bimax: maxillo-mandibular advancement; TB-RFT: tongue base radio-frequency treatment; TT: tracheotomy.



[56]. The available studies point to a higher impact on risk reduction in OSA patients suffering from excessive daytime sleepiness on the one hand and receiving effective treatment on the other. Hence, in particular, non-compliant and non-adherent CPAP patients respectively need to be carefully investigated with respect to their surgical treatment options. Furthermore, controlled outcome studies of surgery for OSA are necessary to assess its impact on cardiovascular risk reduction.

Finally, the following conclusions may be drawn from the published literature:

- Nasal ventilation therapy remains the gold standard in the treatment of OSA (Grade A).
- Nasal surgery is only indicated if nasal breathing is impaired (Grade B).
- Minimally-invasive procedures are helpful in mild OSA (Grade B).
- LAUP is not recommended in OSA (Grade B).
- Tonsillectomy is effective in adult OSA, if in-tertonsillar space is 5mm or less (Grade C).
- UPPP has a 50% long-term success rate in moderate OSA (Grade C).

- Solitary tongue base procedures are subject to research (Grade D).
- Multi-level surgery is reserved for moderate to severe OSA (Grade C).
- Maxillo-mandibular advancement is indicated in severe OSA with retrognathia (Grade B).
- Tracheotomy is rarely needed (Grade D).
- Tonsillectomy and maxillo-mandibular advancement are possible as first-line treatment for selected patients with moderate to severe OSA (Grade C).

If data concerning conservative options are also accounted for, a flow diagram for the treatment decision can be developed using simple patient characteristics (fig. 1).

#### Correspondence:

Dr. med. Joachim T. Maurer  
Department of Otorhinolaryngology  
Sleep Disorders Centre  
University Medicine Mannheim  
Medical Faculty Mannheim of the Ruprecht-Karls-University Heidelberg  
D-68135 Mannheim  
E-Mail: Joachim.maurer@umm.de

## References

- 1 Giles TL, Lasserson TJ, Smith BH, White J, Wright J, Cates CJ. Continuous positive airways pressure for obstructive sleep apnoea in adults. *Cochrane Database Syst Rev.* 2006;(3):CD001106.
- 2 Surgery for obstructive sleep apnoea. Sundaram S, Bridgman SA, Lim J, Lasserson TJ. *Cochrane Database Syst Rev.* 2005;(4):CD001004.
- 3 Weaver TE, Grunstein RR. Adherence to continuous positive airway pressure therapy: the challenge to effective treatment. *Proc Am Thorac Soc.* 2008;5:173–8.
- 4 Randerath W, Bauer M, Blau A, Fietze I, Galetke W, Hein H, et al. Stellenwert der Nicht-nCPAP-Verfahren in der Therapie des obstructiven Schlafapnoe-Syndroms. *Somnologie.* 2006;10:67–98.
- 5 Rombaux P, Liistro G, Hamoir M, Bertrand B, Aubert G, Verse T, Rodenstein D. Nasal obstruction and its impact on sleep-related breathing disorders. *Rhinology.* 2005;43:242–50.
- 6 Verse T. Update on surgery for obstructive sleep apnea syndrome. *HNO.* 2008;56:1098–104.



- 7 Biermann E. Nasal CPAP therapy in obstructive sleep apnea syndrome: Does functional rhinoplasty improve compliance? *Somnologie*. 2001;5:59-64.
- 8 Stuck BA, Köpke J, Maurer JT, Verse T, Eckert A, Bran G, Düber C, Hörmann K. Lesion formation in radiofrequency surgery of the tongue base. *Laryngoscope*. 2003;113:1572-6.
- 9 Seeger J, Zenev E, Gundlach P, Stein T, Müller G. Bipolar radiofrequency-induced thermotherapy of turbinate hypertrophy: pilot study and 20 months' follow-up. *Laryngoscope*. 2003;113:130-5.
- 10 Coticchia JM, Yun RD, Nelson L, Koempel J. Temperature-controlled radiofrequency treatment of tonsillar hypertrophy for reduction of upper airway obstruction in pediatric patients. *Arch Otolaryngol Head Neck Surg*. 2006;132:425-30.
- 11 Stuck BA, Sauter A, Hörmann K, Verse T, Maurer JT. Radiofrequency surgery of the soft palate in the treatment of snoring. A placebo-controlled trial. *Sleep*. 2005;28:847-50.
- 12 Baisch A, Maurer JT, Hörmann K, Stuck BA. Combined radiofrequency assisted uvulopalatoplasty in the treatment of snoring. *Eur Arch Otorhinolaryngol*. 2008 May 16. [Epub ahead of print]
- 13 Brown DJ, Kerr P, Kryger M. Radiofrequency tissue reduction of the palate in patients with moderate sleep-disordered breathing. *J Otolaryngol*. 2001;30:193-8.
- 14 Blumen MB, Dahan S, Fleury B, Hausser-Hauw C, Chabolle F. Radiofrequency ablation for the treatment of mild to moderate obstructive sleep apnea. *Laryngoscope*. 2002;112:2086-2092.
- 15 Bassiouny A, El Salamawy A, Abd El-Tawab M, Atef A. Bipolar radiofrequency treatment for snoring with mild to moderate sleep apnea: a comparative study between the radiofrequency assisted uvulopalatoplasty technique and the channeling technique. *Eur Arch Otorhinolaryngol*. 2007;264:659-67.
- 16 Haraldsson PO, Karling J, Lysdahl M, Svanborg E. Voice quality after radiofrequency volumetric tissue reduction of the soft palate in habitual snorers. *Laryngoscope*. 2002;112:1260-3.
- 17 Birkent H, Soken H, Akcam T, Karahatay S, Gerek M. The effect of radiofrequency volumetric tissue reduction of soft palate on voice. *Eur Arch Otorhinolaryngol*. 2008;265:195-8.
- 18 Powell NB, Riley RW, Guilleminault C. Radiofrequency tongue base reduction in sleep-disordered breathing: a pilot study. *Otolaryngol Head Neck Surg*. 1999;120:656-64.
- 19 Woodson BT, Nelson L, Mickelson S, Huntley T, Sher A. A multi-institutional study of radiofrequency volumetric tissue reduction for OSAS. *Otolaryngol Head Neck Surg*. 2001;125:303-11.
- 20 Stuck BA, Maurer JT, Verse T, Hörmann K. Tongue base reduction with temperature-controlled radiofrequency volumetric tissue reduction for treatment of obstructive sleep apnea syndrome. *Acta Otolaryngol*. 2002;122:531-6.
- 21 Li KK, Powell NB, Riley RW, Guilleminault C. Temperature-controlled radiofrequency tongue base reduction for sleep-disordered breathing: Long-term outcomes. *Otolaryngol Head Neck Surg*. 2002;127:230-4.
- 22 Riley RW, Powell NB, Li KK, Weaver EM, Guilleminault C. An adjunctive method of radiofrequency volumetric tissue reduction of the tongue for OSAS. *Otolaryngol Head Neck Surg*. 2003;129:37-42.
- 23 den Herder C, Kox D, van Tinteren H, de Vries N. Bipolar radiofrequency induced thermotherapy of the tongue base: Its complications, acceptance and effectiveness under local anesthesia. *Eur Arch Otorhinolaryngol*. 2006;263:1031-40.
- 24 Phillips B, Ball C, Sackett D, Badenoch D, Straus S, Haynes B, Dawes M. Levels of evidence and grades of recommendation. Oxford Centre for Evidence-Based Medicine, 2001. Available from: [www.cebm.net/index.aspx?o=1025](http://www.cebm.net/index.aspx?o=1025)
- 25 Woodson BT, Steward DL, Weaver EM, Javaheri S. A randomized trial of temperature-controlled radiofrequency, continuous positive airway pressure, and placebo for obstructive sleep apnea syndrome. *Otolaryngol Head Neck Surg*. 2003;128:848-61.
- 26 Stuck BA, Starzak K, Verse T, Hörmann K, Maurer JT. Complications of temperature controlled radiofrequency volumetric tissue reduction for sleep disordered breathing. *Acta Otolaryngol*. 2003;123:532-5.
- 27 Farrar J, Ryan J, Oliver E, Gillespie MB. Radiofrequency ablation for the treatment of obstructive sleep apnea: a meta-analysis. *Laryngoscope*. 2008;118:1878-83.
- 28 Fischer Y, Khan M, Mann WJ. Multilevel temperature-controlled radiofrequency therapy of soft palate, base of tongue, and tonsils in adults with obstructive sleep apnea. *Laryngoscope*. 2003;113:1786-91.
- 29 Maurer JT, Hein G, Verse T, Hörmann K, Stuck BA. Long-term results of palatal implants for primary snoring. *Otolaryngol Head Neck Surg*. 2005;133:573-8.
- 30 Friedman M, Vidyasagar R, Bliznikas D, Joseph NJ. Patient selection and efficacy of pillar implant technique for treatment of snoring and obstructive sleep apnea/hypopnea syndrome. *Otolaryngol Head Neck Surg*. 2006;134:187-96.
- 31 Walker RP, Levine HL, Hopp ML, Greene D, Pang K. Palatal implants: a new approach for the treatment of obstructive sleep apnea. *Otolaryngol Head Neck Surg*. 2006;135:549-54.
- 32 Nordgård S, Stene BK, Skjøstad KW. Soft palate implants for the treatment of mild to moderate obstructive sleep apnea. *Otolaryngol Head Neck Surg*. 2006;134:565-70.
- 33 Nordgård S, Hein G, Stene BK, Skjøstad KW, Maurer JT. One-year results: palatal implants for the treatment of obstructive sleep apnea. *Otolaryngol Head Neck Surg*. 2007;136:818-22.
- 34 Gossler UR, Hein G, Verse T, Stuck BA, Hörmann K, Maurer JT. Soft palate implants as a minimally invasive treatment for mild to moderate obstructive sleep apnea. *Acta Otolaryngol*. 2007;127:5273-1.
- 35 Friedman M, Schalch P, Lin HC, Kakodkar KA, Joseph NJ, Mazloom N. Palatal implants for the treatment of snoring and obstructive sleep apnea/hypopnea syndrome. *Otolaryngol Head Neck Surg*. 2008;138:209-16.
- 36 Steward DL, Huntley TC, Woodson BT, Surdulescu V. Palate implants for obstructive sleep apnea: multi-institution, randomized, placebo-controlled study. *Otolaryngol Head Neck Surg*. 2008;139:506-10.
- 37 Walker RP, Levine HL, Hopp ML, Greene D. Extended follow-up of palatal implants for OSA treatment. *Otolaryngol Head Neck Surg*. 2007;137:822-7.
- 38 Friedman M, Schalch P, Joseph NJ. Palatal stiffening after failed uvulopalatopharyngoplasty with the Pillar Implant System. *Laryngoscope*. 2006;116:1956-61.
- 39 Stevenson EW, Turner GT, Sutton FD, Doekel RC, Pegram V, Hernandez J. Prognostic significance of age and tonsillectomy in uvulopalatopharyngoplasty. *Laryngoscope*. 1990;100:820-3.
- 40 Schwartz AR, Schubert N, Rothman W, Godley F, Marsh B, Eisele D, Nadeau J, Permut L, Gleadhill I, Smith PL. Effect of uvulopalatopharyngoplasty on upper airway collapsibility in obstructive sleep apnea. *Am Rev Respir Dis*. 1992;145:527-32.
- 41 McGuire WF Jr, Johnson JT, Sanders MH. Previous tonsillectomy as prognostic indicator for success of uvulopalatopharyngoplasty. *Laryngoscope*. 1995;105:1253-5.
- 42 Boot H, van Wegen R, Poulblon RM, Bogaard JM, Schmitz PI, van der Meche FG. Long-term results of uvulopalatopharyngoplasty for obstructive sleep apnea syndrome. *Laryngoscope*. 2000;110:469-75.
- 43 Hessel NS, Vries N. Increase of the apnoea-hypopnoea index after uvulopalatopharyngoplasty: analysis of failure. *Clin Otolaryngol Allied Sci*. 2004;29:682-5.
- 44 Li HY, Wang PC, Lee LA, Chen NH, Fang TJ. Prediction of uvulopalatopharyngoplasty outcome: anatomy-based staging system versus severity-based staging system. *Sleep*. 2006;29:1537-41.
- 45 Hultcrantz E, Linder A, Markström A. Long-term effects of intracapsular partial tonsillectomy (tonsillotomy) compared with full tonsillectomy. *Int J Pediatr Otorhinolaryngol*. 2005;69:463-9.
- 46 Berger G, Stein G, Ophir D, Finkelstein Y. Is there a better way to do laser-assisted uvulopalatoplasty? *Arch Otolaryngol Head Neck Surg*. 2003;129:447-53.
- 47 Kern RC, Kutler DI, Reid KJ, Conley DB, Herzon GD, Zee P. Laser-assisted uvulopalatoplasty and tonsillectomy for the management of obstructive sleep apnea syndrome. *Laryngoscope*. 2003;113:1175-81.
- 48 Ferguson KA, Heighway H, Ruby RRF. A randomized trial of laser-assisted uvulopalatoplasty in the treatment of mild obstructive sleep apnea. *Am J Respir Crit Care Med*. 2003;167:15-9.
- 49 Troell RJ, Powell NB, Riley RW, Li KK, Guilleminault C. Comparison of postoperative pain between laser-assisted uvulopalatoplasty, uvulopalatopharyngoplasty, and radiofrequency volumetric tissue reduction of the palate. *Otolaryngol Head Neck Surg*. 2000;122:402-9.
- 50 Senders CW, Navarrete EG. Laser supraglottoplasty for laryngomalacia: are specific anatomical defects more influential than associated anomalies on outcome? *Int J Pediatr Otorhinolaryngol*. 2001;57:235-44.
- 51 Golz A, Goldenberg D, Westerman ST, Catalfumo FJ, Netzer A, Westerman LM, Joachims HZ. Laser partial epiglottidectomy as a treatment for obstructive sleep apnea and laryngomalacia. *Ann Otol Rhinol Laryngol*. 2000;109:1140-5.
- 52 Baisch A, Hein G, Gossler U, Stuck BA, Maurer JT, Hörmann K. Subjective outcome after multi-level surgery in sleep-disordered breathing. *HNO*. 2005;53:863-8.
- 53 Li KK, Powell NB, Riley RW, Troell RJ, Guilleminault C. Long-term results of maxillomandibular advancement surgery. *Sleep*. 2000;4:137-9.
- 54 Maurer JT, Stuck BA. Update on upper airway evaluation in obstructive sleep apnea. *HNO*. 2008;56:1089-97.
- 55 Main C, Liu Z, Welch K, Weiner G, Jones SQ, Stein K. Surgical procedures and non-surgical devices for the management of non-apnoeic snoring: a systematic review of clinical effects and associated treatment costs. *Health Technol Assess*. 2009;13(3):1-208.
- 56 Thurnheer R. Obstructive sleep apnoea and cardiovascular disease - time to act! *Swiss Med Wkly*. 2007;137:217-22.