

Vertigo: A Review of Common Peripheral and Central Vestibular Disorders

Timothy L. Thompson, MD, Ronald Amedee, MD

Department of Otolaryngology – Head and Neck Surgery, Ochsner Clinic Foundation, New Orleans, LA

INTRODUCTION

Dizziness, a common symptom that affects more than 90 million Americans, has been reported to be the most common complaint in patients 75 years of age or older.¹ Dizziness, however, is a common term used to describe multiple sensations (vertigo, presyncope, disequilibrium), each having numerous etiologies. It is often difficult for a physician to elucidate the quality of dizziness a patient is experiencing and decide how to proceed with medical management. The focus of this article is the peripheral and central vestibular system. We review the more common disorders specific to this system, describe how patients with these disorders present, and discuss management protocols.

THE VESTIBULAR SYSTEM

The vestibular system is broadly categorized into both peripheral and central components. The peripheral system is bilaterally composed of three semicircular canals (posterior, superior, lateral) and the otolith organs (sacculae and utricle). The semicircular canals detect rotational head movement while the utricle and sacculae respond to linear acceleration and gravity, respectively. These vestibular organs are in a state of symmetrically tonic activity, that when excited stimulate the central vestibular system. This information, along with proprioceptive and ocular input, is processed by the central vestibular pathways (e.g. vestibular nuclei) and maintains our sense of balance and position.

PERIPHERAL VESTIBULAR DISORDERS

Peripheral vestibular disorders are limited to cranial nerve VIII and all distal structures. Patients

with a peripheral disorder demonstrate nystagmus to the contralateral side which suppresses with visual fixation. Nystagmus improves with gaze towards the lesion and worsens with gaze opposite the lesion. Patients may also report a falling sensation. Vegetative symptoms are not uncommon, and one can expect nausea, vomiting, and possibly sweating and bradycardia. The rate of recovery typically decreases with age and severity, and with the use of vestibulo-suppressive medications.

MENIERE'S SYNDROME

The term *Meniere's syndrome* is often used synonymously with the terms *Meniere's disease* (MD) and *endolymphatic hydrops*, although they are different. Endolymphatic hydrops describes an increase in endolymphatic pressure resulting in inappropriate nerve excitation which gives rise to the symptom complex of vertigo, fluctuating hearing loss, and tinnitus. The exact mechanism by which this increase in pressure produces the symptoms of MD is greatly debated and beyond the scope of this paper. Numerous disease processes can result in endolymphatic hydrops; if there is a known etiology then it is termed Meniere's syndrome. MD is a term used for endolymphatic hydrops of unknown etiology.

The true incidence of MD is unclear due to difficulty in diagnosis. Caucasians are more often affected, and it is more prevalent in females than males. Typically, these patients complain of spontaneous episodic attacks of tinnitus, aural fullness, fluctuating hearing loss, and vertigo superimposed on a gradual decline in hearing. Symptoms are variable, however, and patients may have a predominance of either cochlear (tinnitus, hearing loss) or vestibular (vertigo) complaints. Attacks typically last minutes to hours; however, most commonly subside after 2 to 3 hours.

Diagnosis is established with a thorough history detailing the aforementioned complaints, possibly accompanied by nausea, vomiting, and diaphoresis. Audiologic and vestibular testing is unreliable, but may show caloric weakness on electronystagmography (ENG) and sensorineural hearing loss on audiography.

There is no cure for MD and the goal of treatment is symptomatic relief. Medical treatment is initiated prior to more invasive surgical intervention and

Address correspondence to:

Ronald Amedee, MD

Department of Otolaryngology – Head and Neck Surgery
Ochsner Clinic Foundation

1514 Jefferson Hwy.

New Orleans, LA 70121

Tel: (504) 842-3640

Fax: (504) 842-3979

Email: ramedee@ochsner.org

Key Words: vertigo, vestibular system

consists of salt restriction, diuretics, vasodilators, anti-emetics, and anti-nausea medications. Those who fail medical treatment may consider surgical therapy. Surgical treatments can be classified as either hearing-conservative or non-hearing-conservative procedures and are appropriately chosen based on the patient's audiometric results. For patients with serviceable hearing, endolymphatic sac decompression, vestibular neurectomy, and intratympanic aminoglycoside infusion are options. Labyrinthectomy is reserved for patients with no serviceable hearing.

BENIGN PAROXYSMAL POSITIONAL VERTIGO

Benign paroxysmal positional vertigo (BPPV) is considered the most common peripheral vestibular disorder, affecting 64 of every 100,000 Americans.² Women are more often affected and symptoms typically appear in the fourth and fifth decades of life. In 1980, Epley proposed that free-floating densities (canaliths) located in the semicircular canals deflect the cupula creating the sensation of vertigo.³ This is well documented in his Canalithiasis Theory. Although these canaliths are most commonly located in the posterior semicircular canal, the lateral and superior canal may also be involved.

Patients with BPPV complain of vertigo with change in head position, rolling over, or getting out of bed, and the vertigo is often side specific. Vertigo occurs suddenly and lasts for less than 1 minute. Attacks are separated by remissions; however, patients may complain of constant light-headedness between episodes. Classic BPPV involving the posterior semicircular canal is characterized by the following: geotropic nystagmus with the problem ear down, predominantly rotary nystagmus toward the undermost ear, latency of a few seconds, duration limited to less than 20 seconds, reversal of nystagmus when the patient returns to an upright position, and a decline in response with repetitive provocation.

Diagnosis is made primarily through history and also by eliciting typical physical findings during the Dix-Hallpike maneuver. The Dix-Hallpike maneuver entails guiding a patient through a series of movements known to elicit nystagmus in a patient with BPPV. Electro-oculography and 2D videonystagmography are of limited use secondary to the inability of these tests to record torsional eye movement.

Treatment is often supportive as a large percentage of patients will have spontaneous resolution of their symptoms. For those with persistent symptoms, the first line of treatment is canalith repositioning maneuvers. These maneuvers attempt to reposition the free-floating canalith particles from the semicircular canals to the utricle using gravity. These

maneuvers are reported to be 91% effective.⁴ Patients with symptoms refractory to repositioning maneuvers may be candidates for singular neurectomy or posterior semicircular canal occlusion.

VESTIBULAR NEURONITIS

Vestibular neuronitis is the second most common peripheral cause of vestibular vertigo. Infection of the vestibular nerve results in nerve degeneration and may present bilaterally. Infection is most often thought to be of viral origin, usually from the herpes virus family. It may also result from bacterial invasion (e.g. *Borrelia*). It is believed that the superior vestibular nerve is more commonly involved secondary to its course throughout a long and narrower bony canal, making it more susceptible to compressive edema. The reported incidence of an upper respiratory infection prior to the development of vestibular symptoms varies from 23% to 100%.⁵

Patients present with complaints of sudden vertigo, lasting up to several days, often with vegetative symptoms. As this process affects only the vestibular portion of the vestibulocochlear apparatus, there is an absence of cochlear symptoms. Vertiginous complaints gradually improve over days to weeks; however, imbalance may persist for months after resolution of acute disease. Recurrence is not uncommon and may occur several times per year. Physical examination is limited and should consist of audiometric evaluation and ENG. Patients may demonstrate nystagmus and caloric weakness on the affected side.

Treatment is primarily supportive with the use of anti-emetics and anti-nausea medications. Vestibular suppressants should be used judiciously in the first few days of an acute attack. Prolonged use of these medications can delay recovery by inhibiting central compensation. Furthermore, early ambulation is paramount in the central nervous system's ability to compensate and is therefore recommended as soon as tolerable. High-dose methylprednisone has been shown to hasten recovery; however, prospective, randomized, double-blinded studies have failed to demonstrate added benefit from the use of antivirals (i.e. valacyclovir).⁶

LABYRINTHITIS

Labyrinthitis is an inflammatory disorder of the membranous labyrinth, affecting both the vestibular and cochlear end organs. It may present unilaterally or bilaterally, and similar to vestibular neuronitis, it is often preceded by an upper respiratory infection. This disorder occurs when infectious microorganisms or inflammatory mediators invade the membranous labyrinth, damaging the vestibular and auditory end organs. Potential etiologies include viral pathogens,

bacterial invasion, bacterial toxins, and systemic disease.

Viral labyrinthitis usually occurs in adults in their fourth to seventh decades of life. Bacterial labyrinthitis may result from both otogenic and meningitic infection, progressing to involve the labyrinth. Labyrinthitis of otogenic origin can be observed in any age group and may result from cholesteatoma or otitis media. Meningitic labyrinthitis is more common in children less than 2 years of age, who are more susceptible to developing meningitis. Otogenic infections typically cause unilateral symptoms while meningitic infections cause bilateral symptoms.

Unlike vestibular neuronitis, patients with labyrinthitis present with complaints indicative of both vestibular and cochlear damage. Vertigo presents suddenly and is accompanied by hearing loss. ENG may reveal nystagmus, and audiometry will reveal a sensorineural hearing loss or mixed hearing loss if middle ear effusion is present. Depending on the source of infection, patients may also present with findings consistent with otitis media, mastoiditis, or meningitis.

Treatment is aimed primarily at eradication of the underlying infection and supportive care. Middle ear effusions and mastoiditis should be drained and treated with antibiotics. Meningitis should be treated with culture-directed antibiotics with central nervous system penetration and appropriate consultation. Anti-emetics and anti-nausea medications are helpful during the acute phase.

VESTIBULAR SCHWANNOMA

Vestibular schwannoma (VS) is the most common intracranial neoplasm producing vestibular symptoms, affecting one in every 100,000 people per year.⁷ These are usually slow-growing, benign tumors that originate from the Schwann cells lining the vestibular portion of cranial nerve VIII. Occasionally these tumors arise from the cochlear branch of the eighth nerve, but this is reported in less than 5% of cases.⁸ Patients may present with either unilateral or bilateral VS. Bilateral VS is associated with neurofibromatosis II, which is additionally characterized by glioma, meningioma, subcapsular ventricular opacities, and less frequently, peripheral neurofibromata and café au lait spots.

Patients may present with episodic or positional vertigo, disequilibrium, tinnitus, and usually asymmetric hearing loss. Early in the disease, when the tumor is small, patients complain of dizziness, hearing loss, and tinnitus, due to compression of the vestibulocochlear nerve. The slow growth often allows for central compensation, alleviating vertigo. With continued growth, the tumor can press against the facial or trigeminal nerve causing facial weakness and

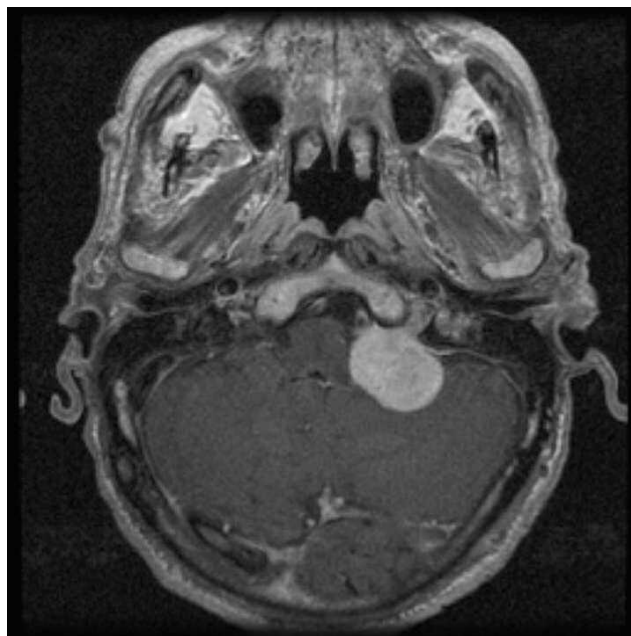


Figure 1. Magnetic resonance image of a patient with vestibular schwannoma.

numbness, respectively. Eventually, the tumor grows to a size where it compresses the brainstem and cerebellum causing truncal ataxia, dysmetria, disequilibrium, and possibly death.

Diagnosis begins with a thorough history and physical examination. An audiogram is important in documenting hearing loss and any asymmetries which may exist. If you suspect VS, then imaging is necessary. Computed tomography of the head with contrast is helpful, but magnetic resonance imaging (Figure 1) with and without enhancement is the preferred imaging modality.

Once VS is confirmed radiographically, a decision should be made on how to proceed with treatment. Treatment options include surgical excision, radiation therapy, and observation with serial magnetic resonance imaging. In making this decision, one should consider the size of the lesion, age and health of the patient, and what symptoms are present. These patients should be referred to a neuro-otologist for management of their care.

PERILYMPHATIC FISTULA

A perilymphatic or inner ear fistula results from an abnormal communication between the perilymphatic space and middle ear or an intramembranous communication. There are numerous causes, stapedectomy most commonly, and also head trauma, explosive blast, barotrauma, and physical exertion. Symptoms vary widely, with the prevalence and severity of both vestibular and cochlear symptoms differing greatly between individuals.

Diagnosis is made through a thorough history and physical examination. Patients may complain of disequilibrium after an increase in cerebrospinal fluid pressure (Hennebert's sign) or exposure to loud noises (Tullio's phenomenon). Physical examination may demonstrate a brief episode of nystagmus with positive pressure applied to the ear through pneumatic otoscopy (Fistula test) or an improvement in the audiogram after laying in Trendelenburg for 30 minutes (Fraser test).

Initially, treatment is conservative, with bed rest, head elevation, laxatives, and serial audiograms and physical examinations to assess hearing loss and vertigo. Surgical exploration is warranted in patients with persistent or worsening symptoms. Unfortunately, surgical exploration is successful in identifying a fistula only half of the time.⁹ When a fistula is observed, it should be patched by the surgeon with a material of their preference (blood clot, fascia, fat). Depending on the study, vestibular complaints were reduced 83% to 94% of the time and hearing loss 13% to 49%.⁹⁻¹¹

SUPERIOR SEMICIRCULAR CANAL DEHISCENCE SYNDROME

Superior semicircular canal dehiscence syndrome (SSCDS) results from a thin or dehiscent bone overlying the superior semicircular canal. Minor et al. theorized that this defect acts as a third window, in addition to the round and oval windows, allowing transfer of sound and pressure into the vestibular system.¹² This additional input is responsible for the clinical manifestations of the syndrome. Although the true incidence of this syndrome is unknown, one study showed that examination of cadaveric temporal bones revealed a dehiscent or markedly thin bone in 1.9% of specimens.¹³

This syndrome is characterized by vertigo induced by an increase in intracranial pressure or loud noise, chronic imbalance, tinnitus, and hyperacusis. Patients often refrain from noisy environments in an attempt to avoid vertiginous symptoms. Typically, patients do not demonstrate nystagmus on routine examination. They may, however, demonstrate Tullio and Hennebert signs and a positive fistula test, similarly to patients with a perilymph fistula. When the fistula test is performed, vertical-torsional nystagmus is evoked with slow waves directed away from the dehiscent labyrinth. This characteristic nystagmus may also be seen when patients are exposed to sound frequencies between 500 to 2000 Hz with intensity of 100 to 110 dB. In patients suspected of having SSCDS, high-resolution computed tomography (Figure 2) is required to make definitive diagnosis.

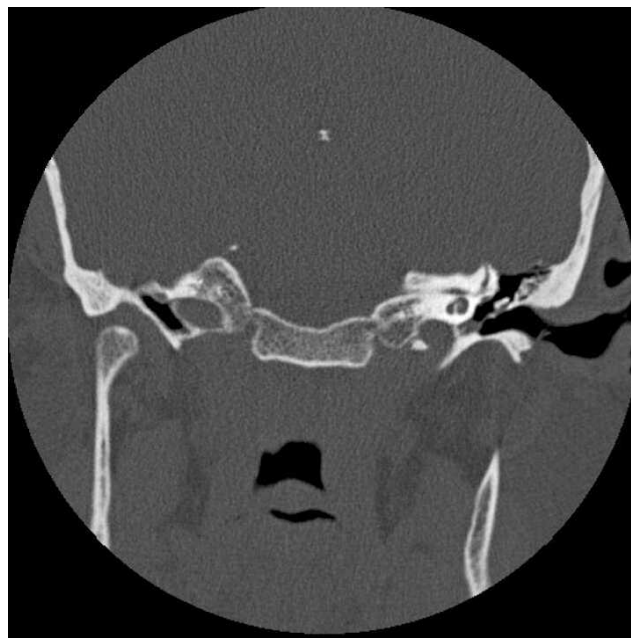


Figure 2. High-resolution computed tomography image of a patient with superior semicircular canal dehiscence syndrome.

Unlike many other disorders responsible for vertigo, surgery is the first line of treatment. Although there are numerous approaches, all have in common the goal of ablating the superior semicircular canal or patching the dehiscent bone with some form of material. Common to these procedures are the complications of sensorineural hearing loss, facial nerve injury, and persistent vertigo.

TRAUMA

Vertigo or ataxia is a common complaint among trauma patients. Vestibular complaints can arise from head trauma, cervical trauma, and damage to the peripheral vestibular system. The more common peripheral vestibular injuries and their medical management are detailed below.

Labyrinthine concussion may follow blunt head trauma or barotrauma and is characterized by a lack of otic capsule and intralabyrinthine membrane violation. Patients will have transient vertigo or disequilibrium and hearing loss most apparent at 4000 Hz. Complaints usually resolve in days to weeks but may persist for much longer.

Blast trauma, as seen with an open hand slap to the ear or explosion, infrequently results in vestibular damage. Patients are more likely to experience high frequency hearing loss with spontaneous recovery.

Penetrating trauma can be potentially devastating to the peripheral vestibular organs. The extent of damage to the vestibulocochlear system is dependent upon the mechanism of injury and the path of

penetration. In an otherwise healthy individual, vestibular complaints usually subside in days to weeks in unilateral injuries. Hearing loss varies and may be permanent. Treatment also varies greatly and may be as limited as bed rest and extensive as surgical repair, depending on the degree of injury.

Barotrauma is subclassified into two groups, alternobaric trauma and atmospheric inner ear barotrauma. Alternobaric trauma occurs most frequently in divers and pilots as they ascend. Symptoms occur as a result of increased middle ear pressure in relation to the ambient pressure. This increased pressure stimulates the vestibular and cochlear system leading to transient vertigo and hearing loss. These complaints often resolve within 15 minutes. Conditions which alter the patency of the eustachian tube, such as an upper respiratory illness, exacerbate this phenomenon. Patients involved in predisposing activities should be educated in the use of frequent equilibrations, the use of topical decongestants, and avoidance of such activities while afflicted with an upper respiratory illness.

Atmospheric inner ear barotrauma results from extreme pressure changes which damage the middle and inner ear structures. This most commonly occurs in divers, but has been reported in less likely situations such as forcefully sneezing with a closed mouth and nose. Unlike alternobaric trauma, injury can be long lasting and even permanent. Patients complain of hearing loss, tinnitus, and vertigo in varying degrees. Symptoms typically resolve with conservative management (bed rest and head elevation); however, those with progressive hearing loss or vertigo for greater than 3 to 5 days warrant surgical exploration. It has been suggested that patients should refrain from diving for at least 3 months.

CENTRAL VESTIBULAR DISORDERS

Not all vertigo results from a peripheral vestibulopathy and may actually be secondary to central pathology. Patients with central pathology more often present with complaints of disequilibrium and ataxia rather than true vertigo, but this is not always the case. Often their inability to stand or walk distinguishes them from patients with a peripheral lesion, who more commonly are able to stand or ambulate with assistance. Unlike peripheral lesions, nystagmus of central pathology changes direction with gaze, is unaffected by fixation, and may be purely vertical or torsional. Depending on the site of lesion there may be associated hearing loss as well as multiple other neurological symptoms. A thorough neurological examination is essential and should include such tests as the "foam and dome," heel to shin, and finger to nose.

MIGRAINE-ASSOCIATED DIZZINESS (VESTIBULAR MIGRAINE)

Migraines are considered a vascular syndrome resulting from serial constriction and dilation of intracranial vessels. Patients describe episodic attacks of severe headache and associated symptoms such as nausea, photophobia, phonophobia, and sensitivity to head movement. Approximately 10% of Americans are afflicted with this disorder, women more commonly than men. Patients suffering from migraine are usually between 30 to 50 years of age; however, any age group can be affected. Migraines are classically defined as migraines with or without aura.¹⁴ Auras are reversible neurological symptoms which develop over 15 minutes or less and typically resolve within an hour as the headache begins. Most commonly auras are characterized by visual disturbances such as scotomata, specks, scintillating scotoma, and hemianopia, but may consist of alterations in somatosensory, olfactory and auditory hallucinations, weakness, speech difficulty, and dizziness. Multiple triggers for migraines have been identified which include stress, diet (red wine, fruits, nitrates, chocolate, artificial sweeteners), fluorescent lights, allergies, and hormonal changes.

It has been reported that 38% of patients with migraines have episodic vertigo.¹⁵ Migraine-associated vestibular symptoms vary greatly among patients in regard to duration, severity, character, and temporal relation to headaches. Vestibular symptoms most commonly present as an aura and last seconds to hours. They may occur concurrently with the headache, after the headache, or between attacks with no appreciable temporal relation. Some patients may only have a distant history of headaches or only a family history of migraines. As mentioned earlier, migraines can present at any age, and many believe they are responsible for benign paroxysmal vertigo of childhood. This disorder usually occurs between the ages of 2 and 4 years and is described as brief (5 minutes) episodes of vertigo associated with anxiety, fear, nausea, and diaphoresis. Symptoms rapidly resolve with no residual neurologic signs. Symptoms disappear by 5 to 10 years of age. Migraine-associated dizziness (MAD) may present with new onset motion intolerance. Auditory hallucinations have been reported, but more commonly patients complain of low frequency sensorineural hearing loss. Hearing loss may fluctuate, complicating the distinction between vestibular migraine and MD.

Diagnosis is complicated by the lack of internationally accepted criteria for MAD. Neuhauser et al suggested the following criteria: the patient experiences recurrent episodic vertigo and a current or prior history of migraine, and at least one migraine

symptom must be present during two or more episodes of vertigo.^{15,16} Perhaps the most problematic dilemma is in differentiating MAD from MD. Both may present with episodic vertigo and possibly hearing loss. A thorough history is imperative and should inquire about headaches, photophobia, phonophobia, presence of aura, and any other neurological symptoms that may point towards a diagnosis of migraine. ENG and rotational testing is non-specific and often adds little if anything towards a diagnosis.

Once the diagnosis of MAD has been reached, numerous therapies are available for treatment. Initial management should focus on avoidance of triggers through lifestyle modification. Patients should avoid food and drinks as well as other agents known to induce migraines. Stress relief is recommended and both sleep and exercise are encouraged. For those who fail to find relief with lifestyle modification alone, medical treatment may be necessary. Prophylactic treatment varies depending on the physician, but most often includes one or more of the following; amytryptiline, benzodiazepines, beta-blockers, calcium channel blockers, and selective serotonin reuptake inhibitors. Acute attacks may require antiemetics and anti-vertiginous medications, as well as triptans. Those with headaches may also benefit from non-steroidal anti-inflammatory drugs.

VERTEBROBASILAR ISCHEMIC STROKE

The blood supply to the brainstem, cerebellum, and inner ear is derived from the vertebrobasilar system. Occlusion of any of the major branches of this system may result in vertigo. Symptoms of vertebrobasilar ischemic stroke (VIS) are highly variable and depend on which of the three major circumferential branches are occluded; the posterior inferior cerebellar artery, anterior inferior cerebellar artery, or superior cerebellar artery. Numerous processes may occlude the vertebrobasilar system. The most common are atherosclerosis, emboli, and vertebral artery dissection. Vertebral artery dissection can result from trauma or neck manipulation, or can occur spontaneously. Less common causes include subclavian steal syndrome, hypercoagulation disorders, and inflammatory conditions.

As mentioned earlier, the symptoms associated with ischemic stroke in this area are highly variable and greatly dependent upon which branch of the system is occluded. Occlusion of the posterior inferior cerebellar artery will cause a lateral medullary infarction and result in lateral medullary syndrome, also known as Wallenberg's syndrome. Expected manifestations include vertigo, nystagmus, gait disturbance, ipsilateral limb ataxia and facial pain or numbness, contralateral body hemianesthesia, Hor-

ner's syndrome, dysphagia, hoarseness, and rarely, facial nerve paralysis.

Lateral pontomedullary infarction secondary to occlusion of the anterior inferior cerebellar artery will result in lateral inferior pontine syndrome. This syndrome is characterized by symptoms similar to Wallenberg's syndrome with notable differences. Involvement of cranial nerves VII and VIII results in ipsilateral facial paralysis and tinnitus and hearing loss, respectively. Dysphagia and hoarseness, however, are not apparent as cranial nerves IX and X nuclei are uninvolved with occlusion of the anterior inferior cerebellar artery.

Lateral superior pontine syndrome occurs when the superior cerebellar artery is occluded. With this syndrome, one can expect vertigo, nystagmus, gait disturbance, ipsilateral limb ataxia and facial pain or numbness, contralateral body hemianesthesia, and Horner's syndrome. Distinguishing this syndrome is the finding of contralateral impairment of vibration and temperature due to medial lemniscus involvement.

A high index of suspicion must be kept with any patient presenting with spontaneous vertigo to avoid missing the diagnosis of ischemic stroke. It is essential to consider stroke in any acutely vertiginous patient with concomitant neurological signs and symptoms. Once VIS is suspected, an expeditious work-up is necessary. This should include a thorough physical examination, imaging, and neurology consultation for both evaluation and treatment.

VERTEBROBASILAR INSUFFICIENCY

Vertebrobasilar insufficiency is synonymous with a transient ischemic attack (TIA) of the vertebrobasilar system. By definition, patients experience symptoms similar to those detailed above, but the symptoms resolve within 24 hours. If left untreated, the disease process will eventually progress to stroke with permanent or long-lasting sequelae. Risk factors and causes are identical to those for VIS. Forty-eight percent of patients who suffer a VIS report a TIA in the preceding days or weeks.¹⁷ In fact, 29% of patients suffer from at least one episode of vertigo, a symptom of vertebrobasilar insufficiency, prior to their VIS.¹⁸ Patients suffering a vertebrobasilar TIA are likely to progress to stroke more quickly than those experiencing TIAs in the anterior territory.

Vertebrobasilar insufficiency is a common cause of vertigo in the elderly. Symptoms may last from minutes to hours, but typically average 8 minutes in duration. In as many as one third of patients, vertigo is the only manifestation of their disease. Although this disease should always be in the differential, several months of recurrent vertigo unaccompanied by other neurological signs suggests another disorder. The

likelihood of immediate stroke is less in patients presenting with only episodic vertigo. Patients who also present with paresis, blindness, or altered consciousness, however, should be evaluated urgently for fear of impending stroke. Evaluation is similar to that of an ischemic stroke. Treatment includes antiplatelets, anticoagulation, possible thrombolysis and percutaneous transluminal angioplasty, and neurological consultation.

CONCLUSION

Dizziness is a common complaint and can represent numerous disease processes. The goal of this paper was to present the more common causes of vertigo and disequilibrium relating to pathology of the central and peripheral vestibular system. This is far from an exhaustive list but hopefully serves as a good review and starting point for future readings.

REFERENCES

1. Sloan PD. Dizziness in primary care. Results from the national ambulatory medical care survey. *J Family Practice*. 1989;29:33–38.
2. Froehling DA, Silverstein MD, Mohr DN, et al. Benign positional vertigo: incidence and prognosis in a population-based study in Olmsted County, Minnesota. *Mayo Clin Proc*. 1991;66:596–601.
3. Epley JM. New dimensions of benign paroxysmal positional vertigo. *Otolaryngol Head Neck Surg*. 1980;88:599–605.
4. Nunez RA, Cass SP, Furman JM. Short- and long-term outcomes of canalith repositioning for benign paroxysmal positional vertigo. *Otolaryngol Head Neck Surg*. 2000;122:647–652.
5. Schessel DA, Minor LB, Nedzelski J. Meniere's disease and other peripheral vestibular disorders. In: Gaertner RS, Murphy MB, eds. *Cummings Otolaryngology Head and Neck Surgery*. 4th ed. Philadelphia: Mosby, 2004:3231–3232.
6. Strupp M, Zingler VC, Arbusow V, et al. Methylprednisolone, valacyclovir, or the combination for vestibular neuritis. *N Engl J Med*. 2004;351:354–361.
7. Tos M, Thomson J. Epidemiology of acoustic neuromas. *J Laryngol Otol*. 1984;98:685–692.
8. Khrais T, Romano G, Sanna M. Nerve origin of vestibular schwannoma: a prospective study. *J Laryngol Otol*. 2008;122:128–131.
9. Rizer FM, House JW. Perilymph fistulas: the House Ear Clinic experience. *Otolaryngol Head Neck Surg*. 1991;104:239–243.
10. Black FO, Pesznecker S, Norton T, et al. Surgical management of perilymphatic fistulas: a Portland experience. *Am J Otol*. 1992;13:254–262.
11. Seltzer S, McCabe BF. Perilymph fistula: the Iowa experience. *Laryngoscope*. 1986;96:37–49.
12. Minor LB, Solomon D, Zinreich JS, et al. Sound- and/or pressure-induced vertigo due to bone dehiscence of the superior semicircular canal. *Arch Otolaryngol Head Neck Surg*. 1998;124:249–258.
13. Carey JP, Minor LB, Nager GT. Dehiscence or thinning of bone overlying the superior semicircular canal in a temporal bone survey. *Arch Otolaryngol Head Neck Surg*. 2000;126:137–147.
14. Headache Classification Subcommittee of the International Headache Society, *The International Classification of Headache Disorders*. 2nd ed. Oxford, England: Blackwell Publishing, 2003:24–36.
15. Neuhauser HK, Leopold M, von Brevern M, et al. The interrelations of migraine, vertigo, and migrainous vertigo. *Neurology*. 2001;56:436–441.
16. Neuhauser HK, Lempert T. Diagnostic criteria for migrainous vertigo. *Acta Otolaryngol*. 2005;125:276–279.
17. Kim HY, Chung CS, Moon SY, et al. Complete nonvisualization of basilar artery on MR angiography in patients with vertebrobasilar ischemic stroke: favorable outcome factors. *Cerebrovasc Dis*. 2004;18:269–276.
18. Grad A, Baloh RW. Vertigo of vascular origin. Clinical and electronystagmographic features in 84 cases. *Arch Neurol*. 1989;46:281–284.